


2018 FOLLOW-UPS



WLNC 2018

ISTANBUL CASES



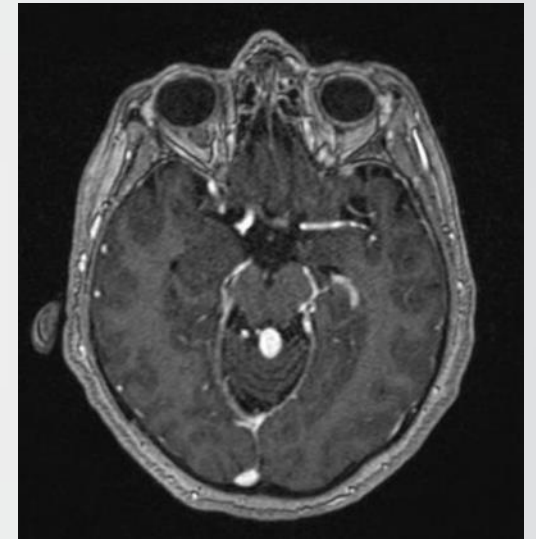
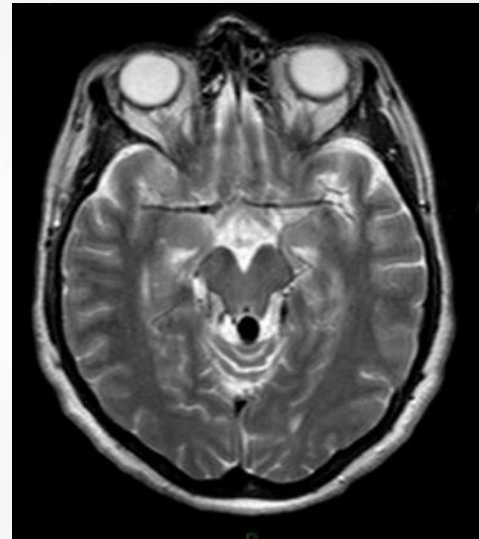
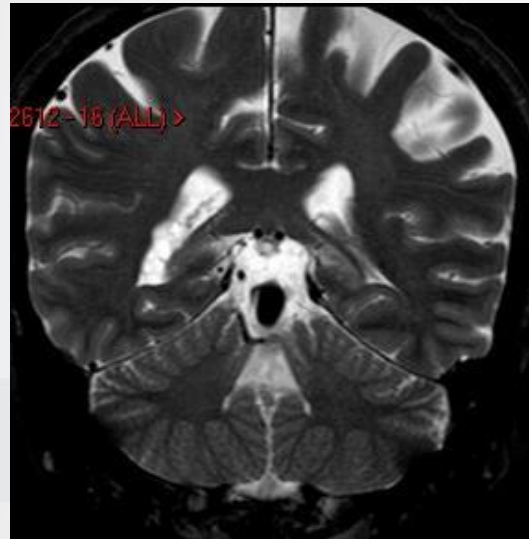
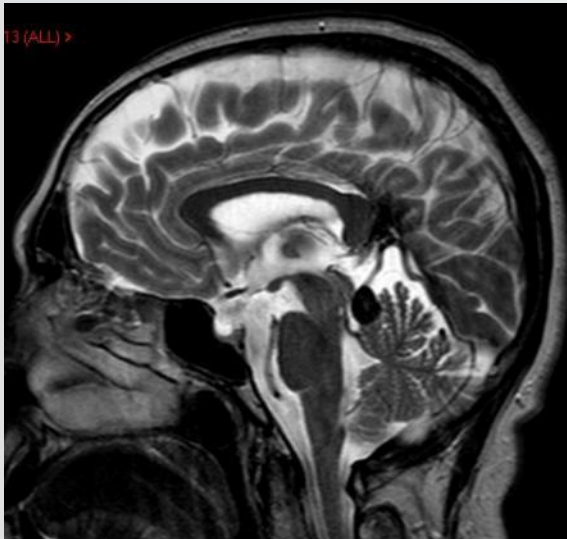
PATIENT 1 NK

- 62 Y F
- Presented with dizziness 2 years ago
- MR-DSA:

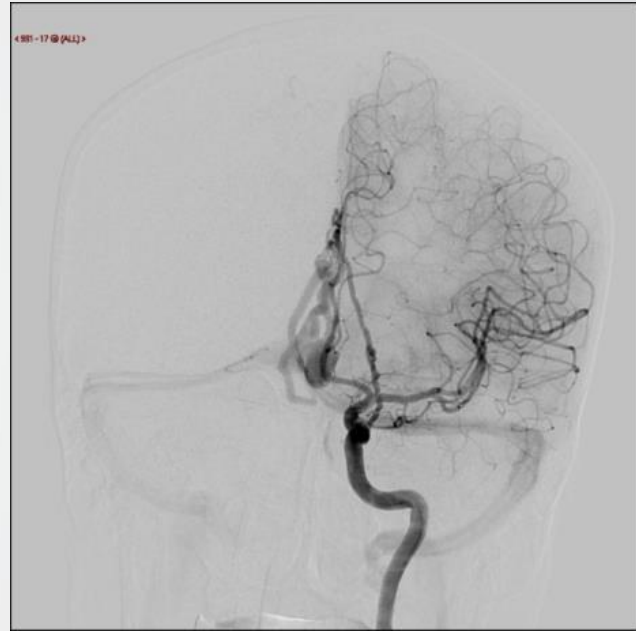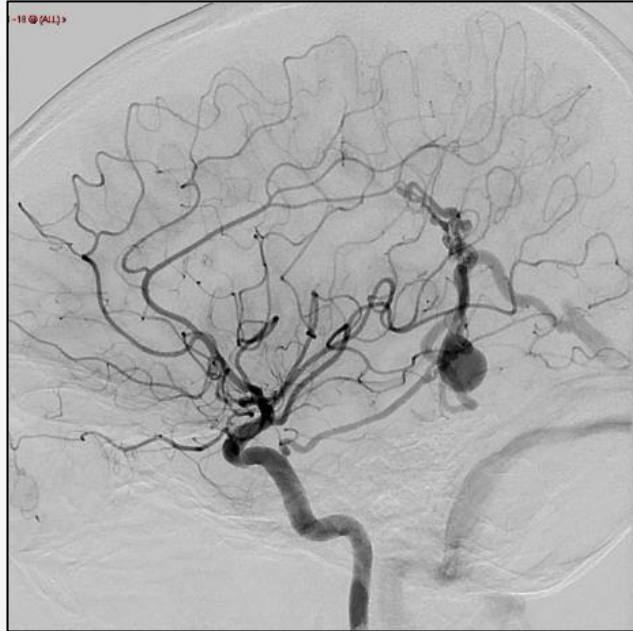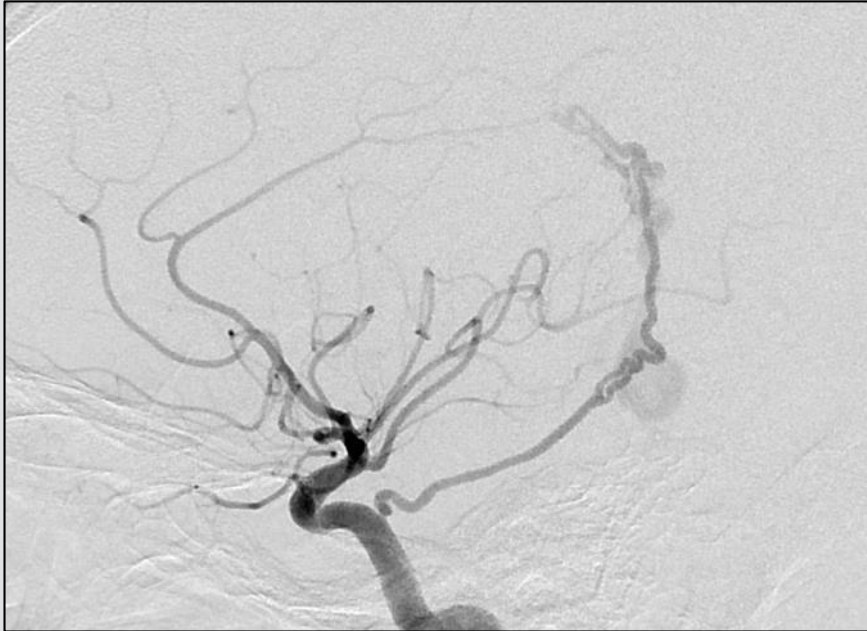Falcotentorial Dural AVF



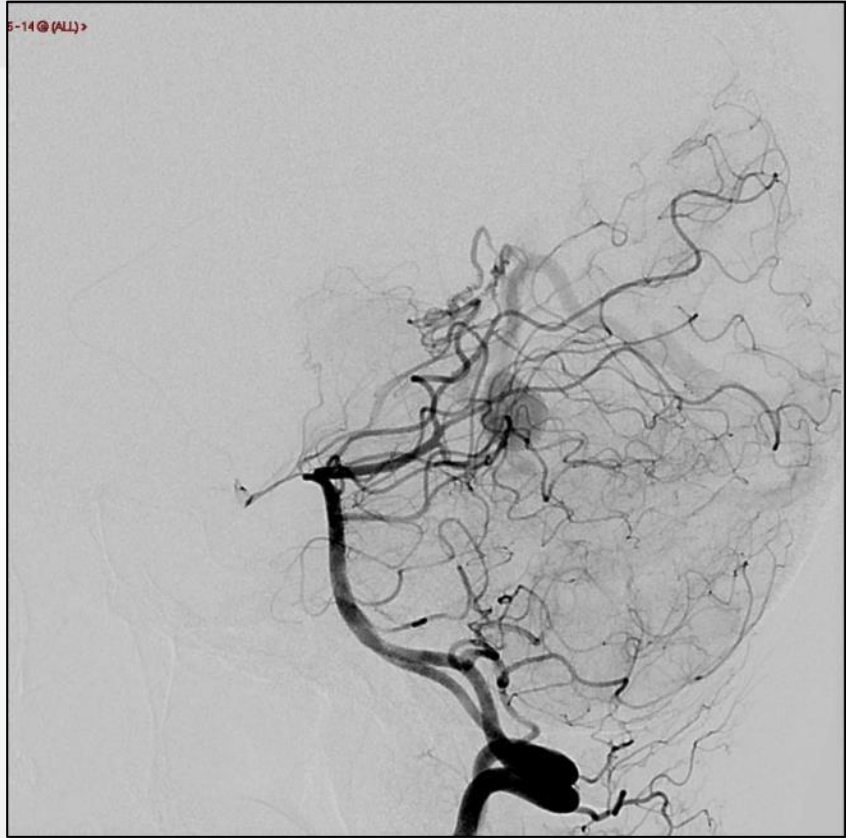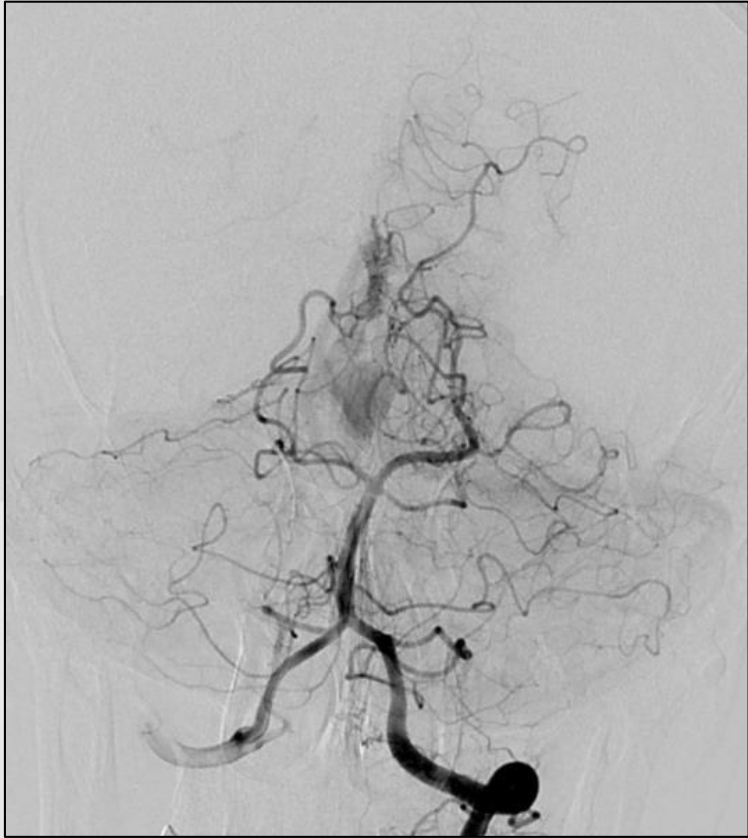
MRI 2017



DSA 11.11.2017



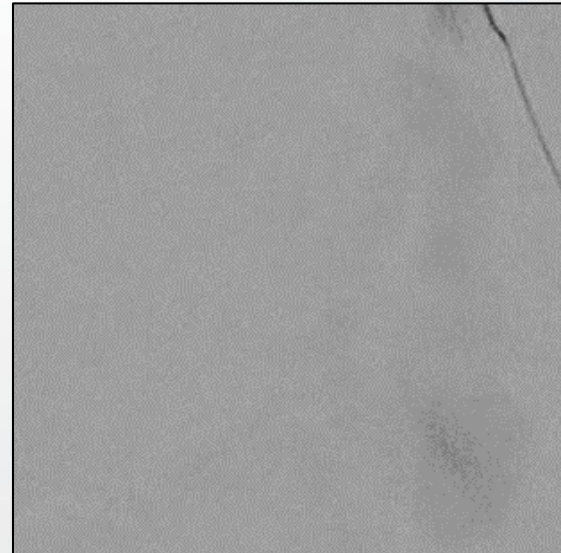
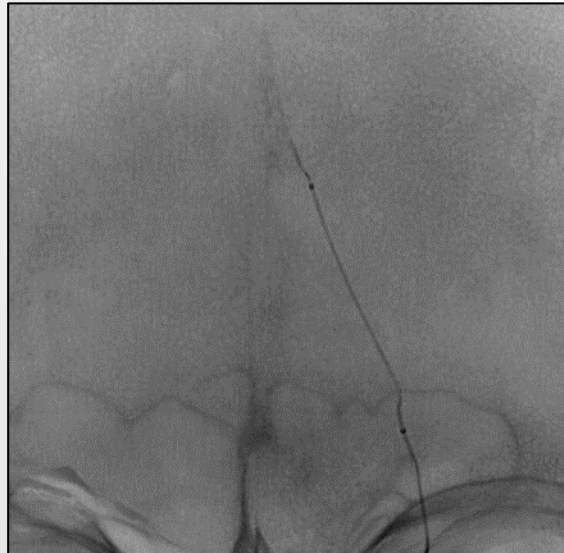
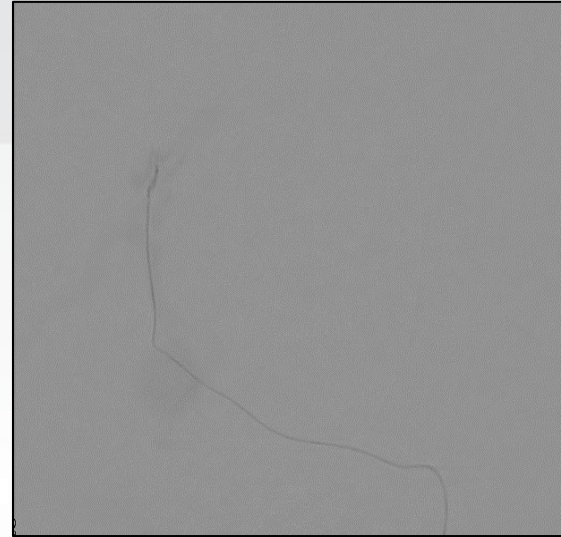
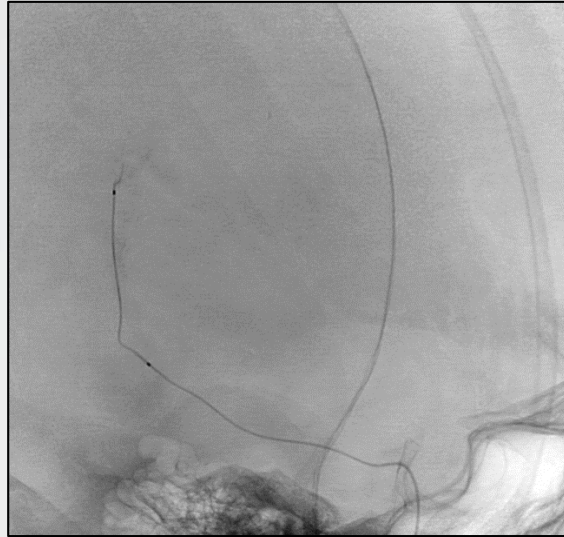DSA 11.11.2017



TREATMENT PLAN

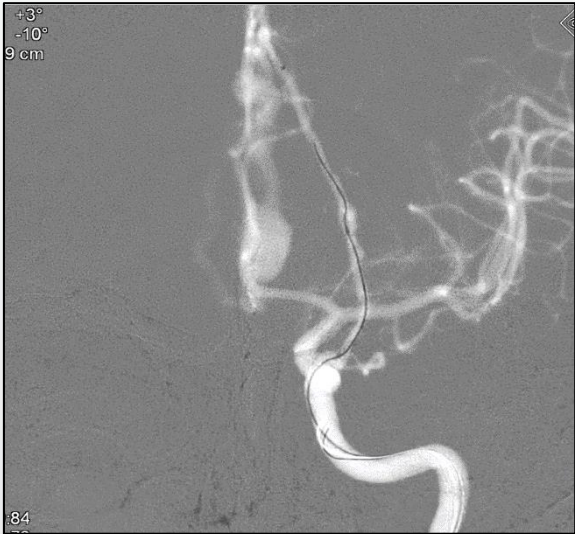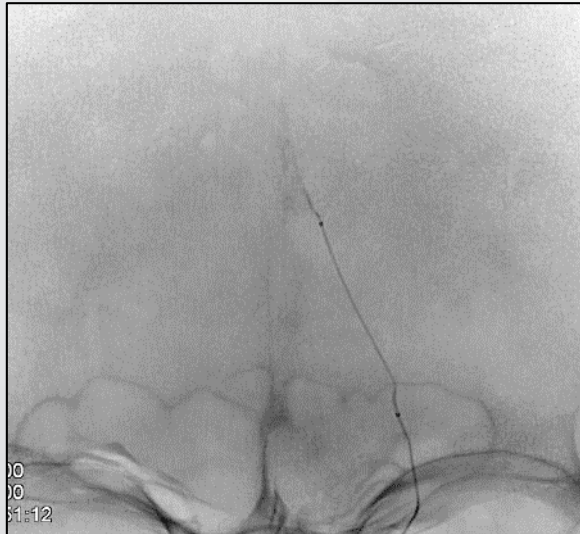
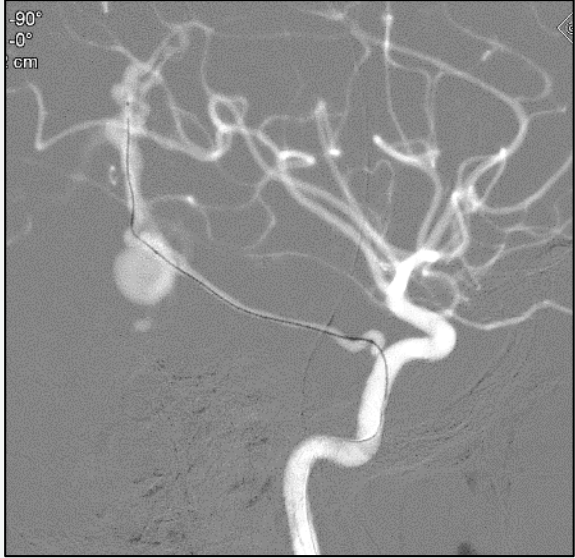
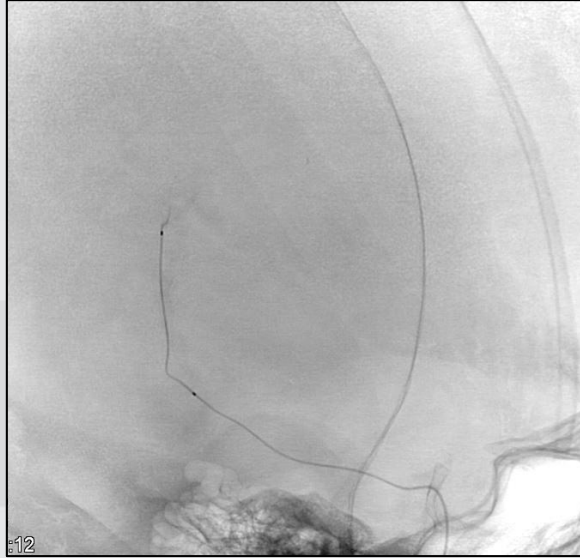- Transarterial access
- Embolisation with liquid embolic agent (Phil)
- Non or Detachable tip microcatheter

L ICA MHT Bernasconi-Cassinari artery

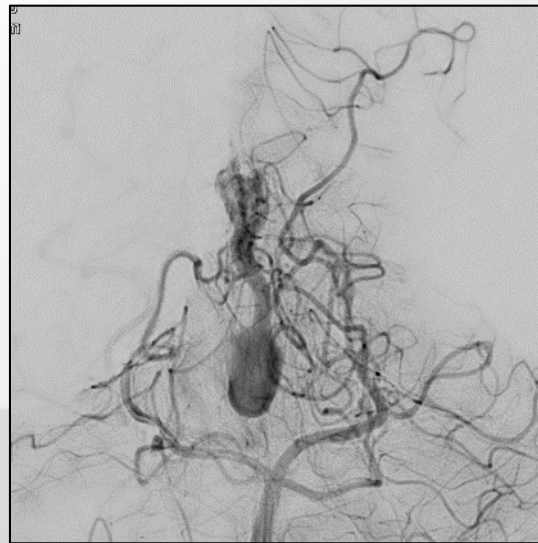
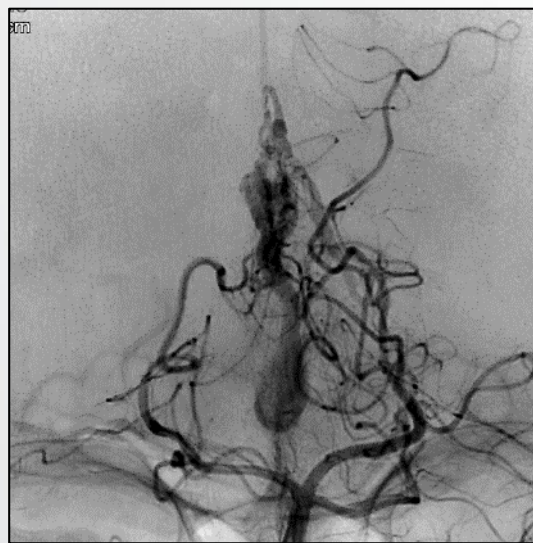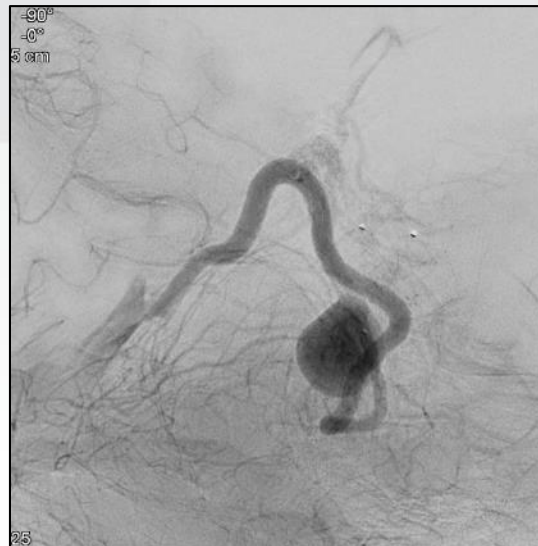

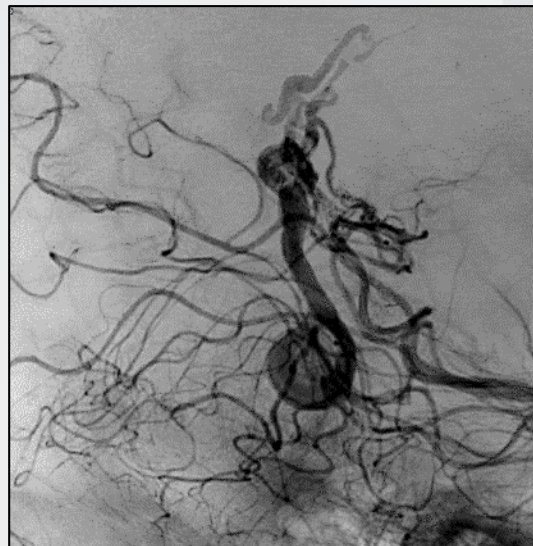
Embolization

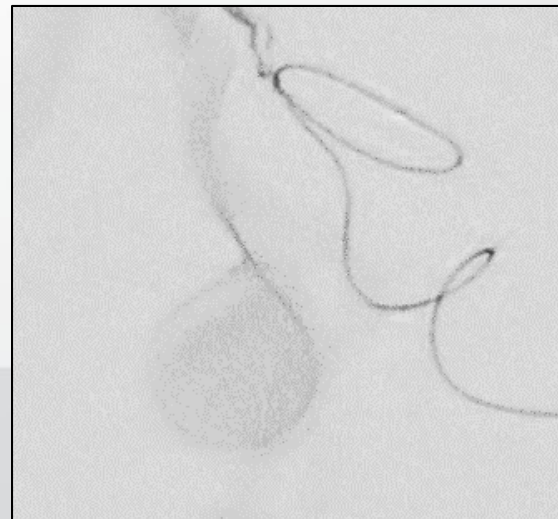
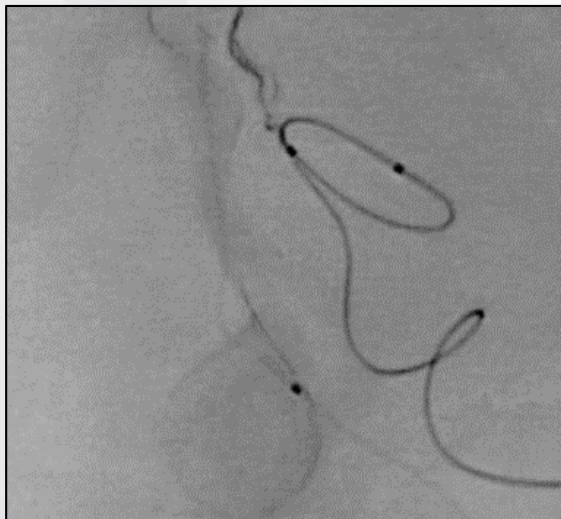
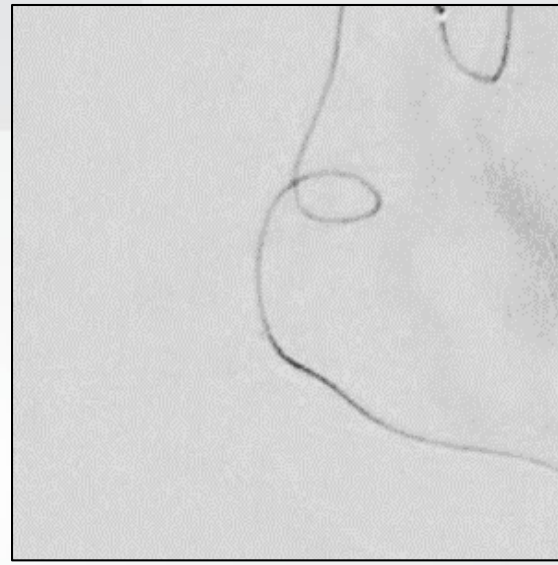
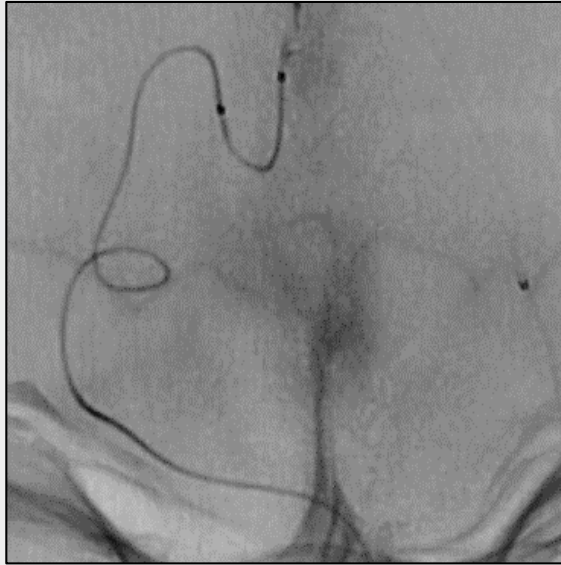
Left ICA MHT Bernasconi-Cassinari artery



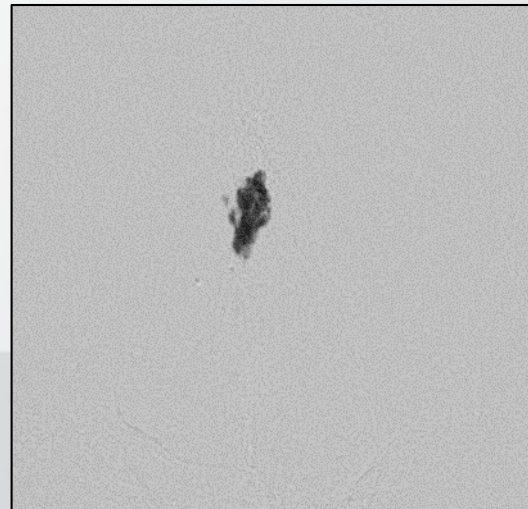
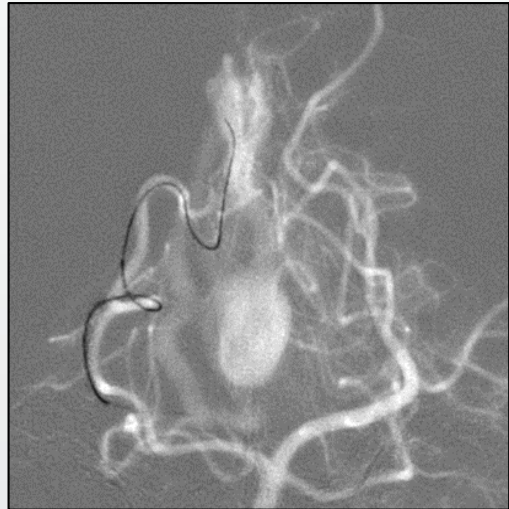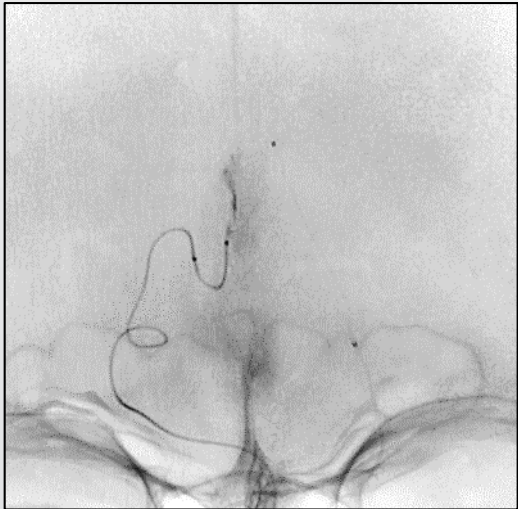
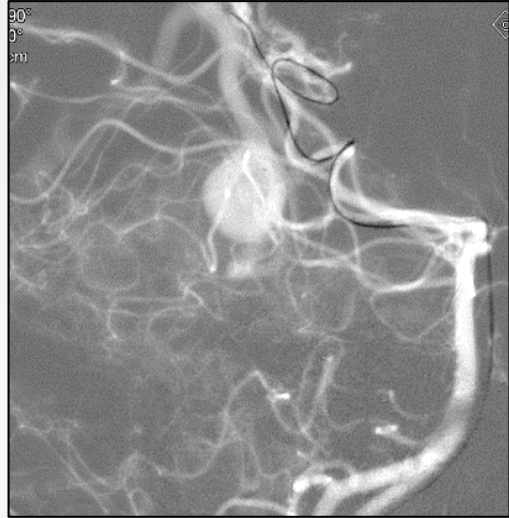
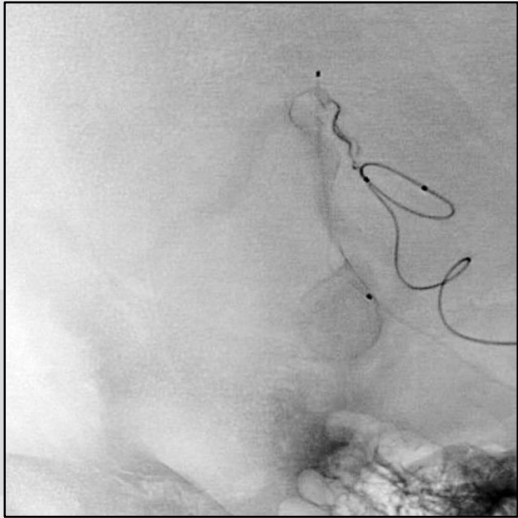
Residual flow R PCA injection



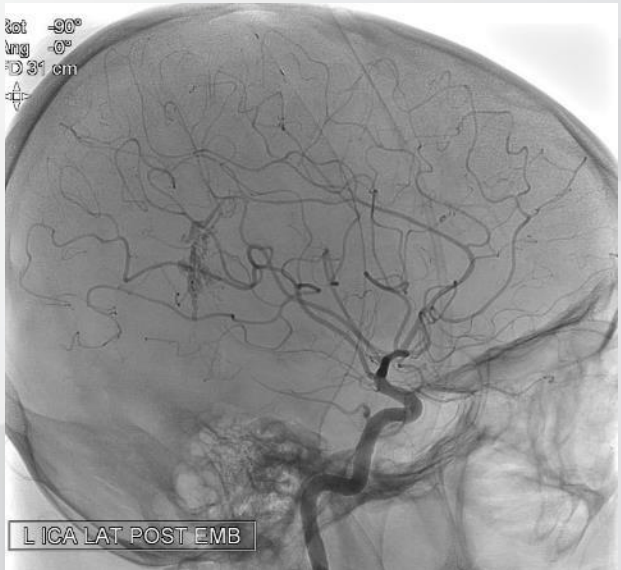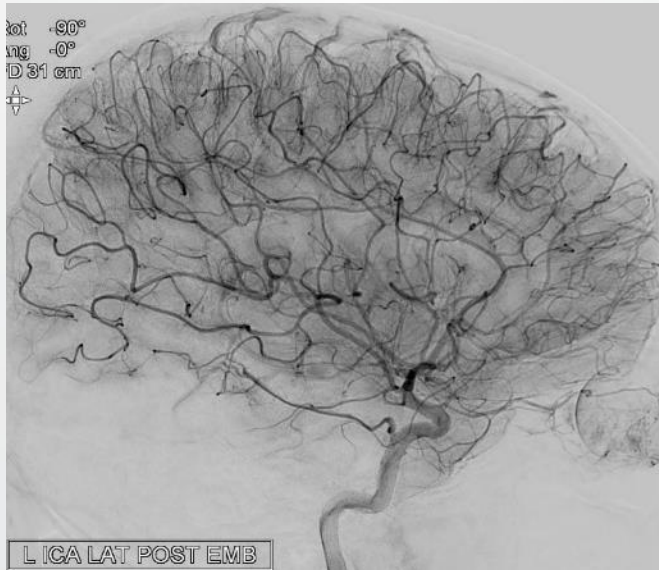
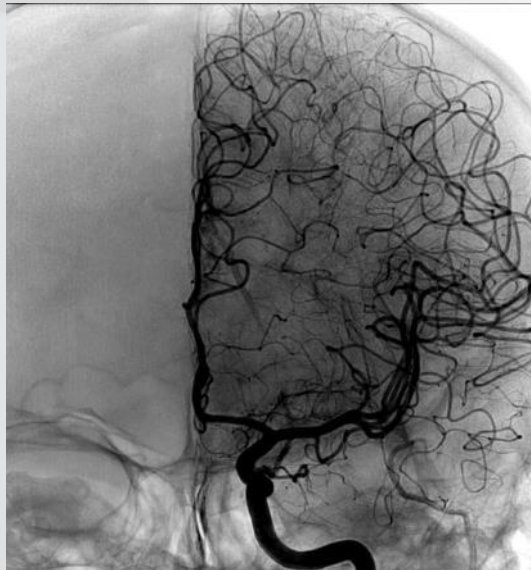
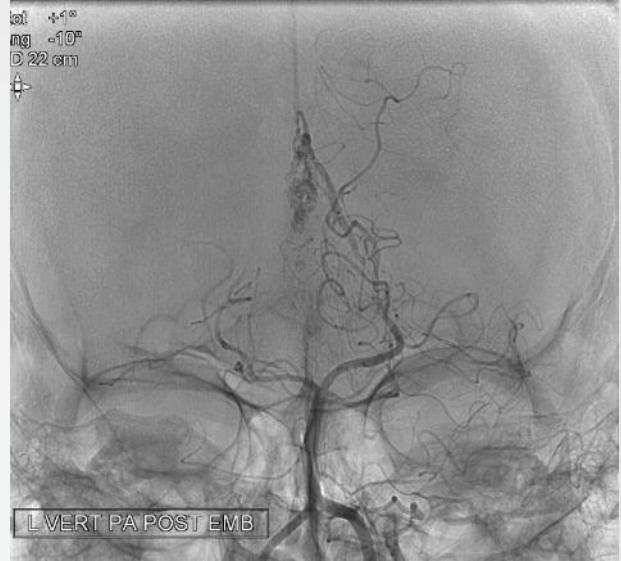
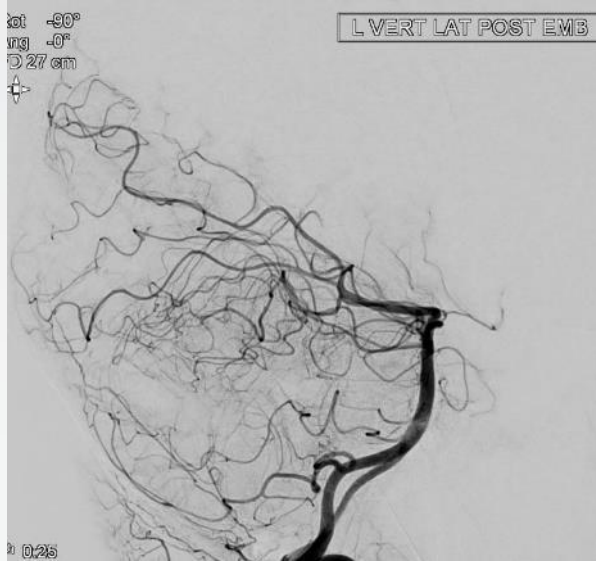
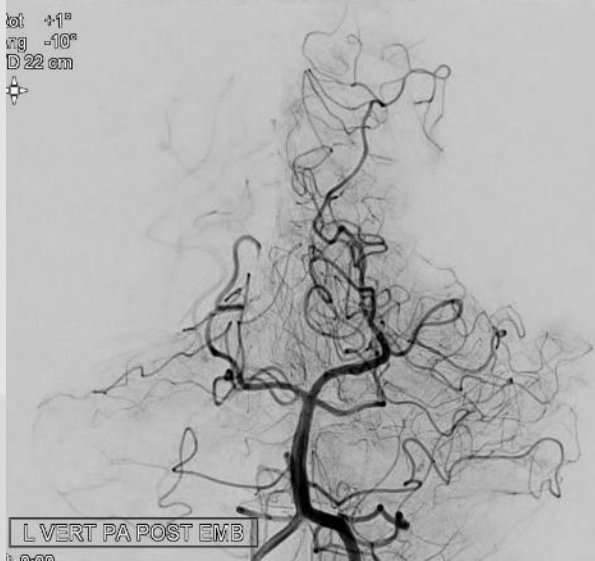
R PCA Davidoff-Schechter artery



Embolization R PCA Davidoff-Schechter artery

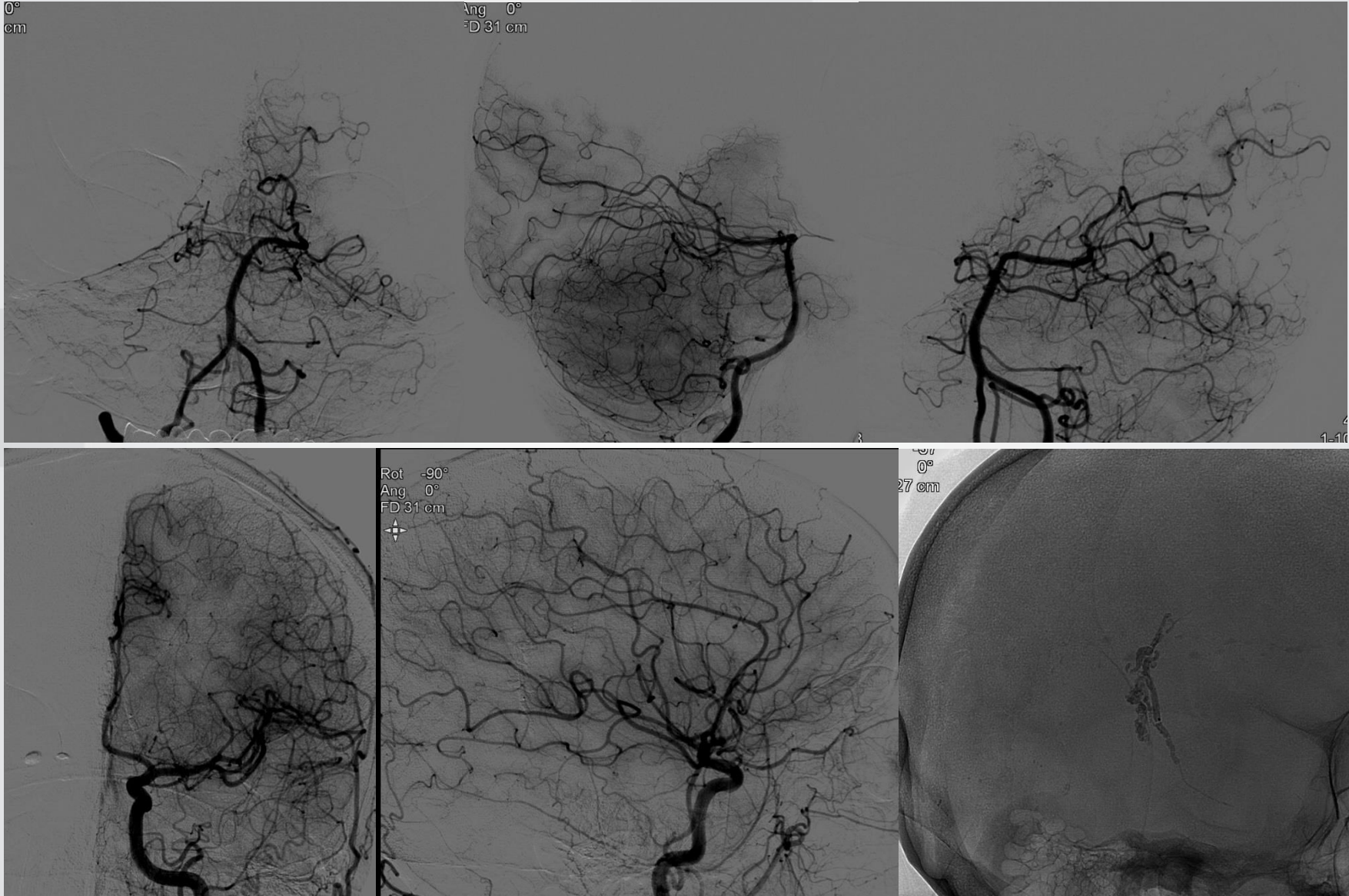


Post Embolization



FOLLOW UP

12-2018

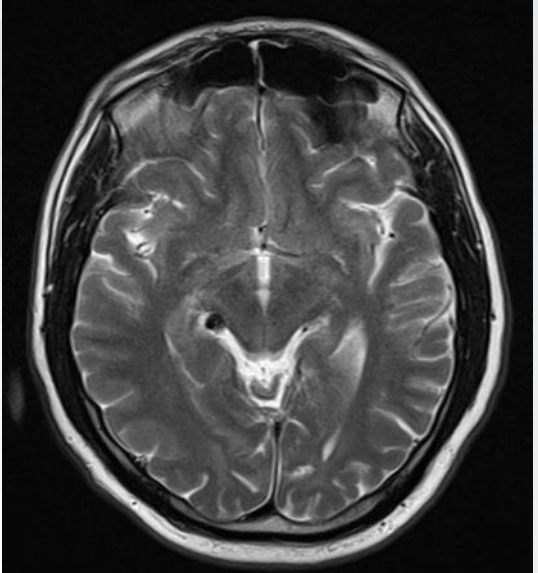
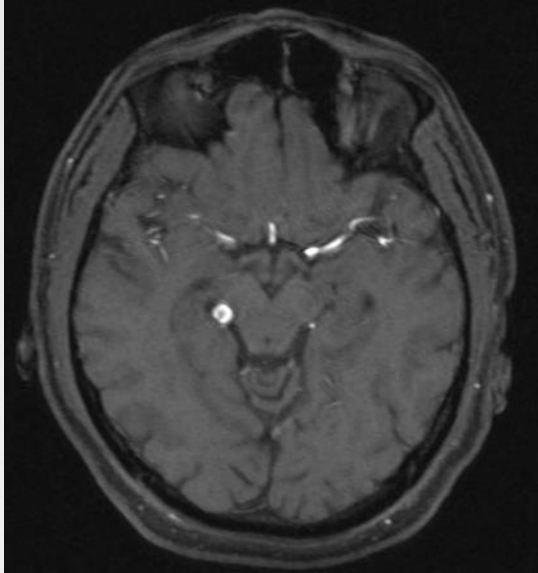


PATIENT 2 AAT

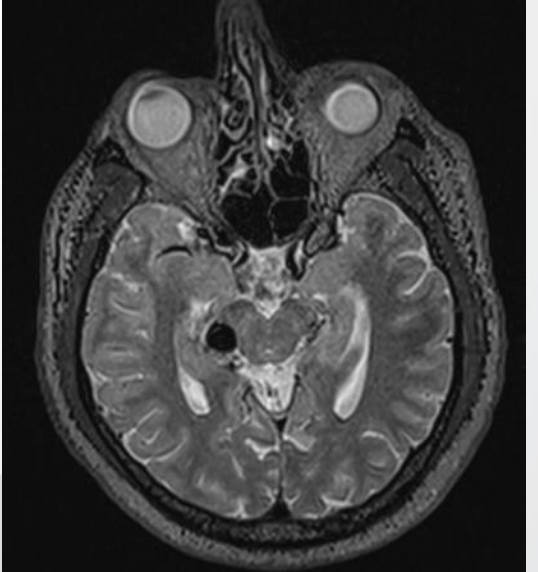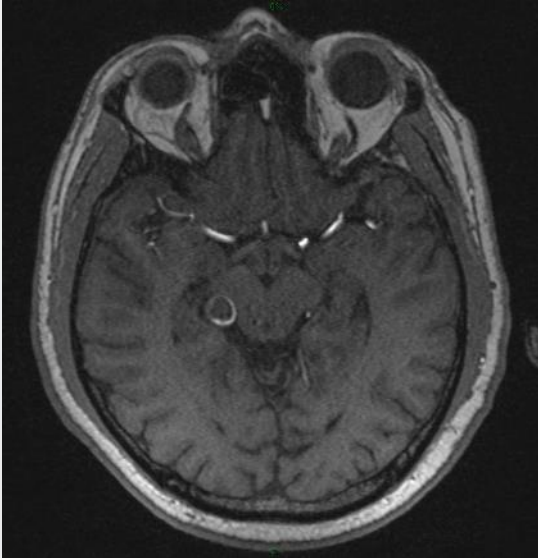
- 55 Y M
- Presented with headaches 5 years ago
- MRA & DSA:
 - **R PCA P2-P3 segment fusiform aneurysm without thrombosis**
 - Enlarged by time!



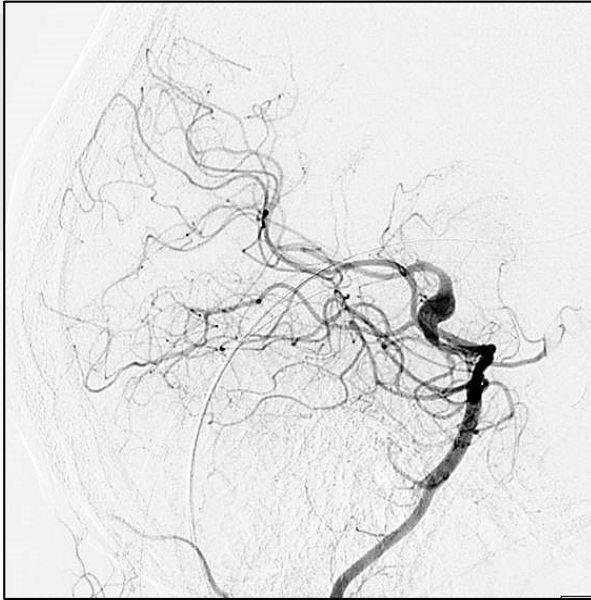
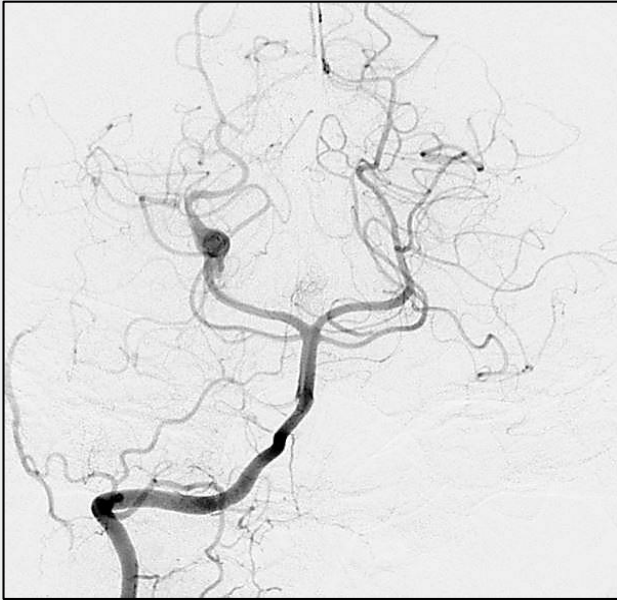
MRI 2013



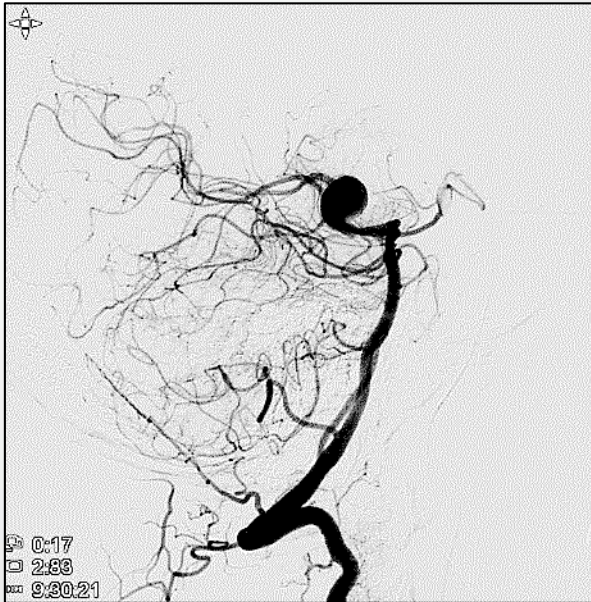
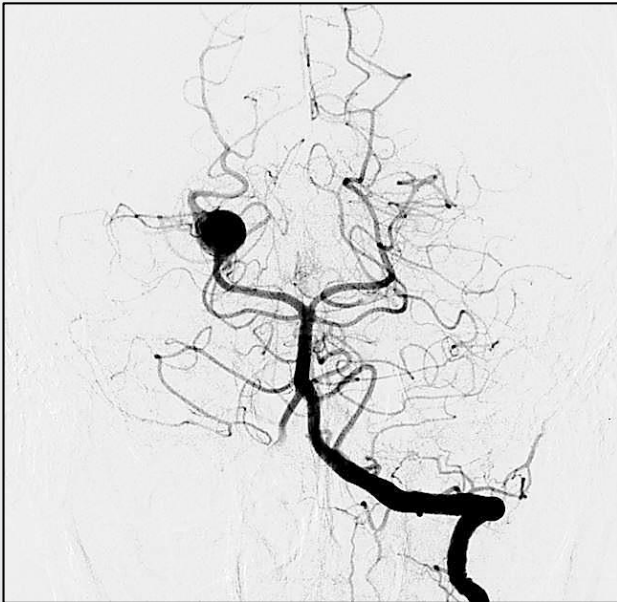
MRI 2018

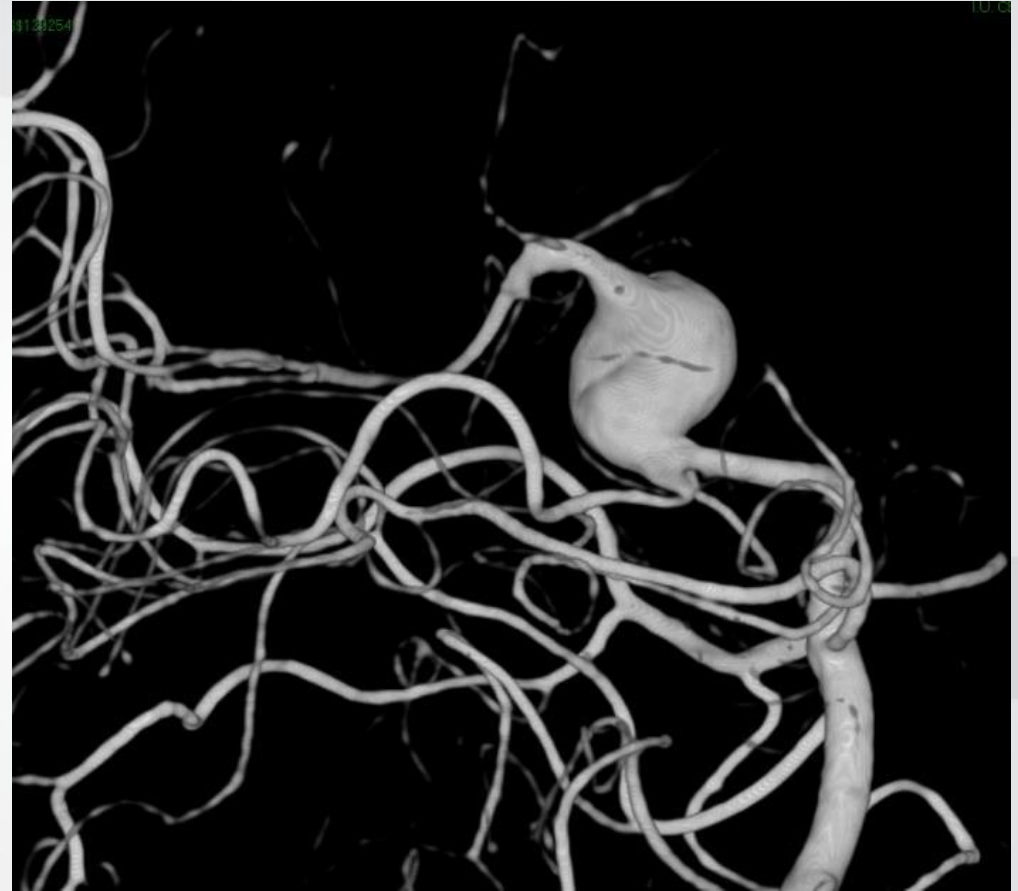
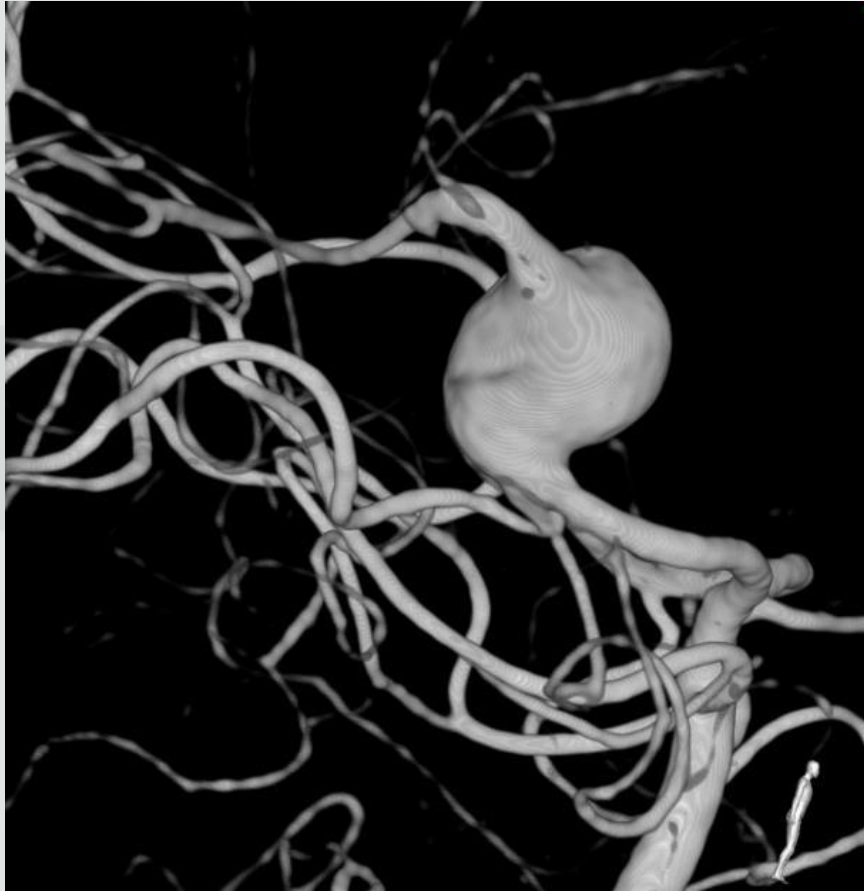


DSA 2011



DSA 2017

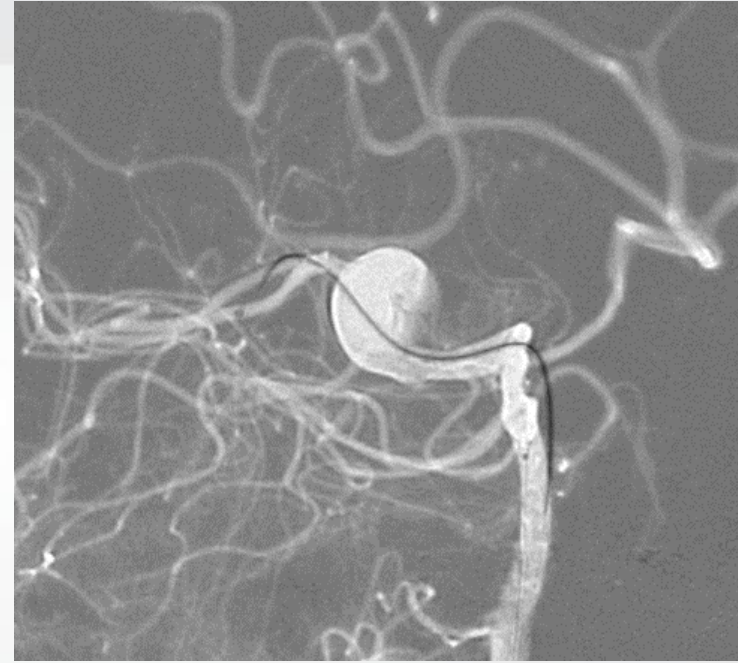
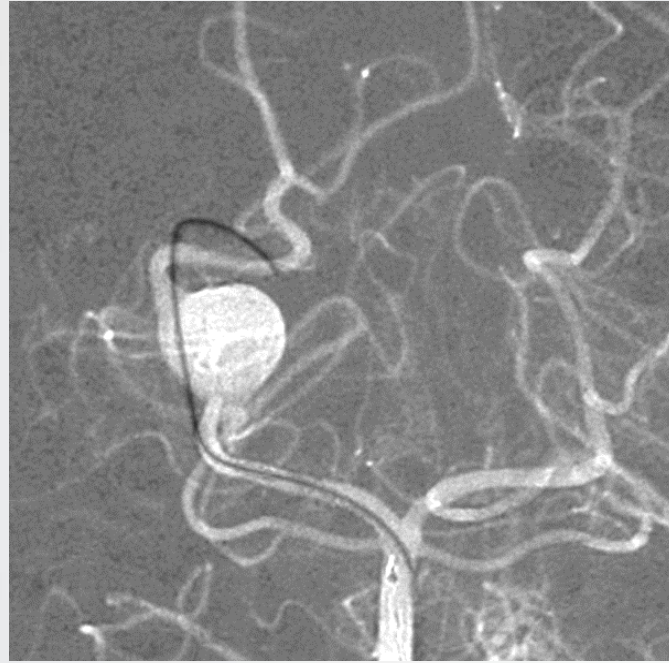


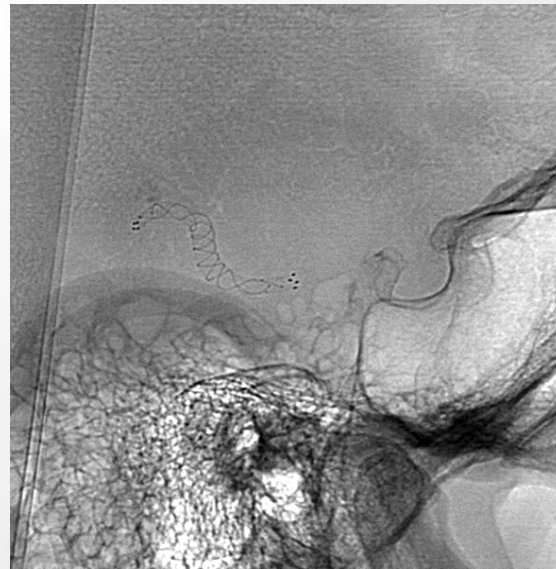
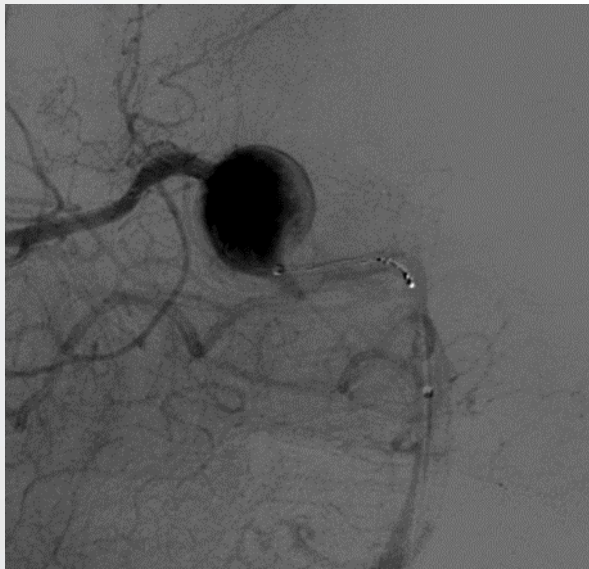
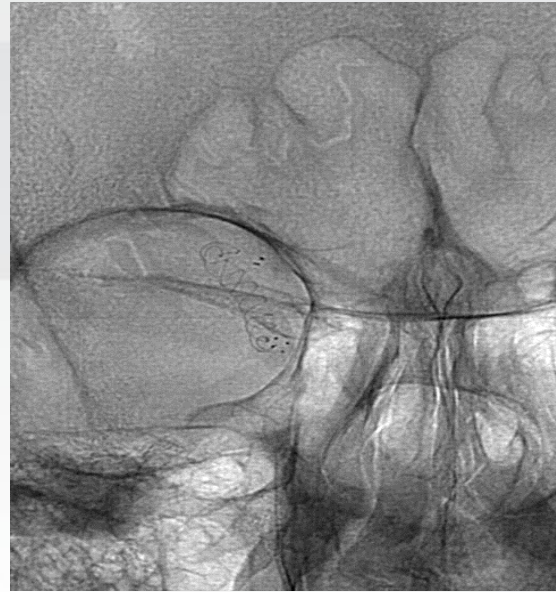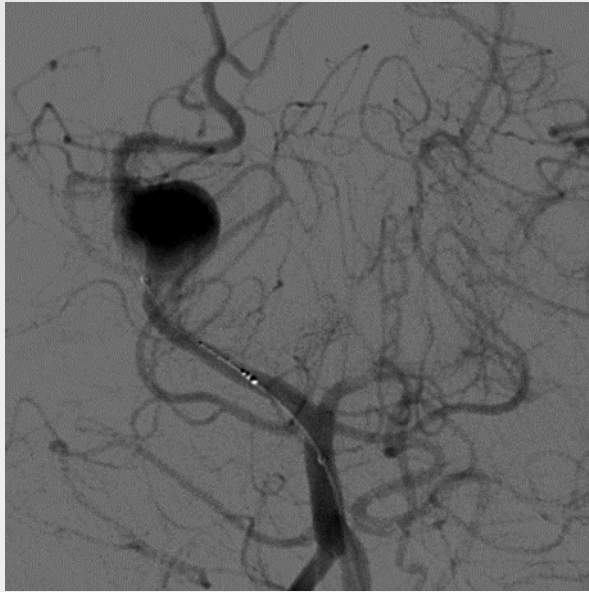
TREATMENT PLAN

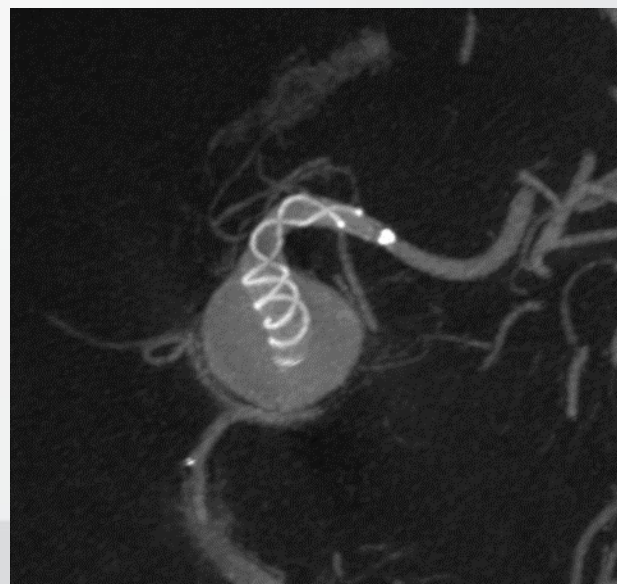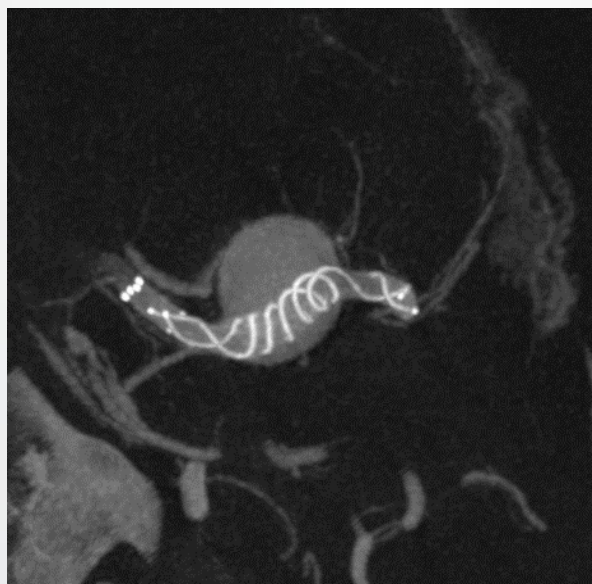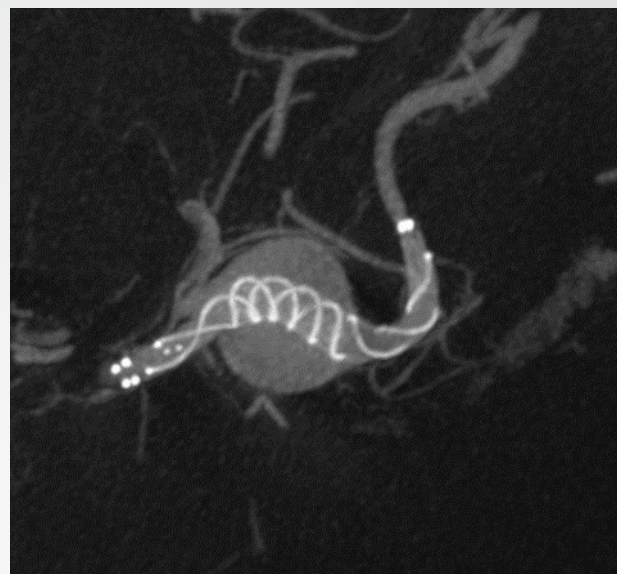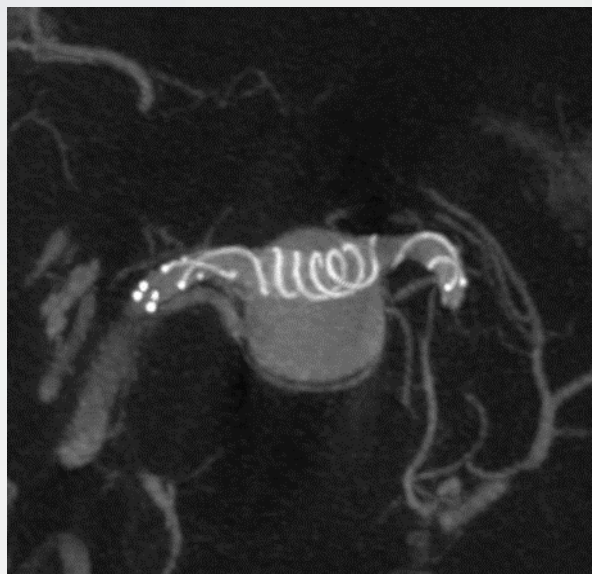
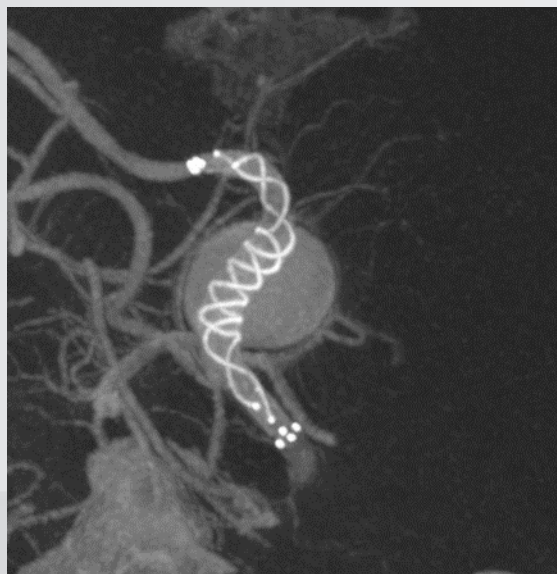- Flow diverter stent

TREATMENT

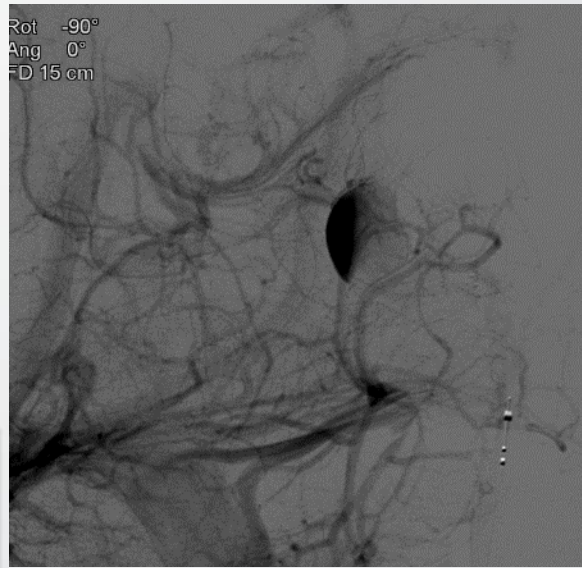
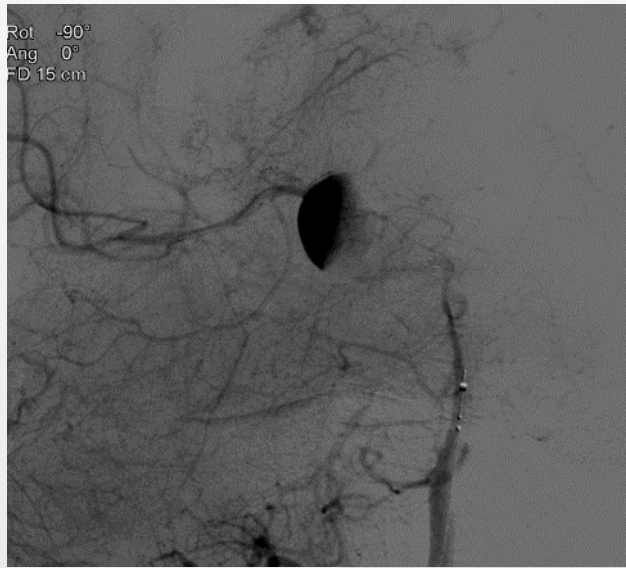
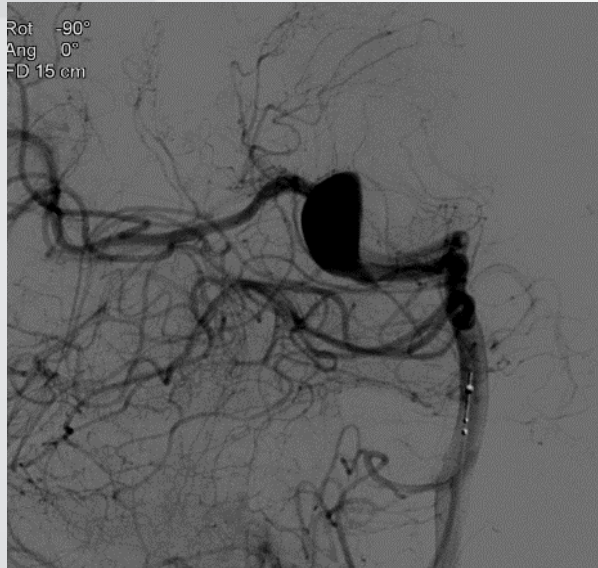
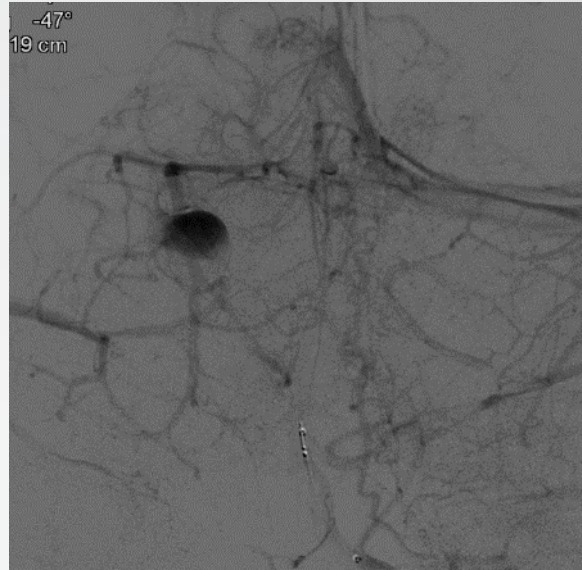
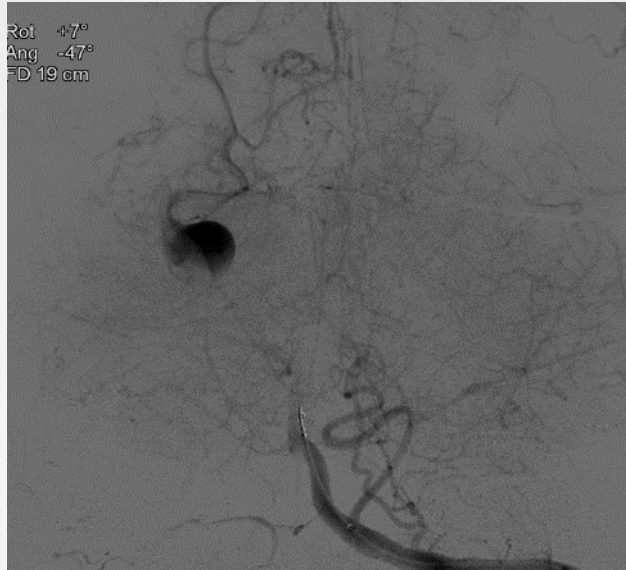
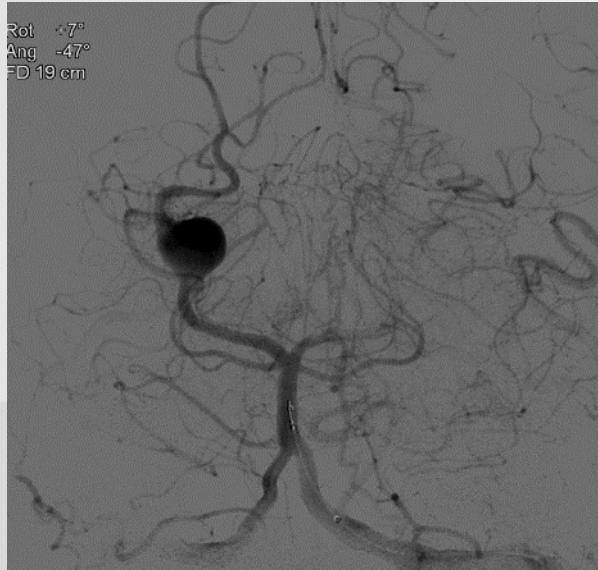


Size of the aneurysm : 13x9 mm
FD stent: FRED Jr. 3/32/27mm



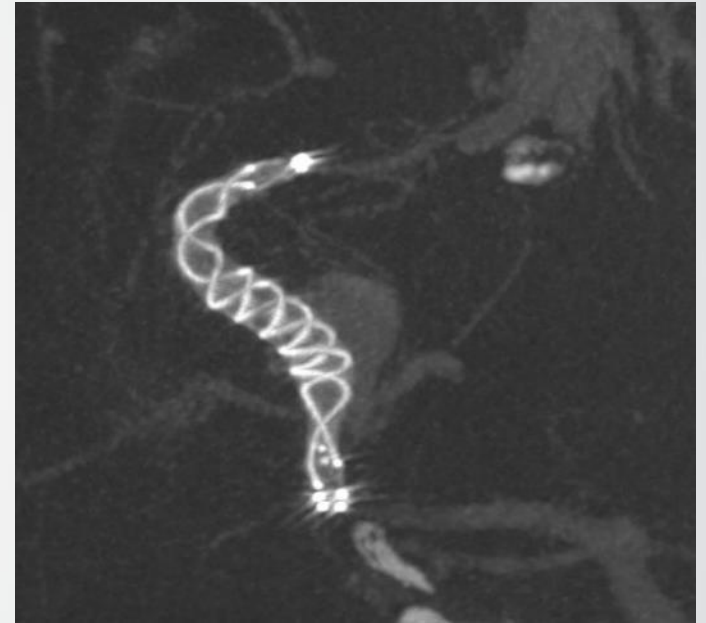
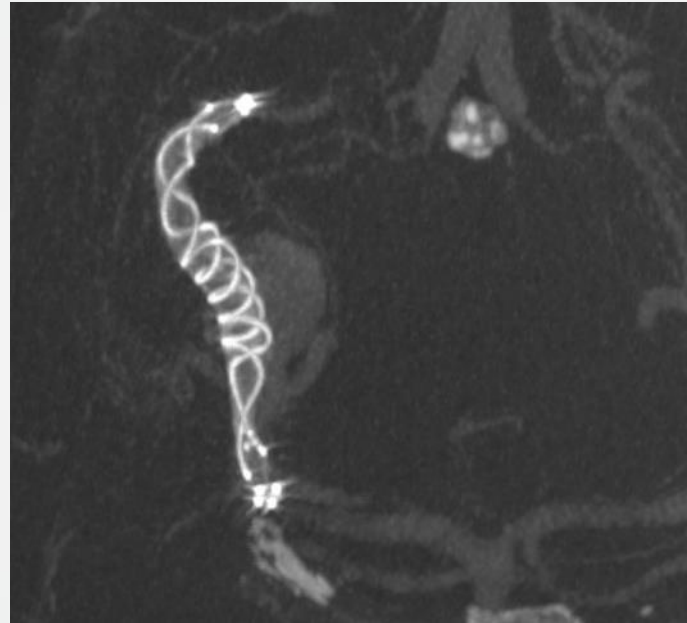
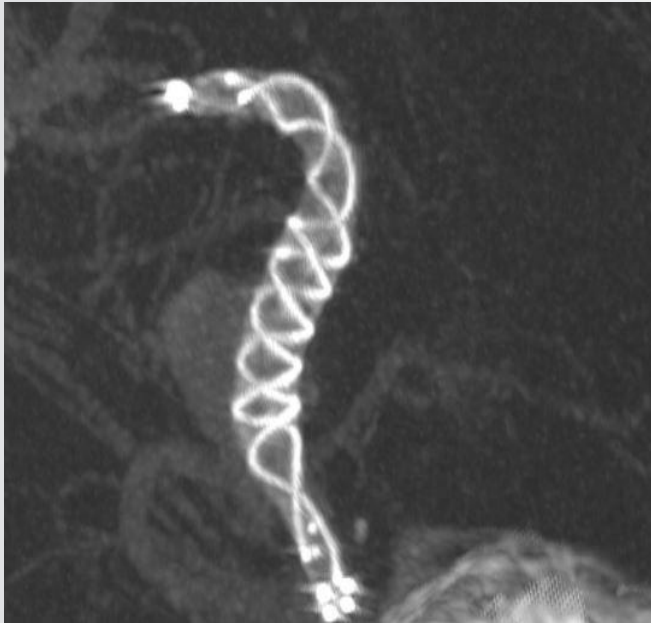


POST TREATMENT



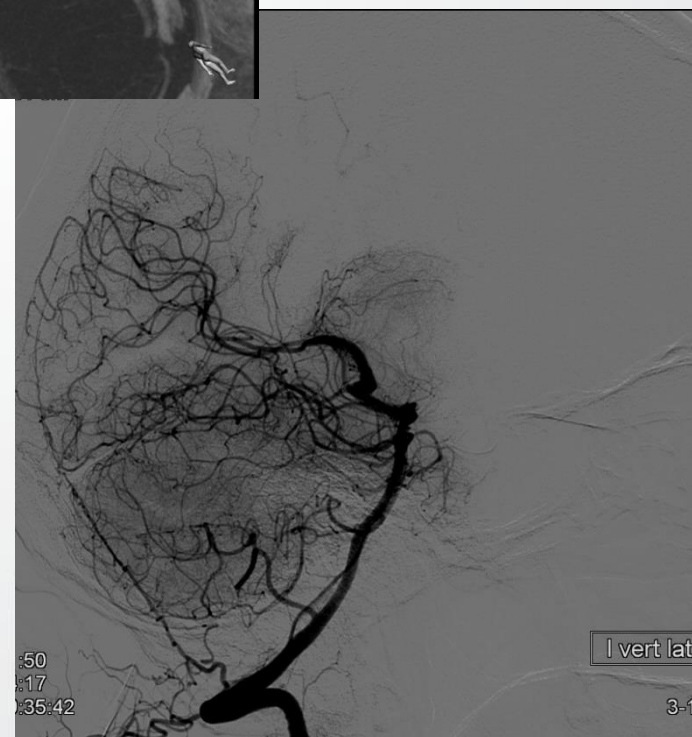
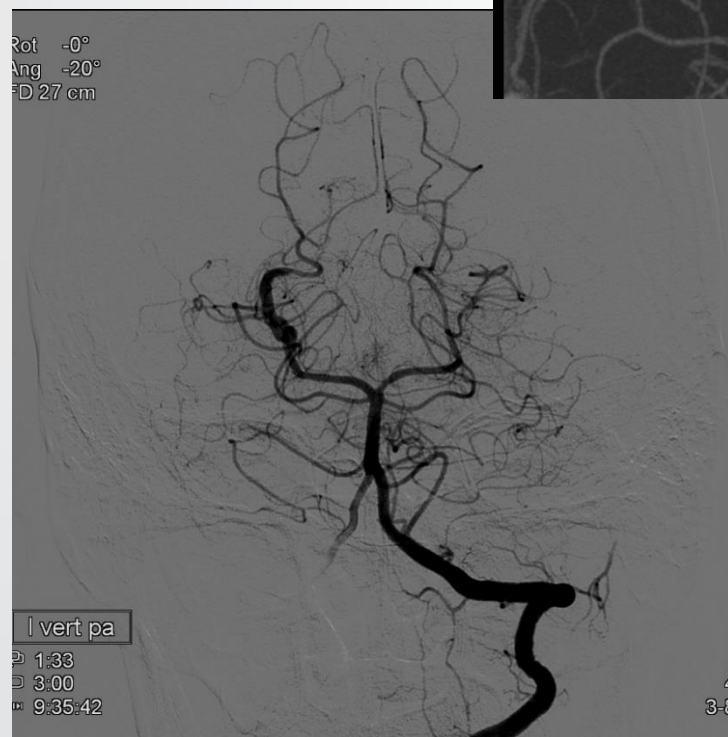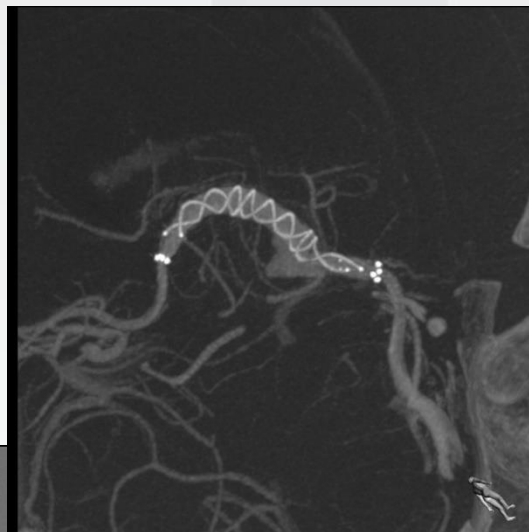
FOLLOW UP

02.05.2018:Vaso CT



FOLLOW UP

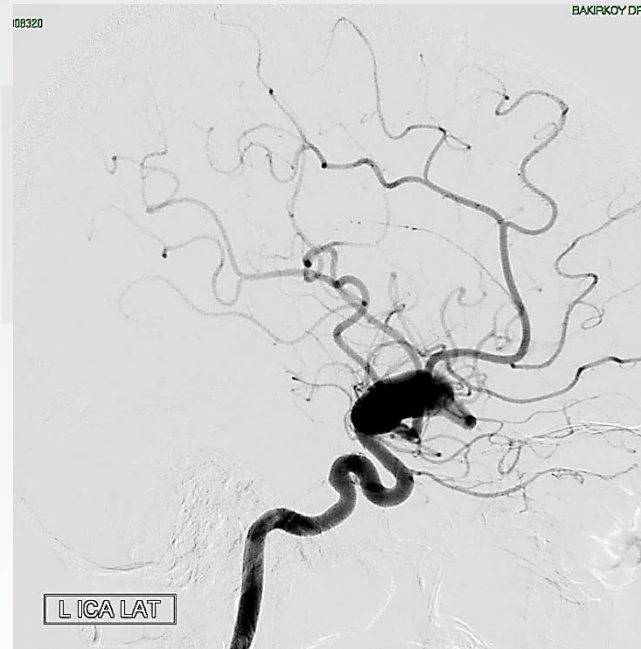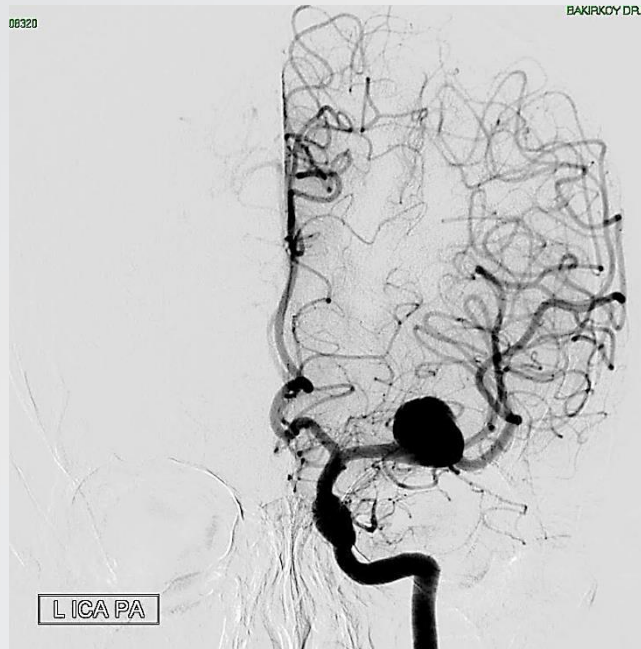25.03.2019



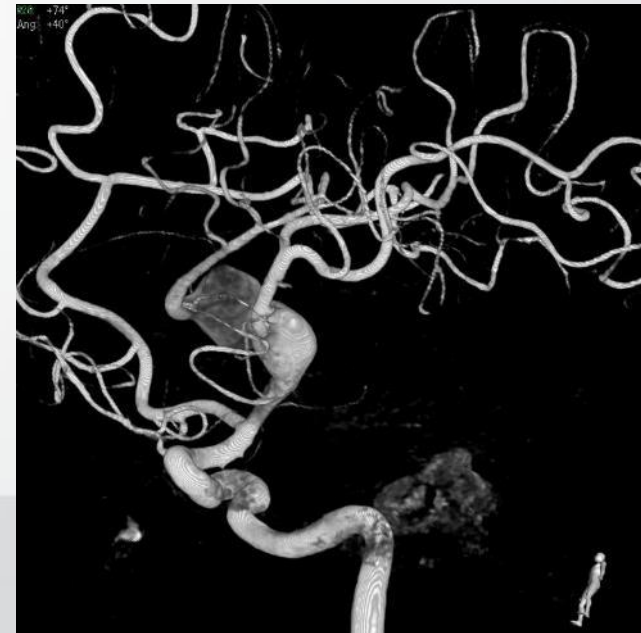
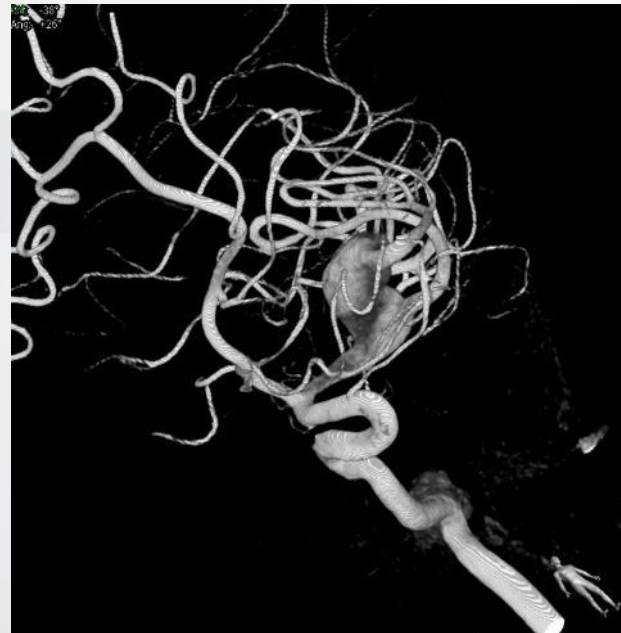PATIENT 2 YK

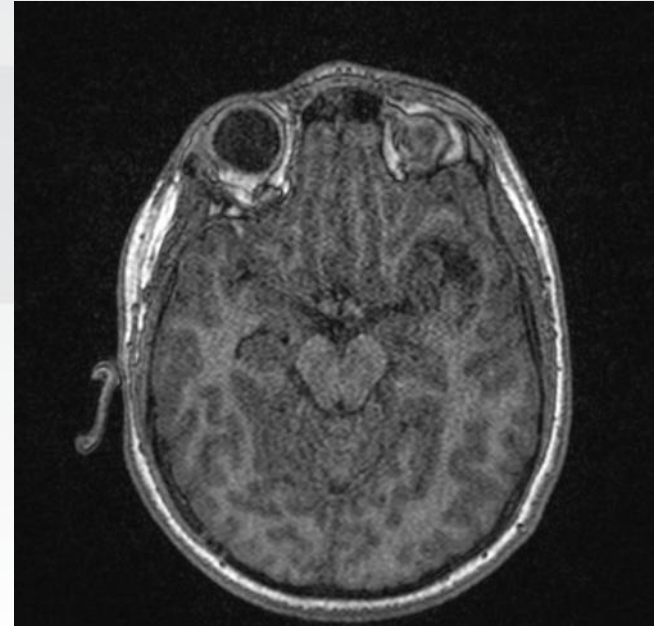
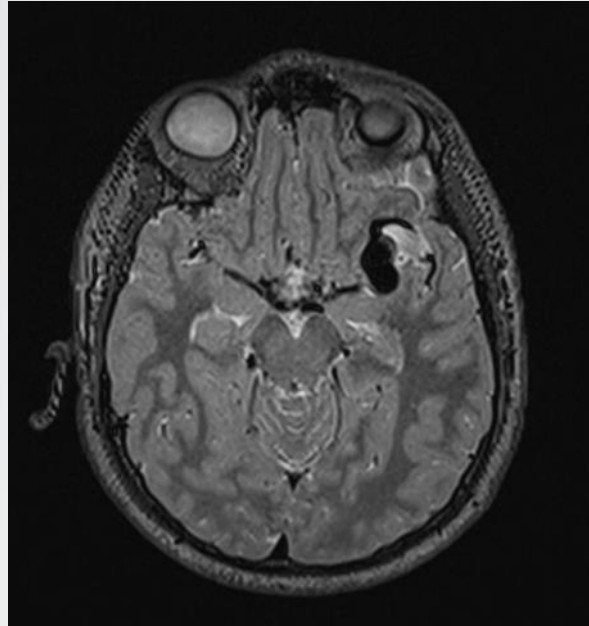
- 16 Y M
- Diagnosed incidentally after car accident 1 year ago
- CTA-MRA-DSA:
 - L MCA fusiform aneurysm,**
 - MCA M1-M2 (mostly on upper truncus)**



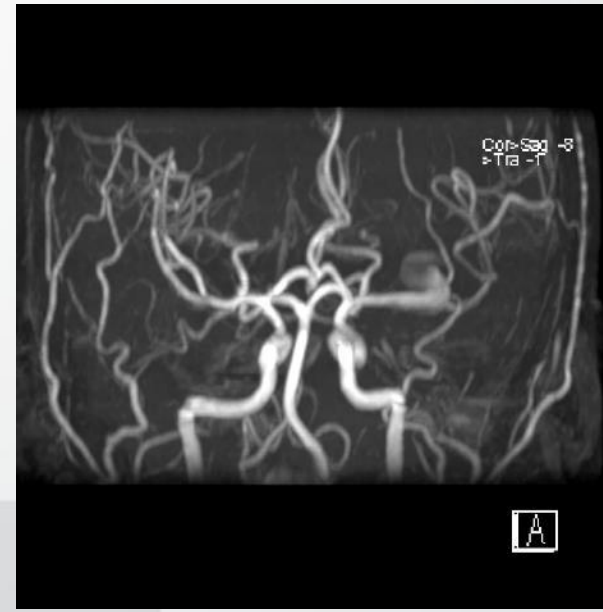
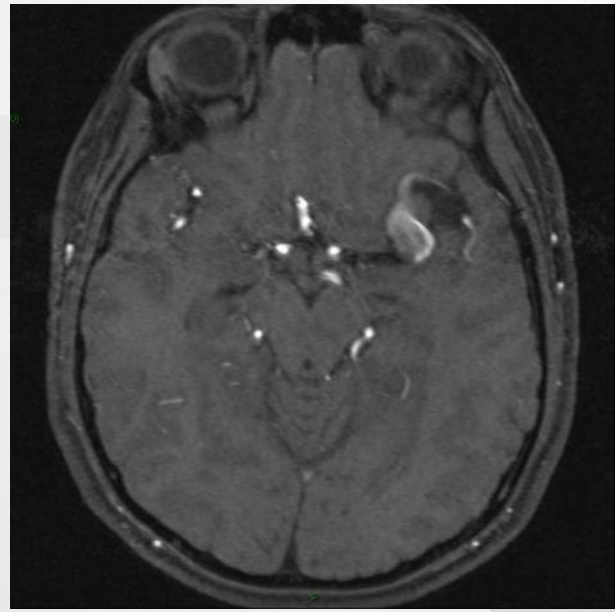


DSA 20.06.2017





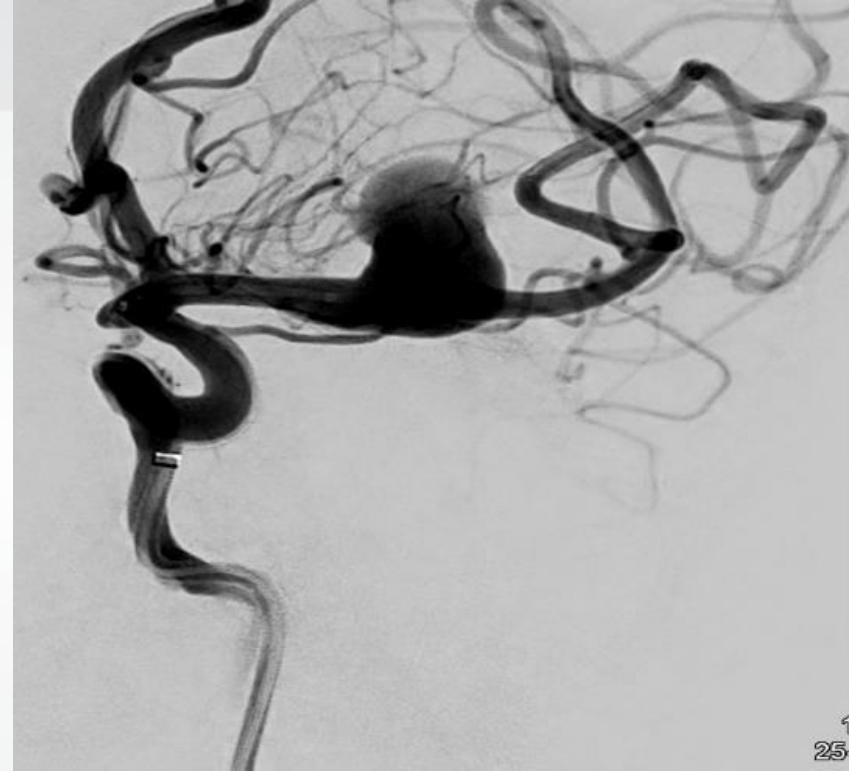
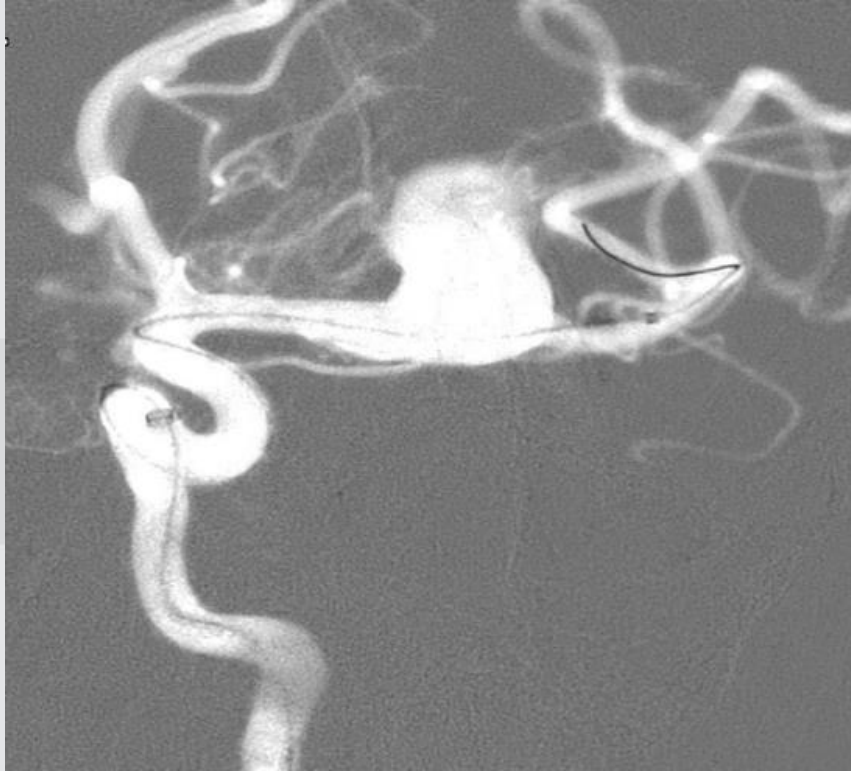MRI 05.04.2018



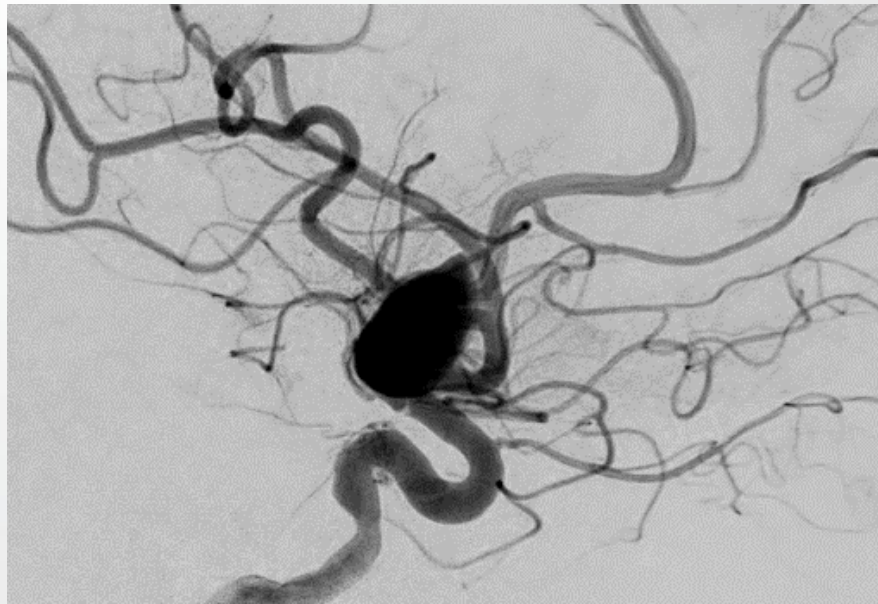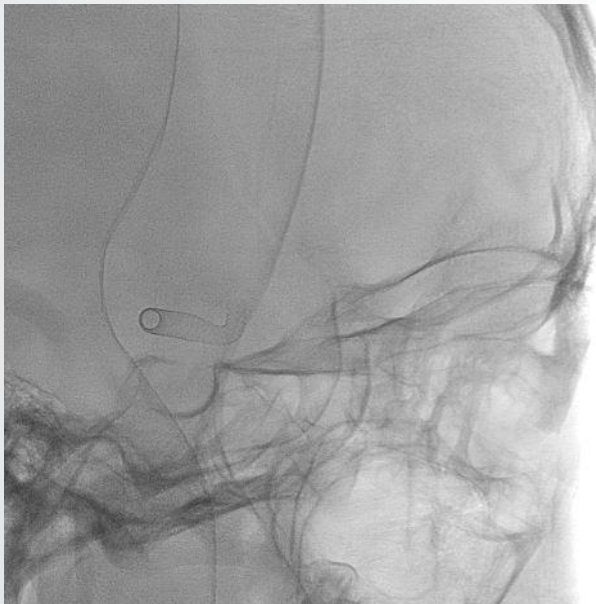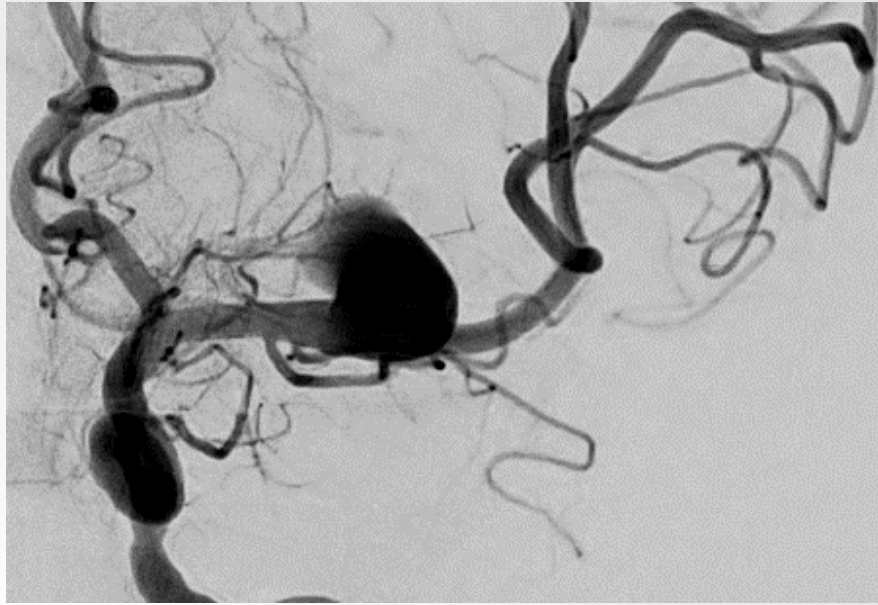
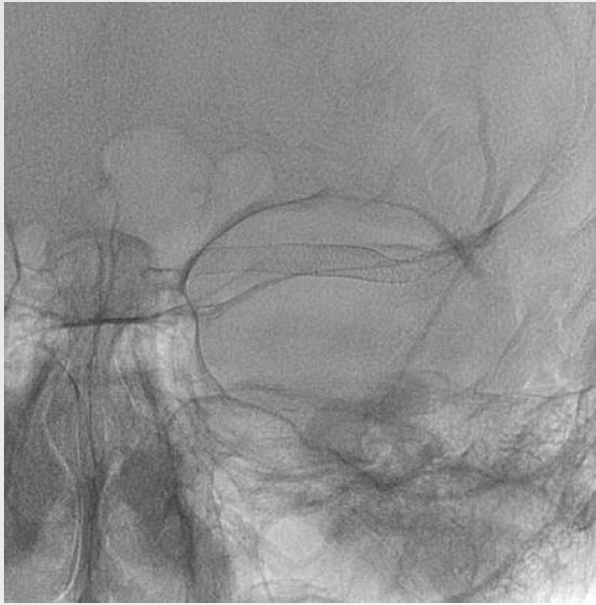
TREATMENT PLAN

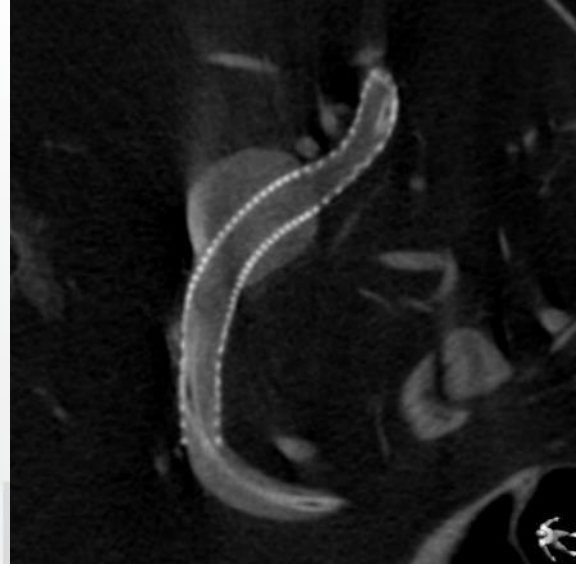
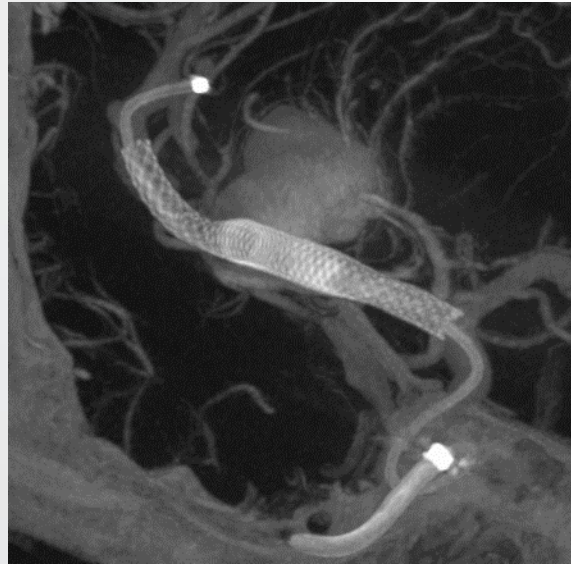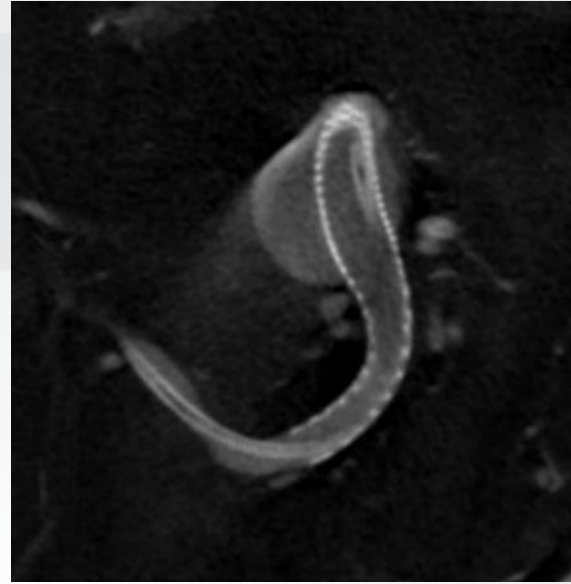
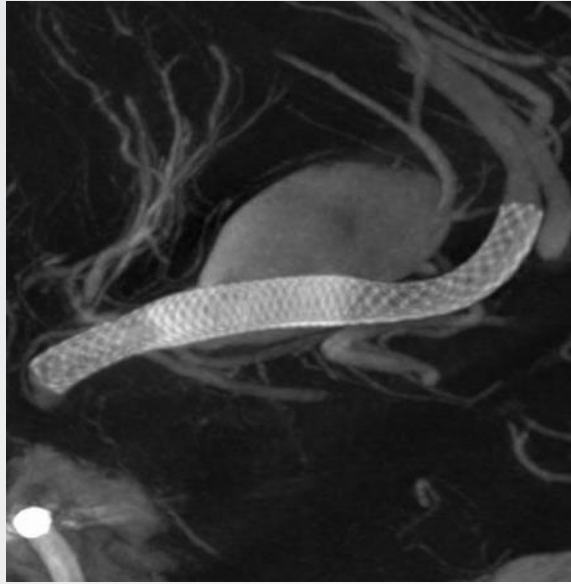
- Flow diverter stent

TREATMENT

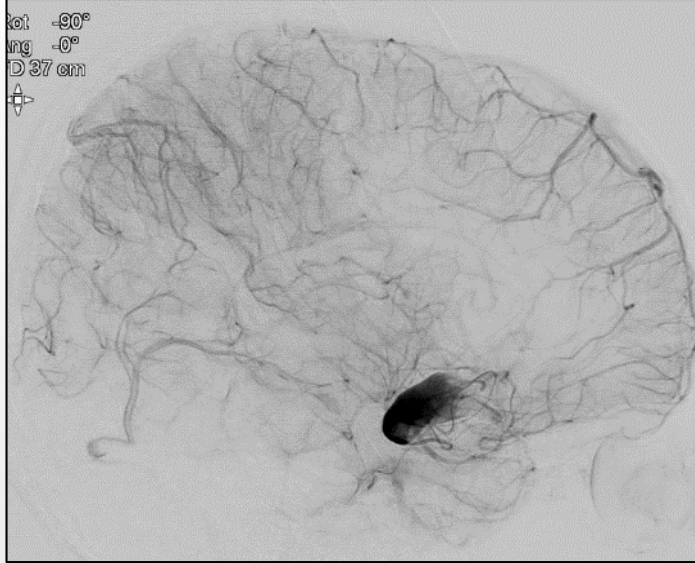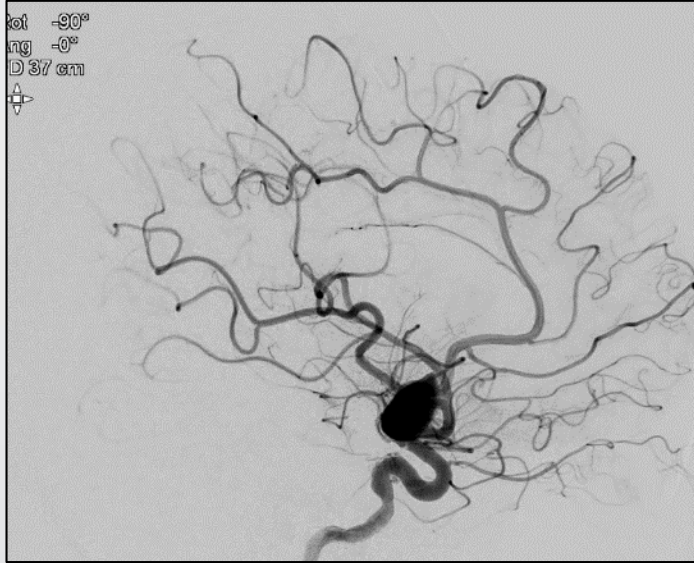
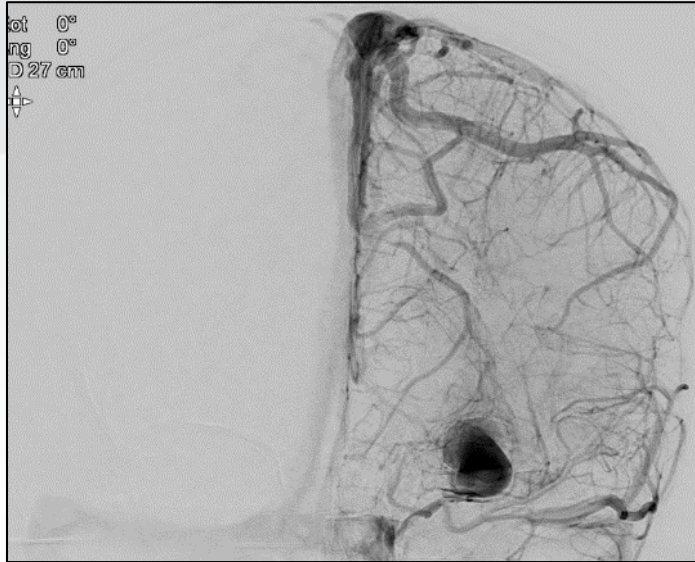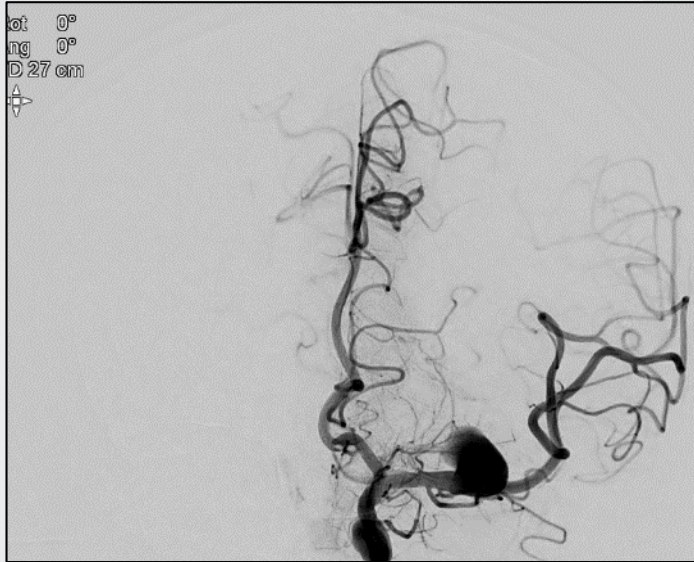


Size of the aneurysm : 23x14 mm
FD stent: Pipeline 4mm/35 mm



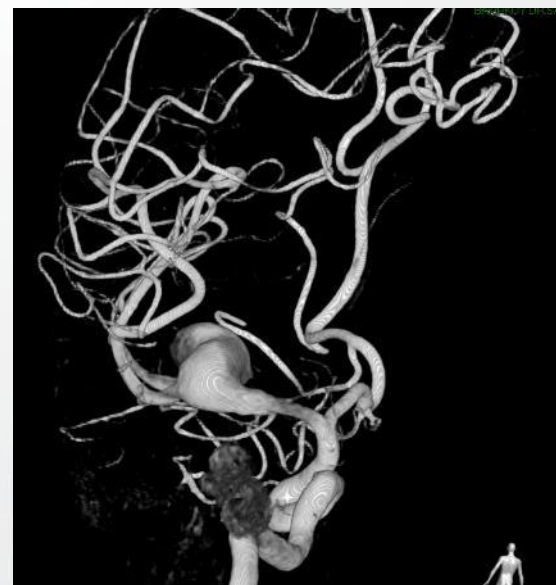
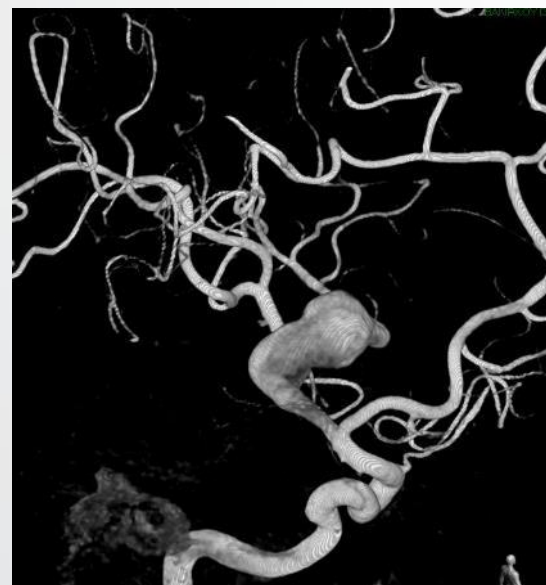
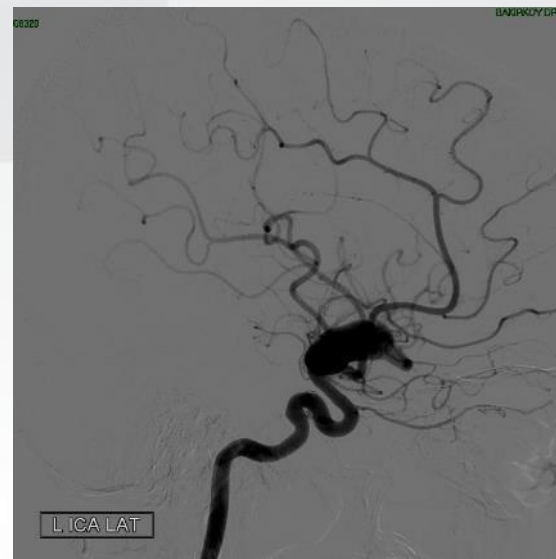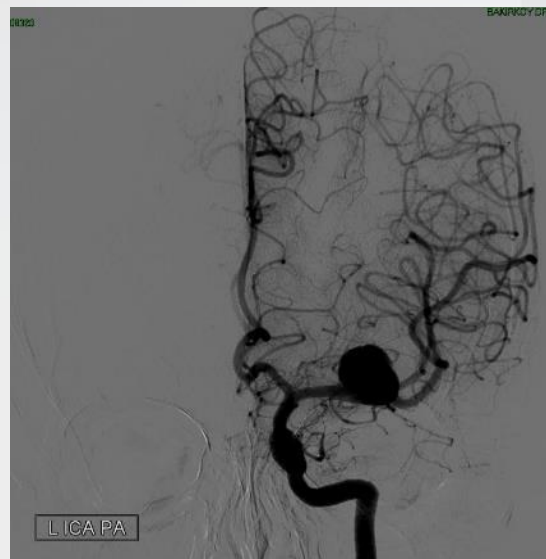POST TREATMENT



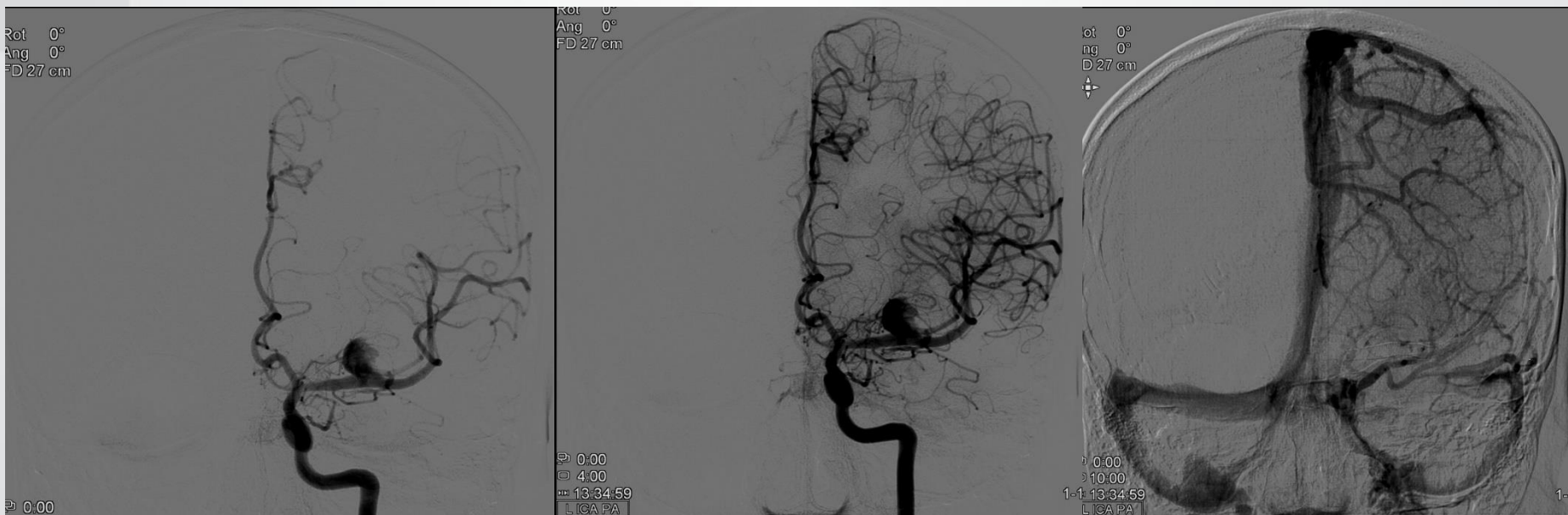
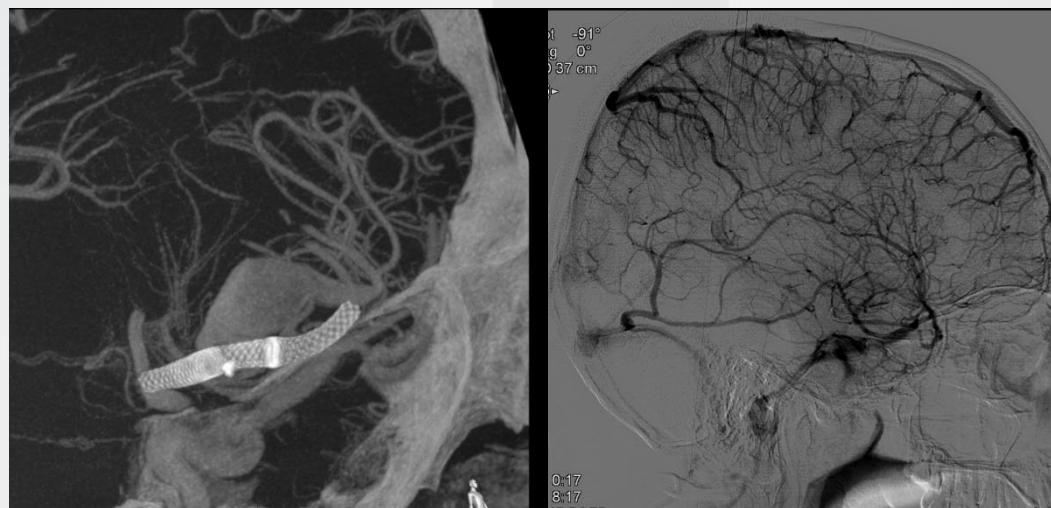
FOLLOW UP

DSA 20.06.2017



FOLLOW UP

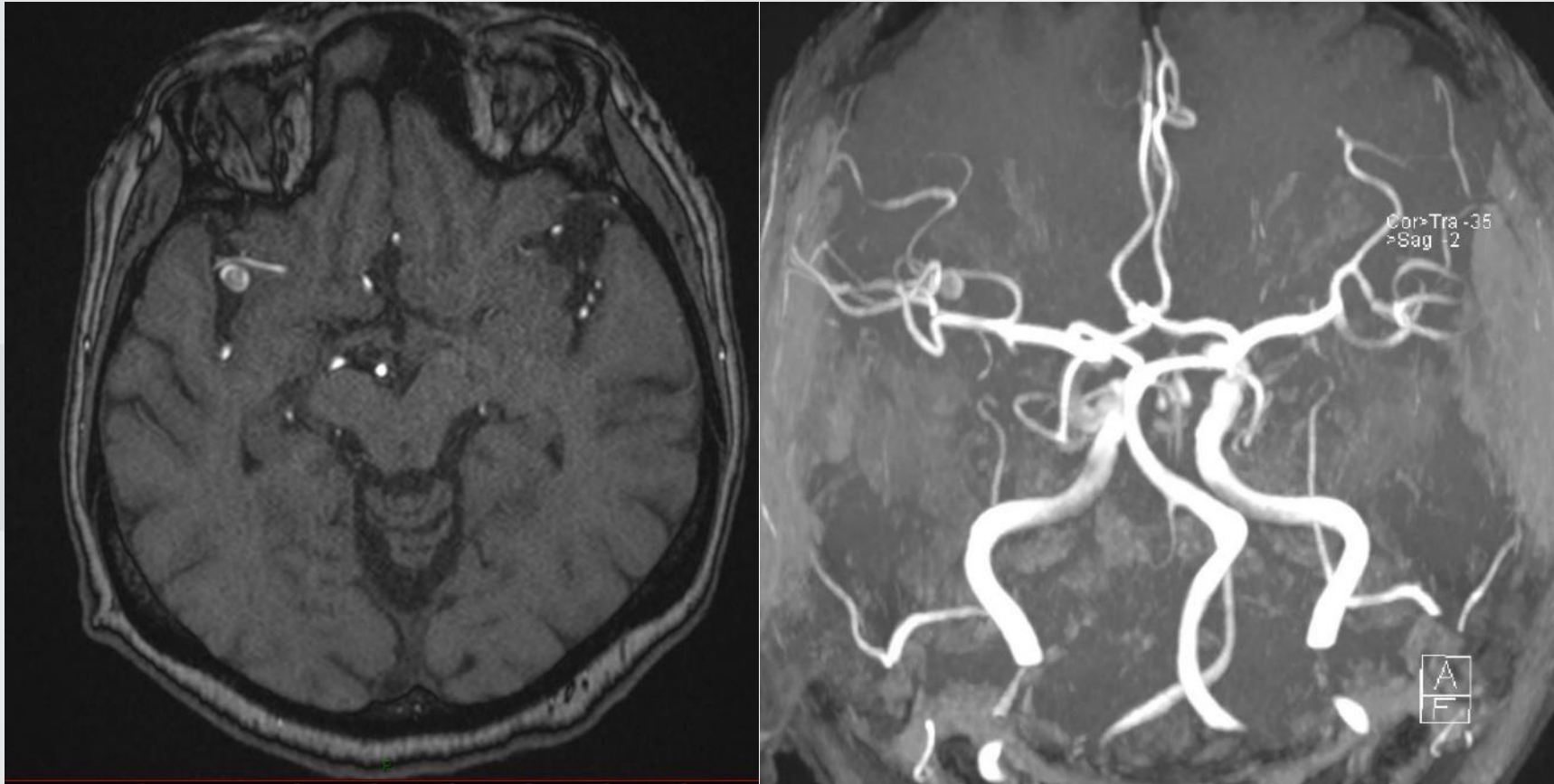
1-2019



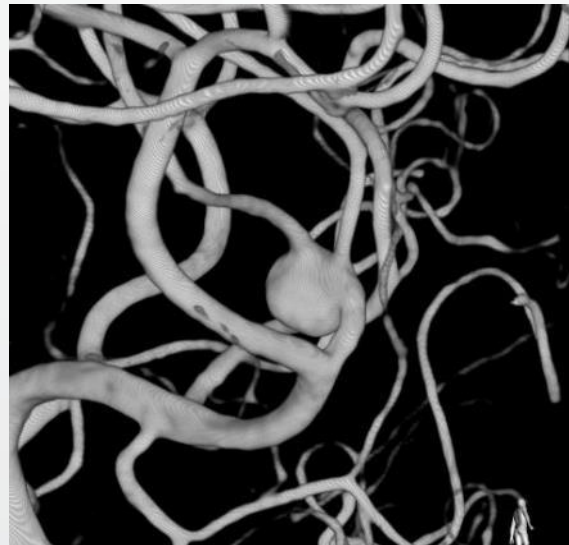
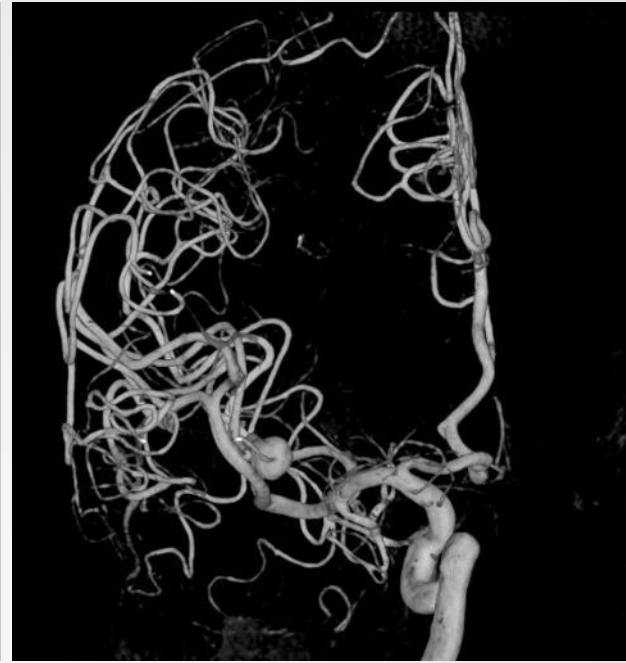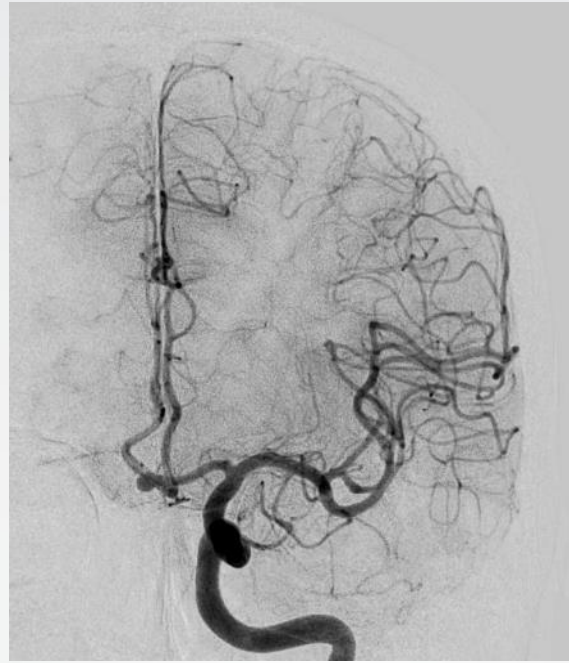
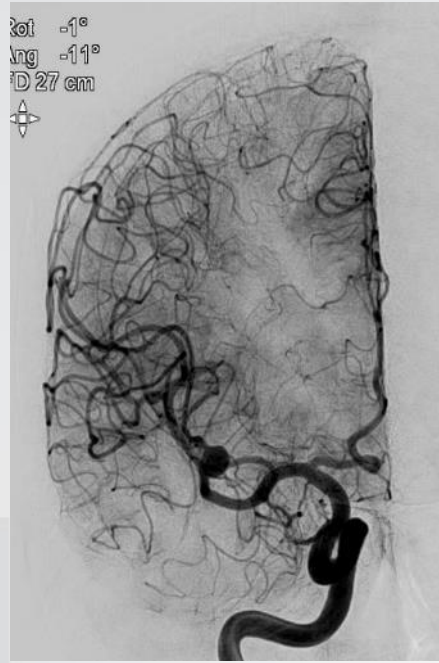PATIENT 4 EK

- 64 Y F
- Presented with headaches
- MRA & DSA:
R MCA M3 segment aneurysm and
AcomA aneurysm





MRA 23.12.2017

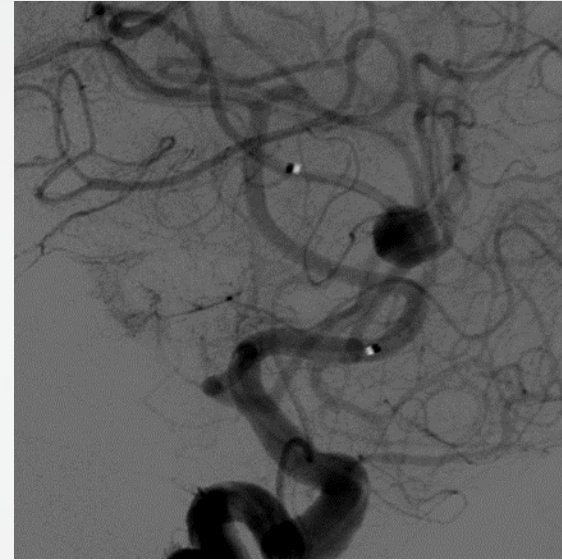
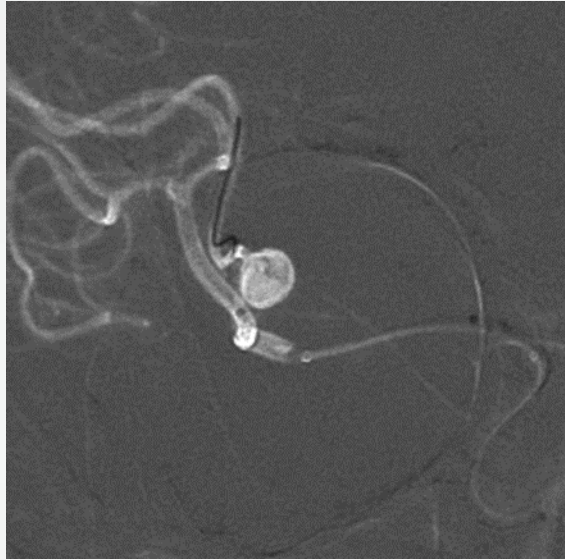
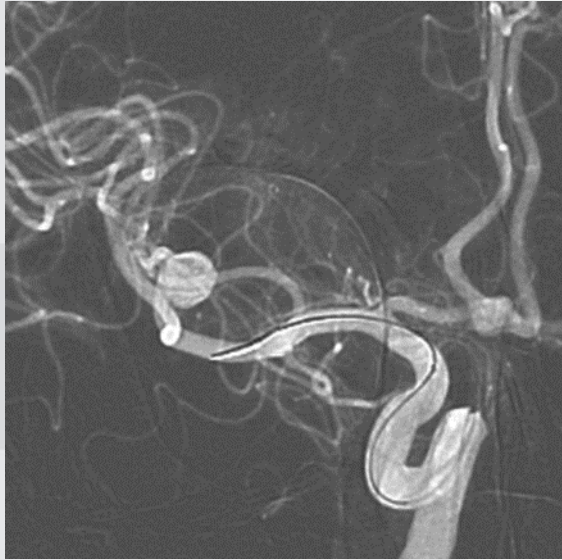
DSA 25.01.2018

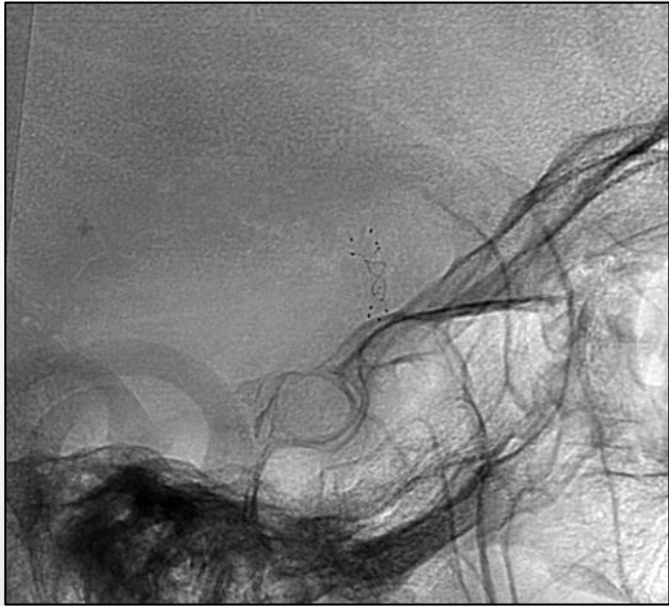
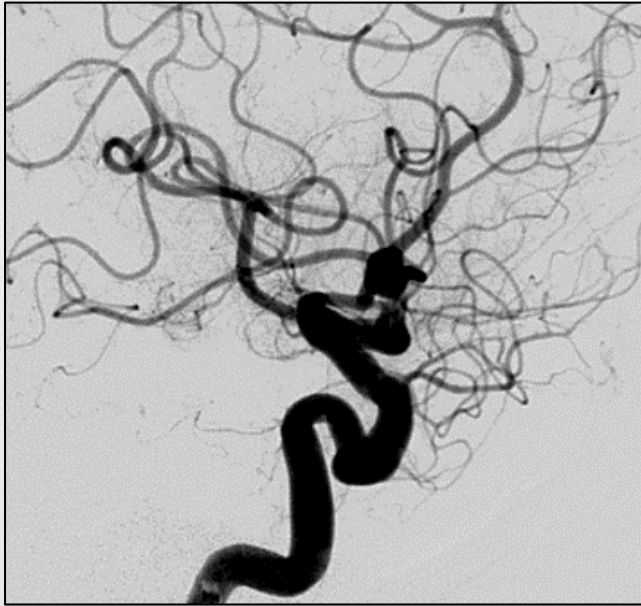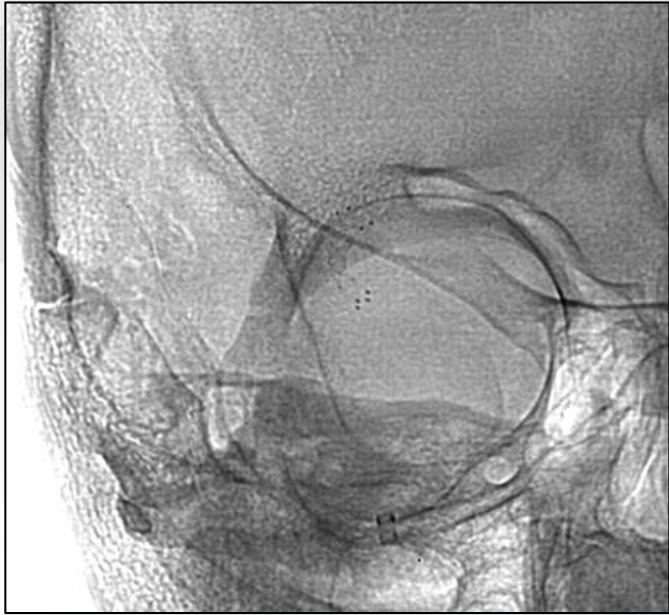
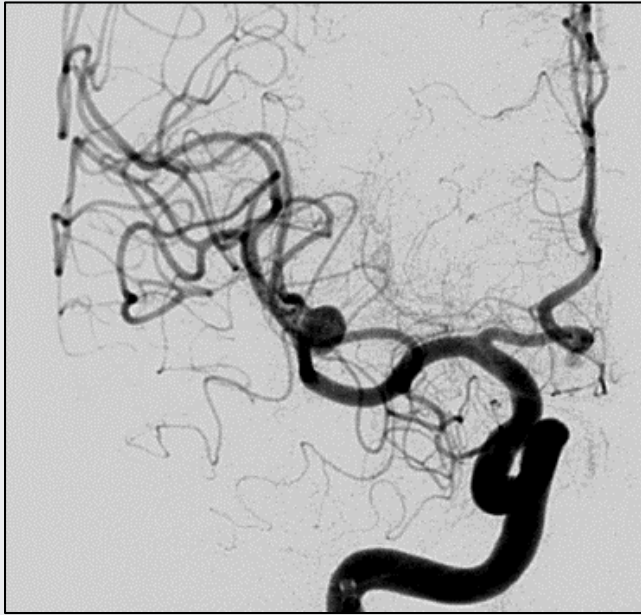
TREATMENT PLAN

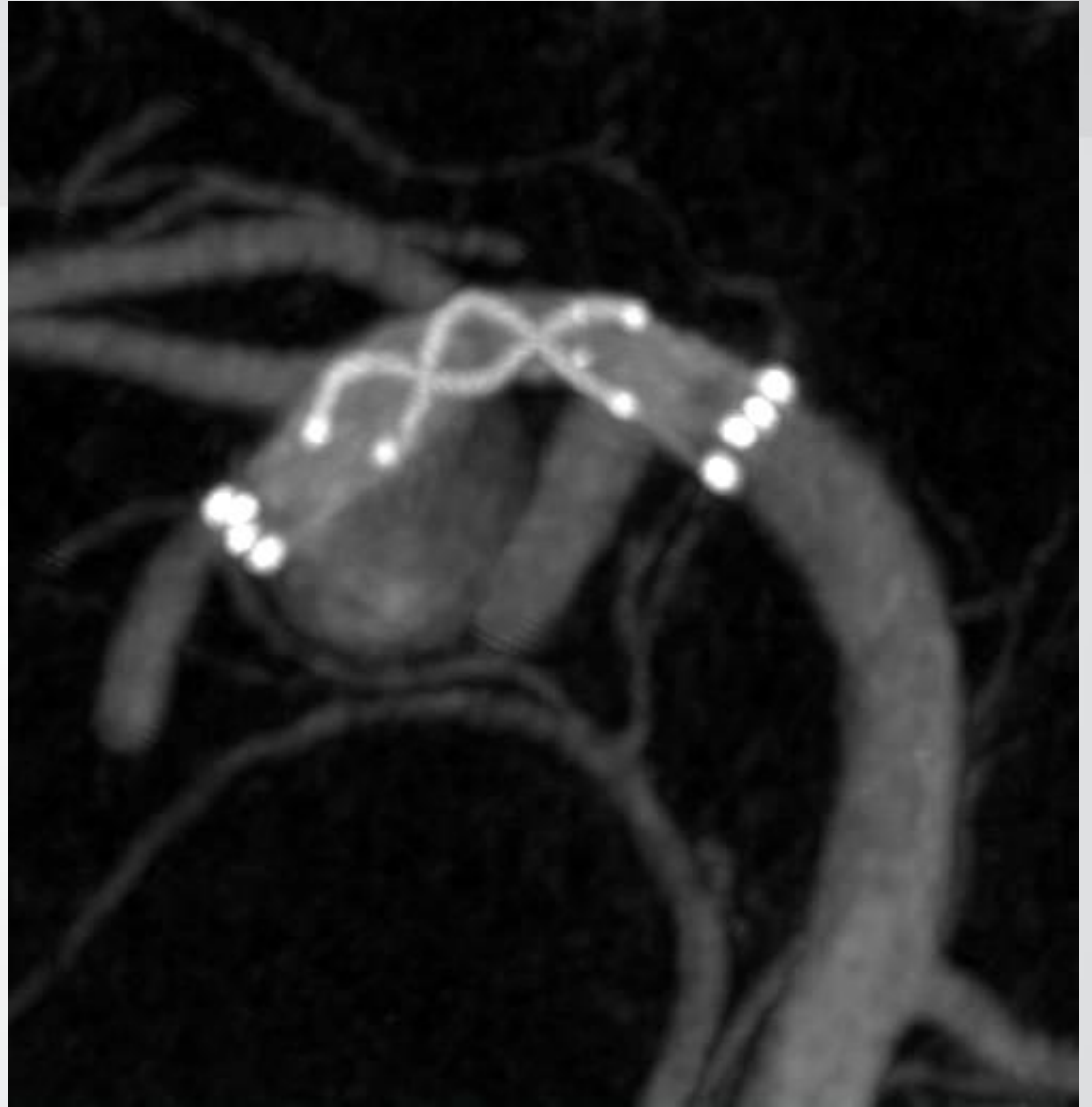
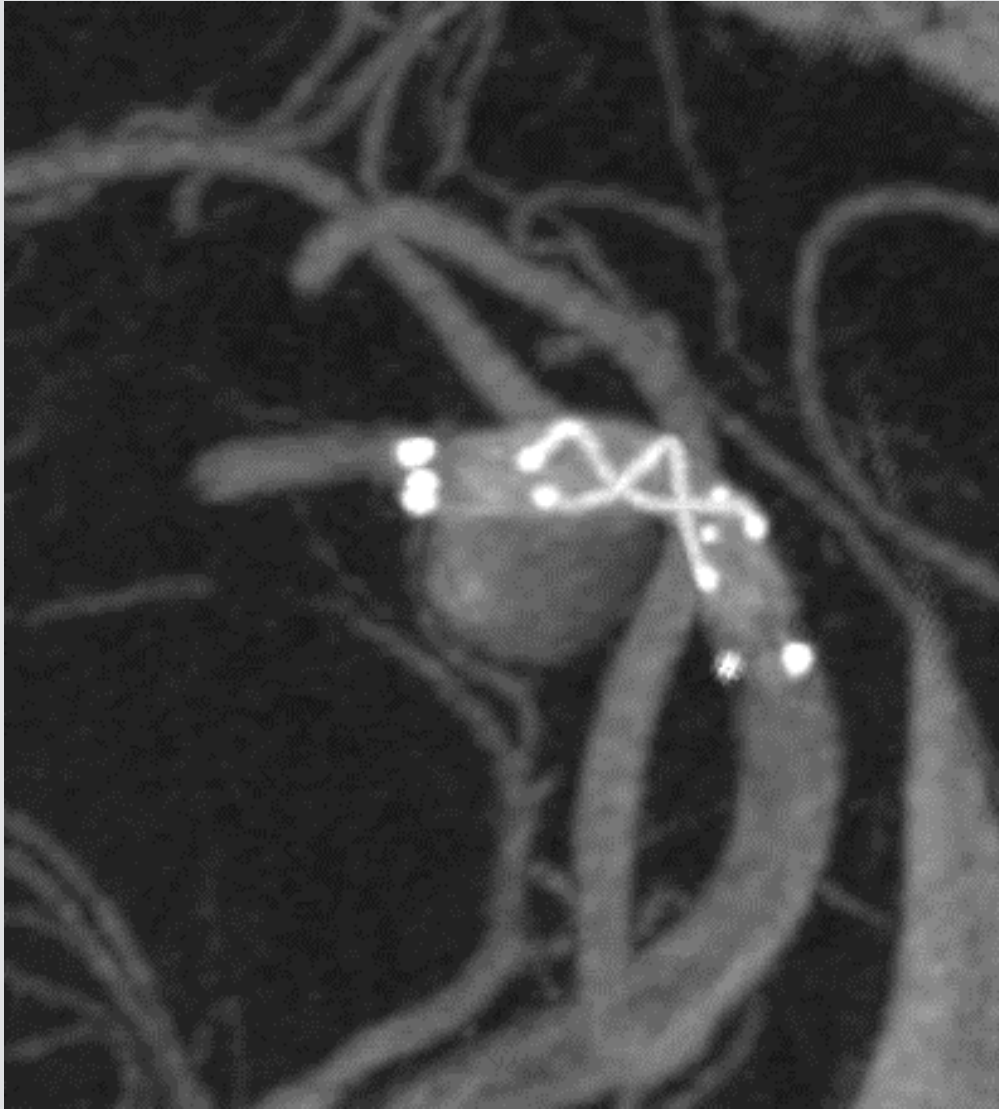- Flow diverter stent

TREATMENT

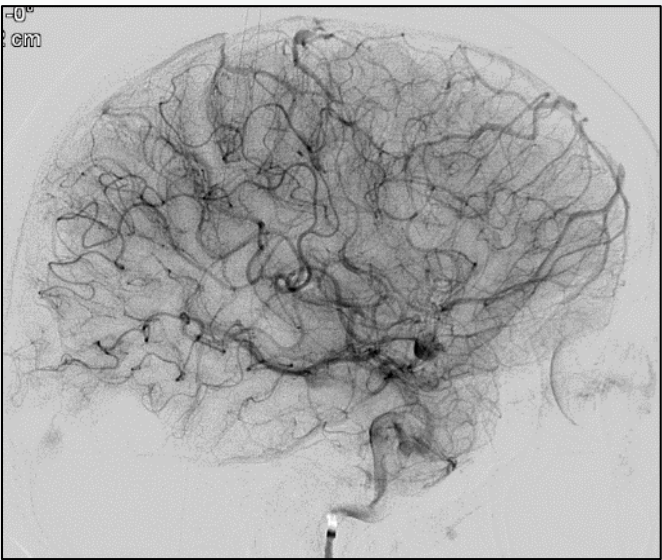
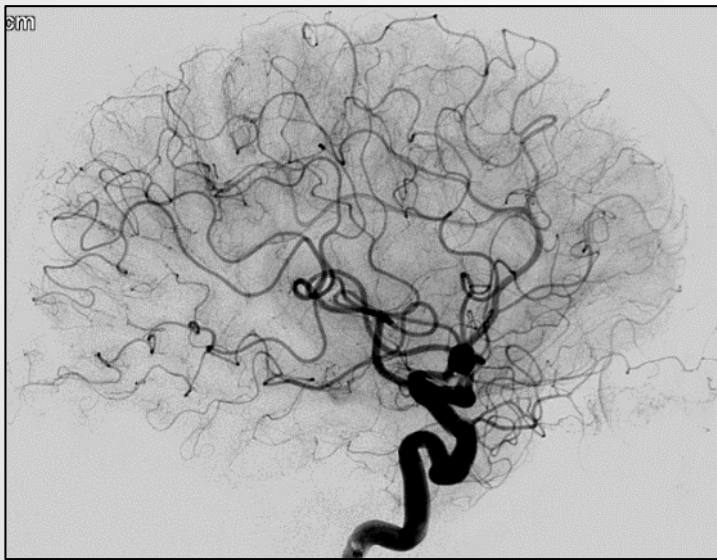
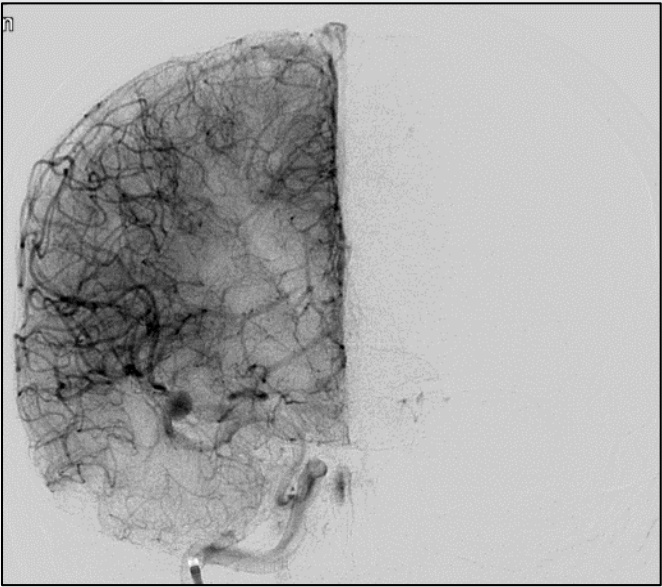
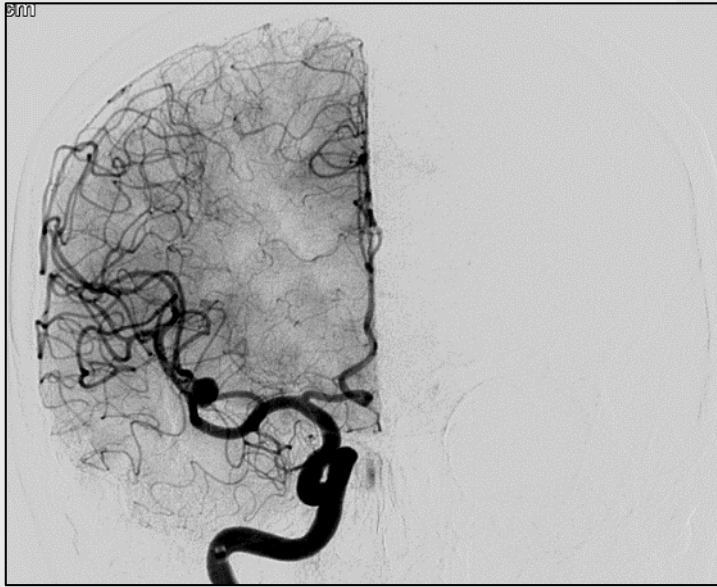


Size of the aneurysm : 7x6 mm
FD stent: FRED Jr. 2,5X13X8mm





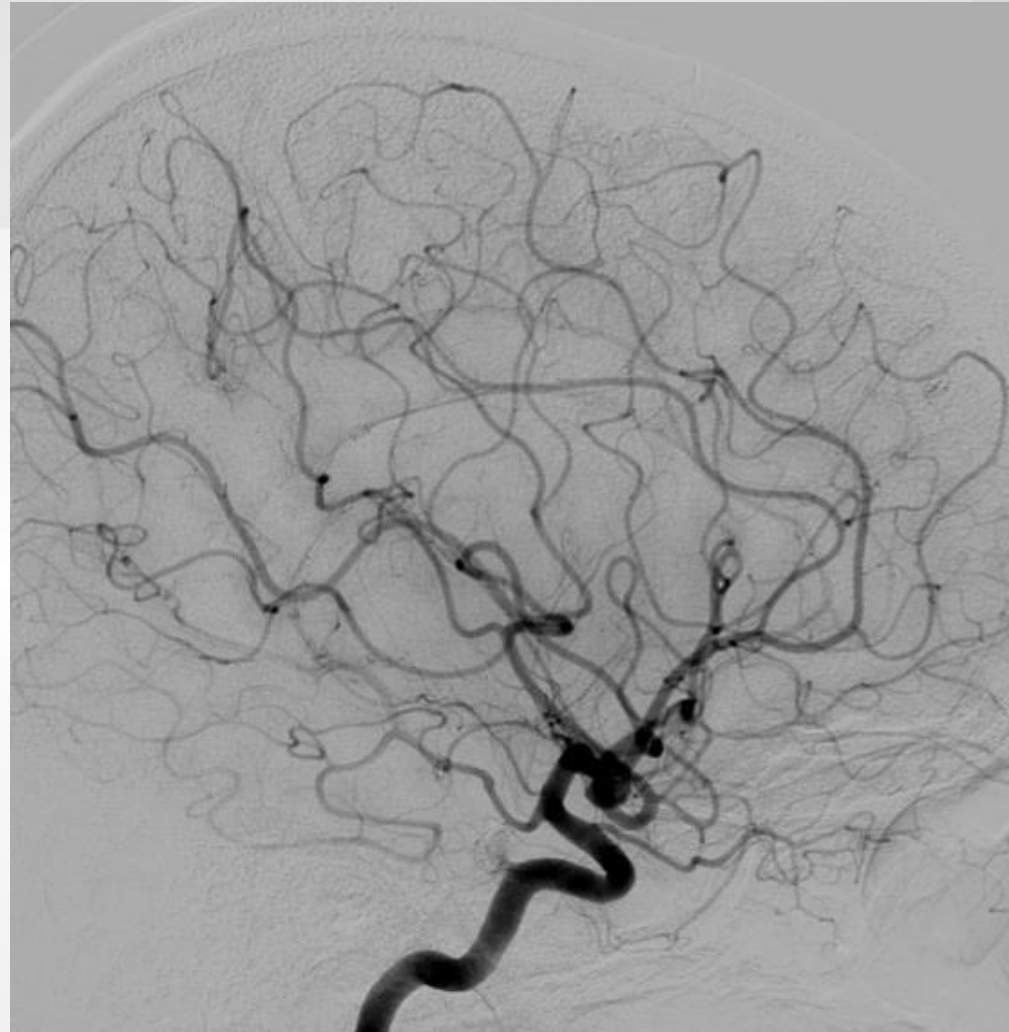
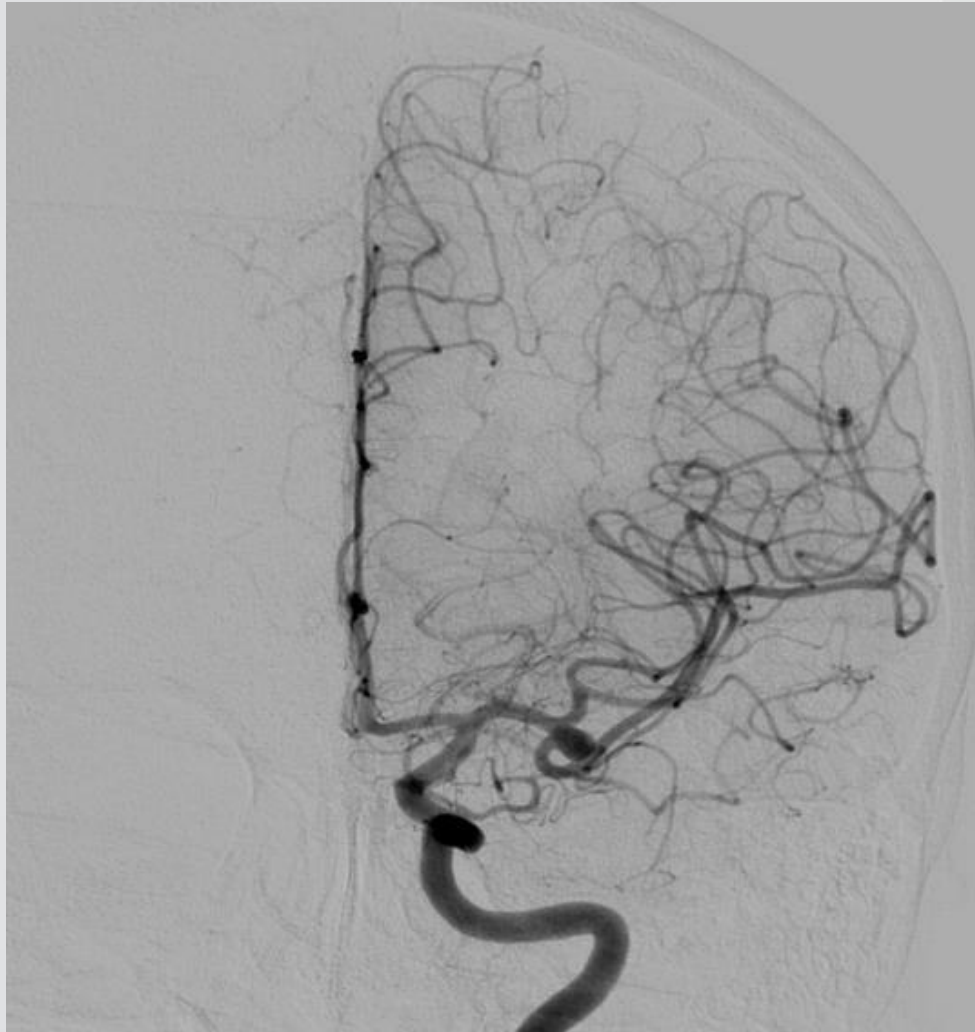POST TREATMENT



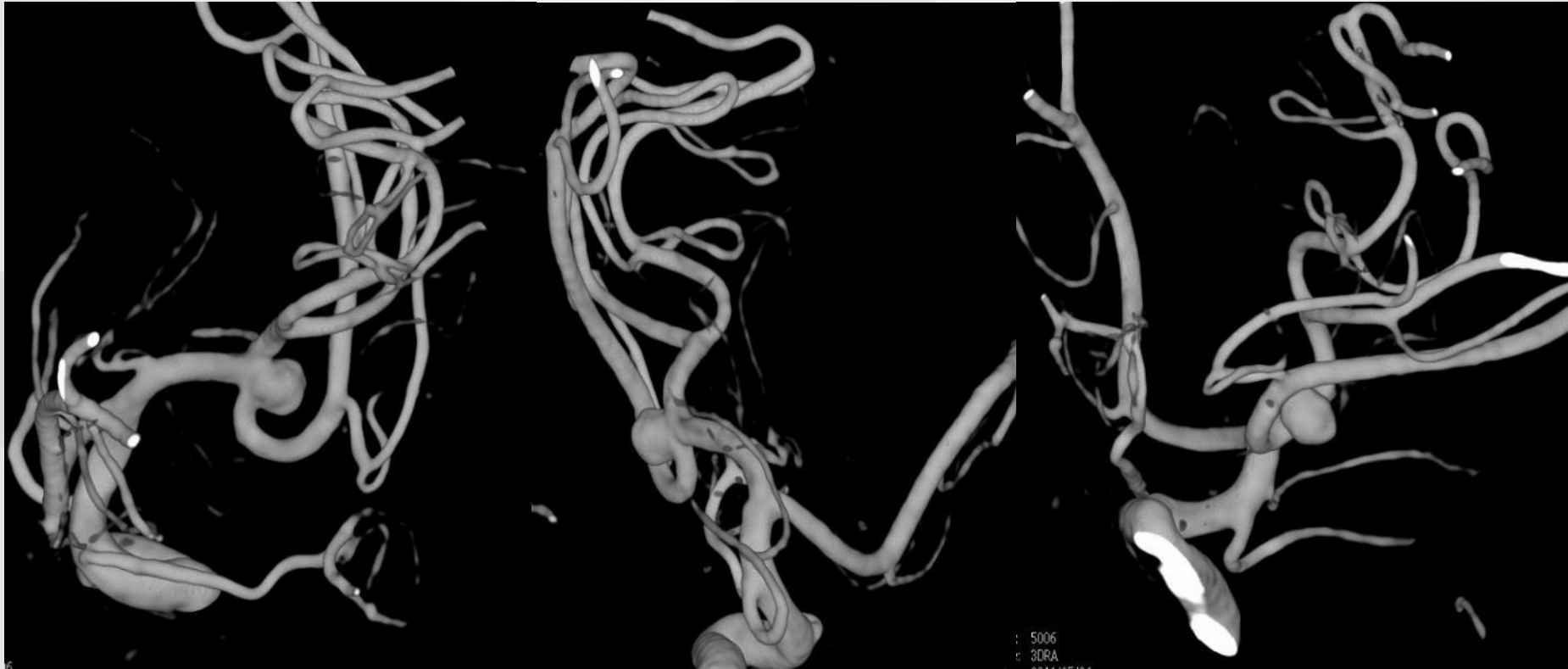
PATIENT 5 CYY

- 58 Y F
- Presented by headache 12 years ago
- Mild renal insufficiency:
Cr: 1,18 mg/dl, Urea: 69 mg/dl
- MRA-DSA:
L MCA M1-M2 bifurcation aneurysm



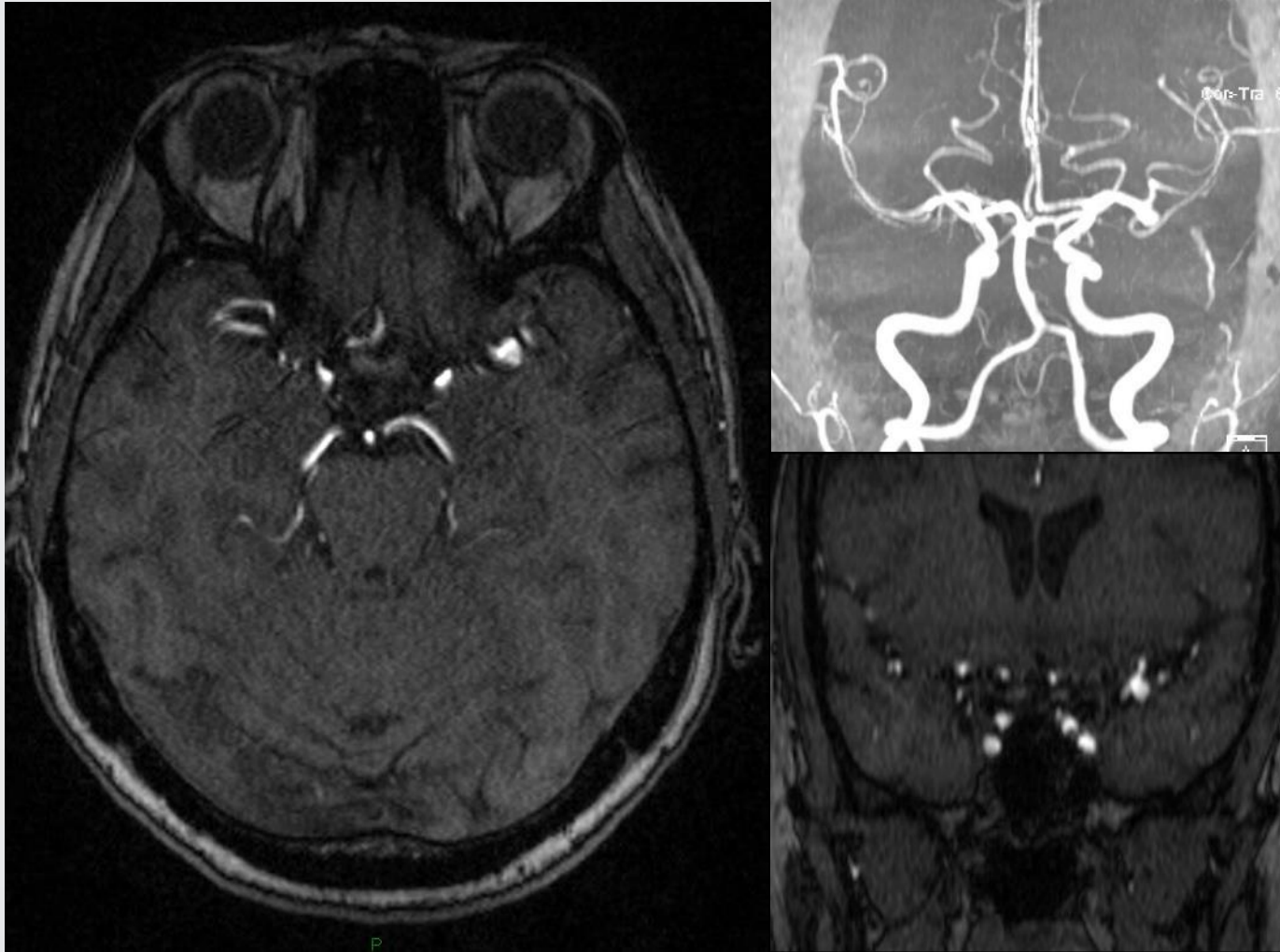


DSA 04.05.2018



DSA 04.05.2011

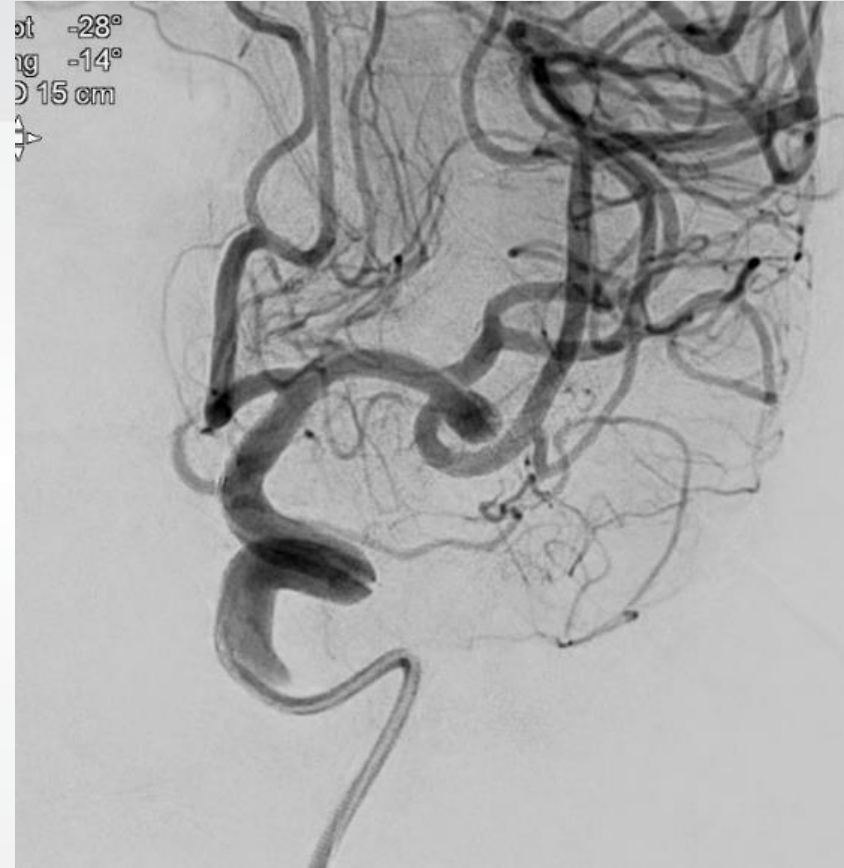
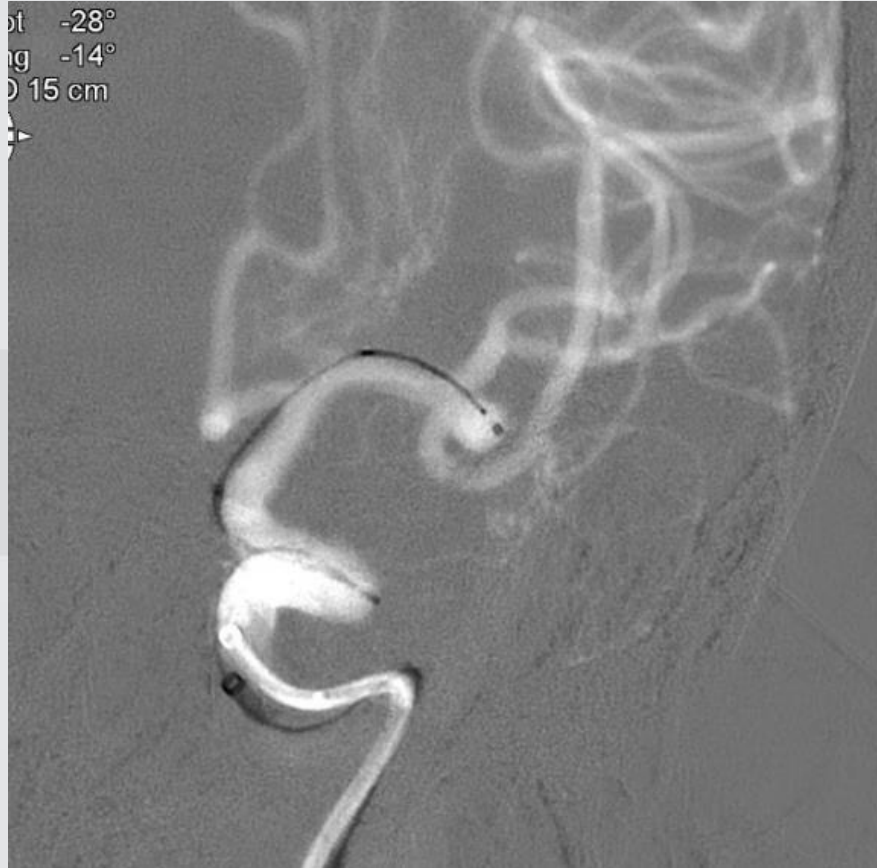MRA 11.04.2018



TREATMENT PLAN

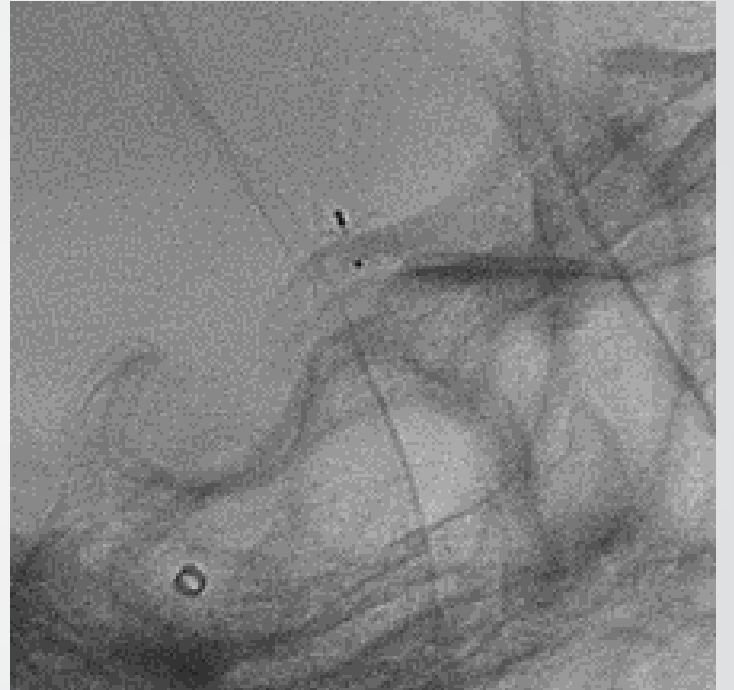
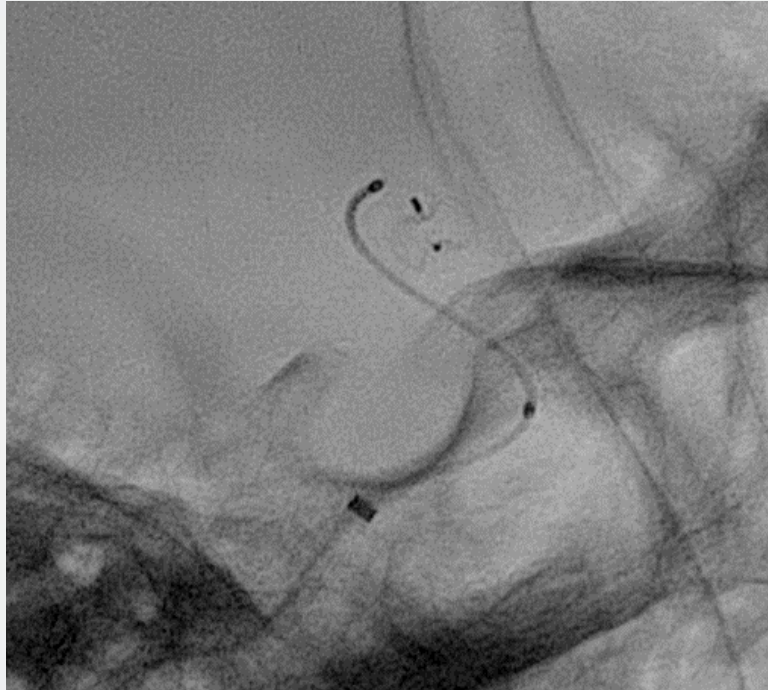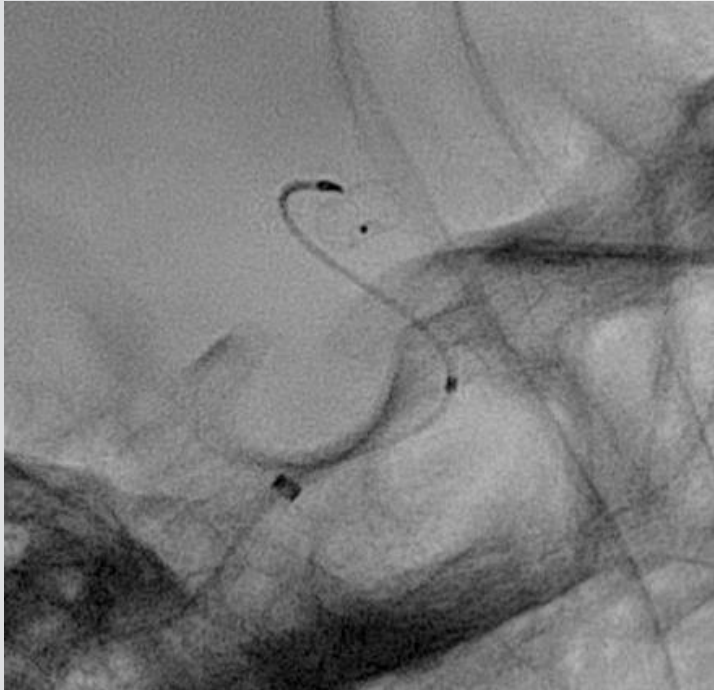
- WEB (Woven Endobridge)

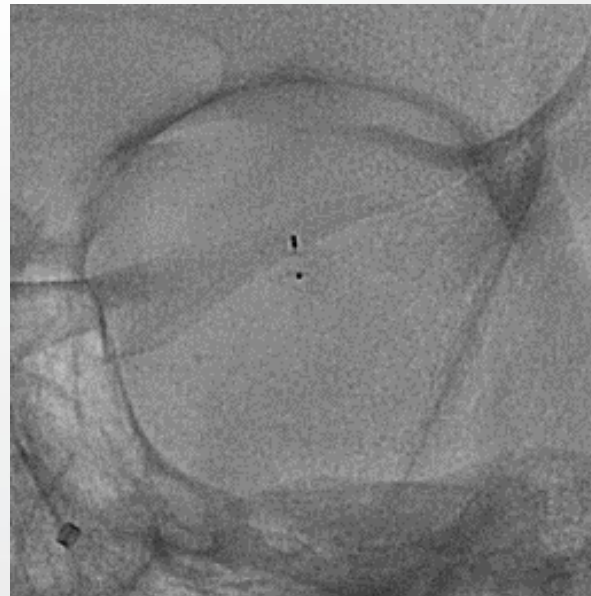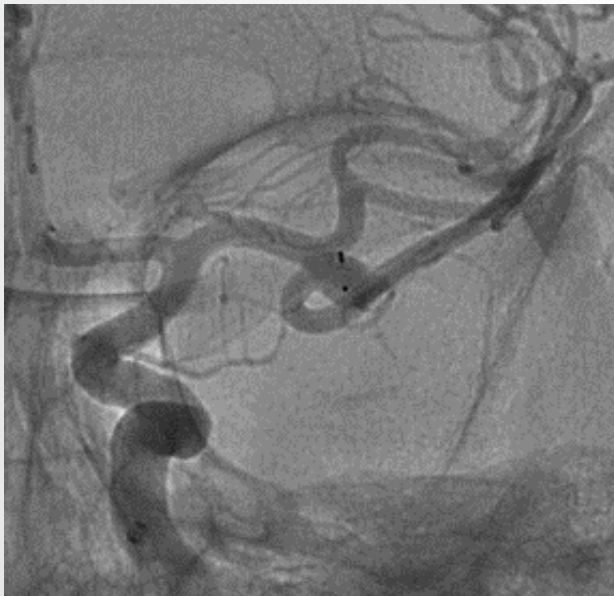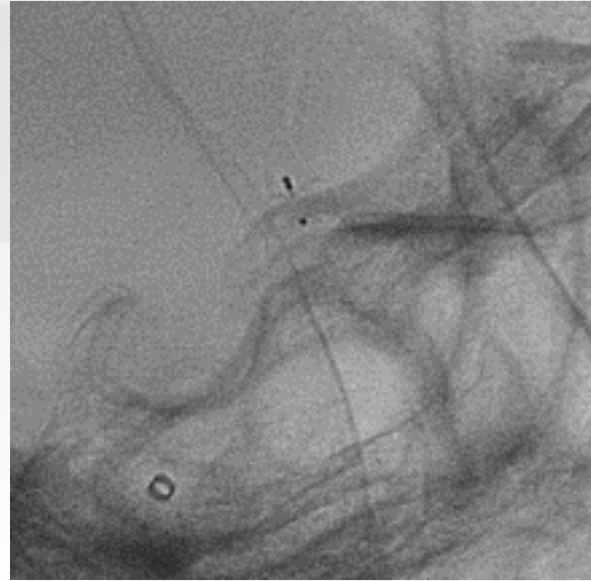
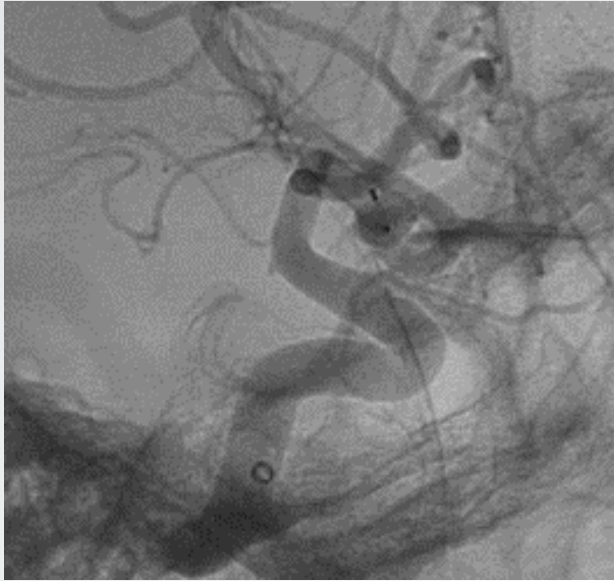
TREATMENT

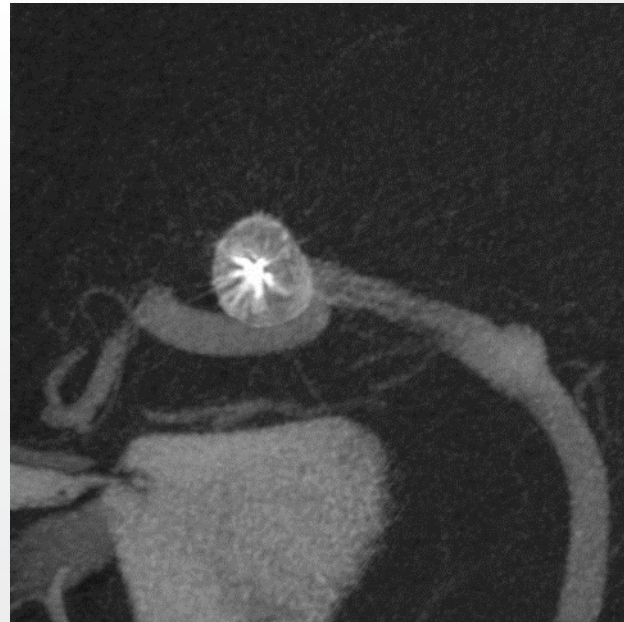
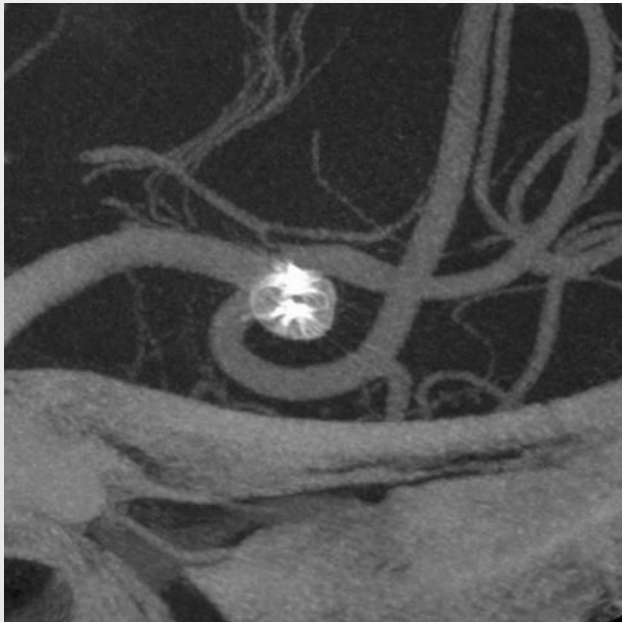
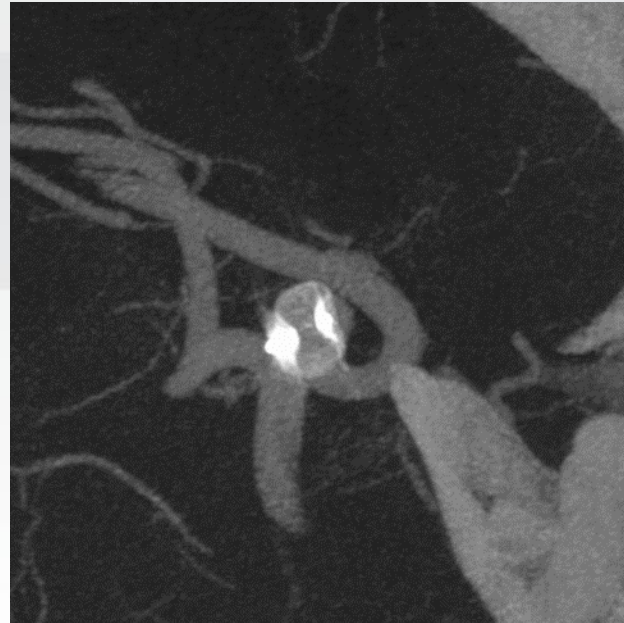
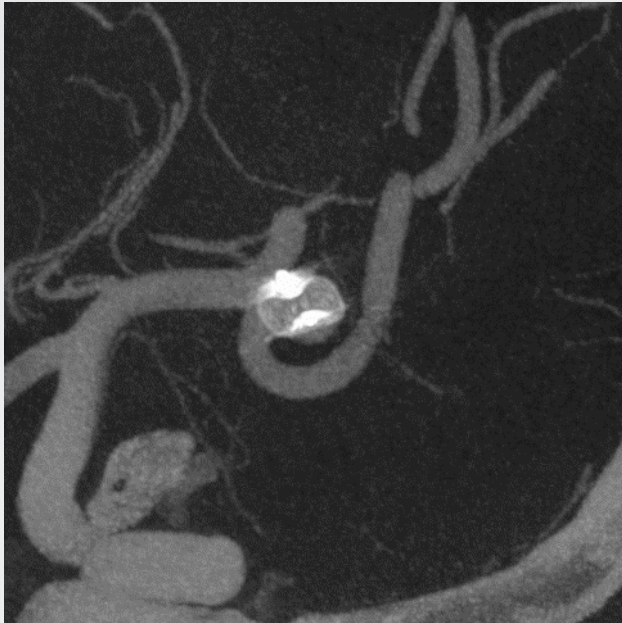

Size of the aneurysm : 4x4,5 mm

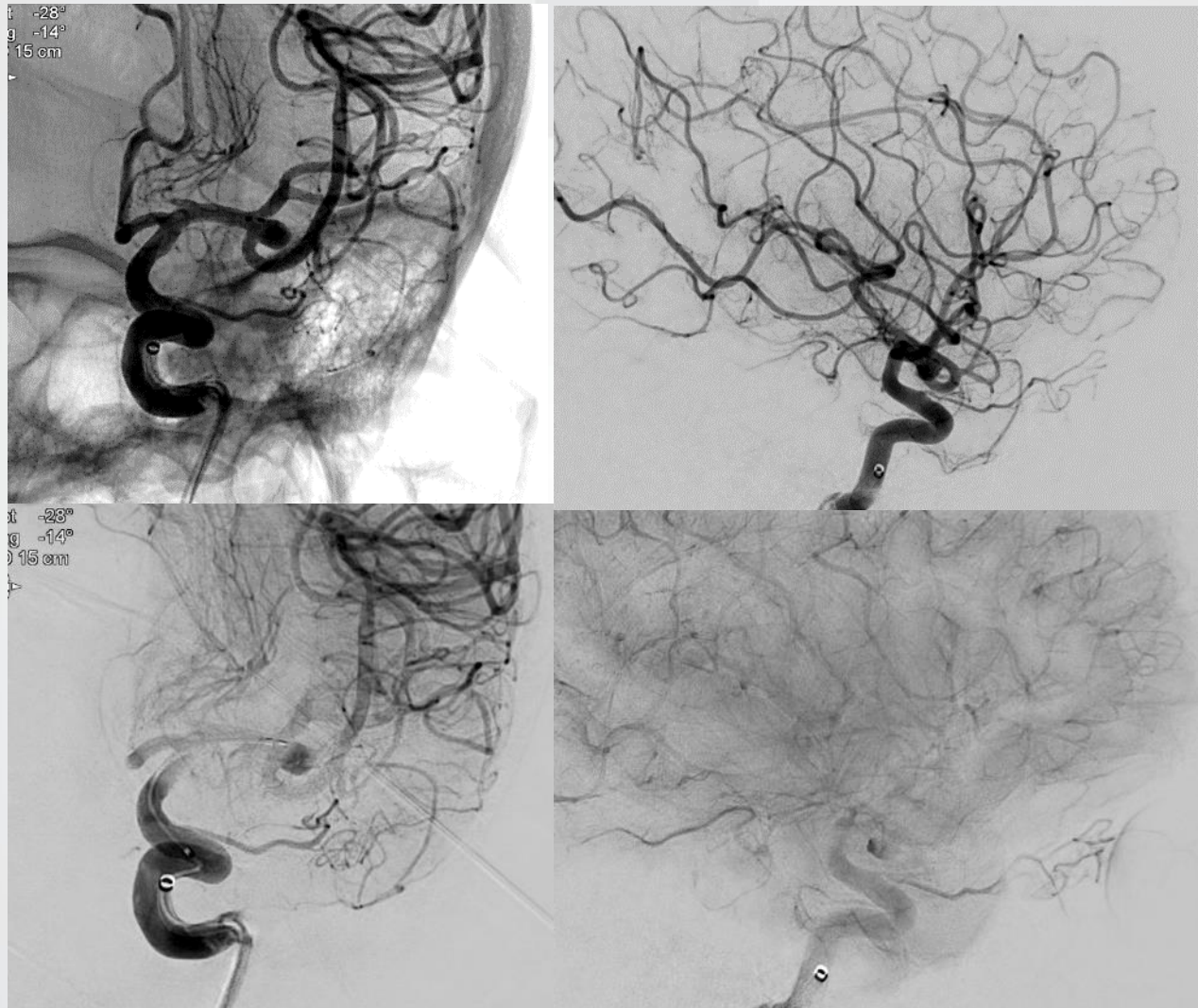
WEB SL aneurysm embolization system 5/3 mm





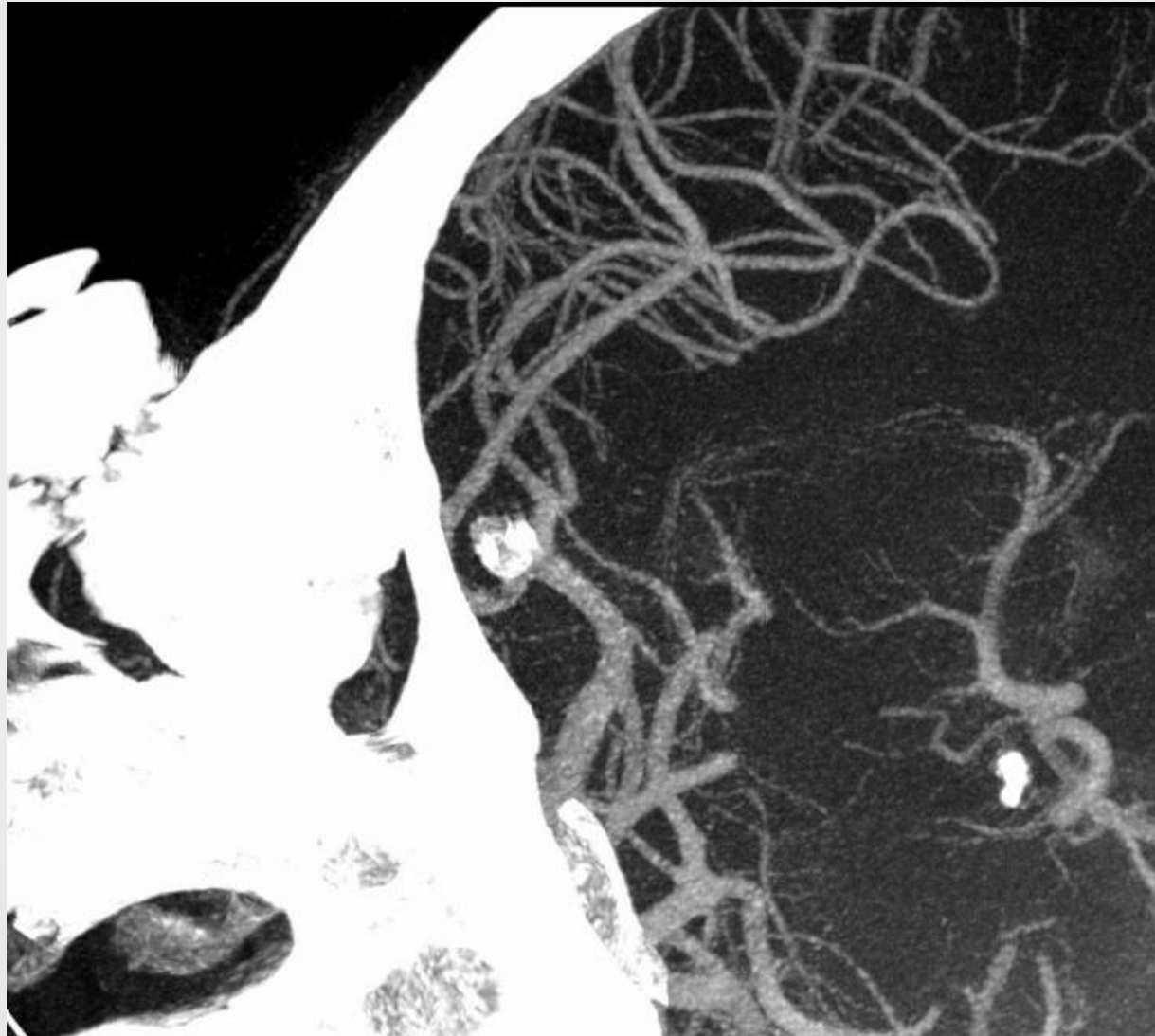


POST TREATMENT



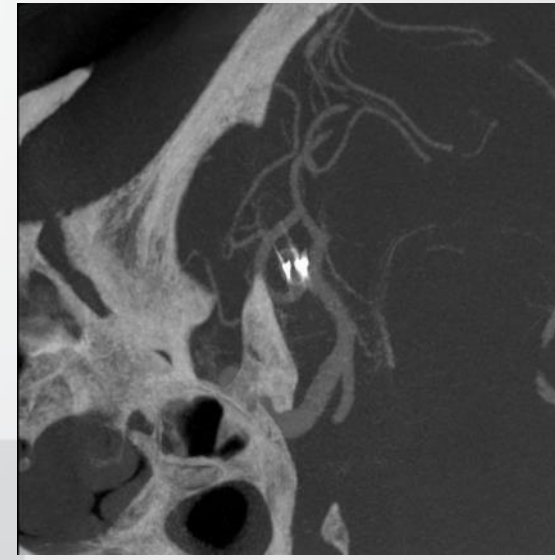
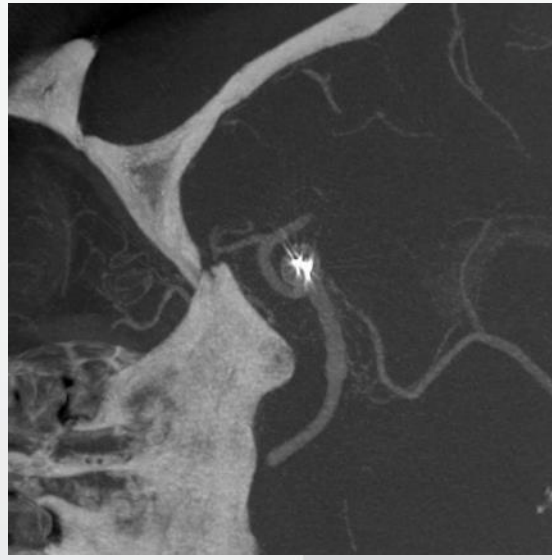
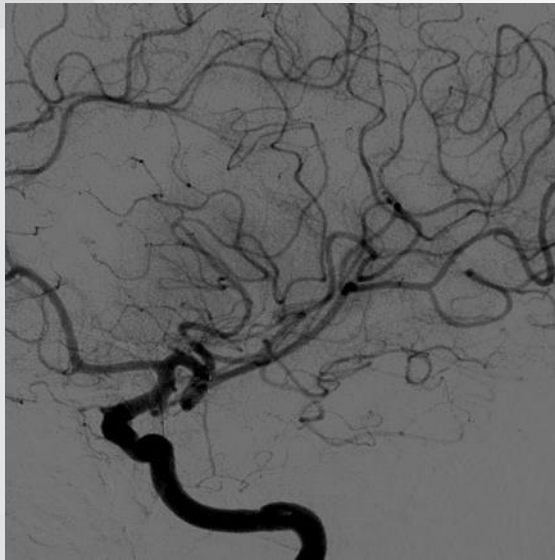
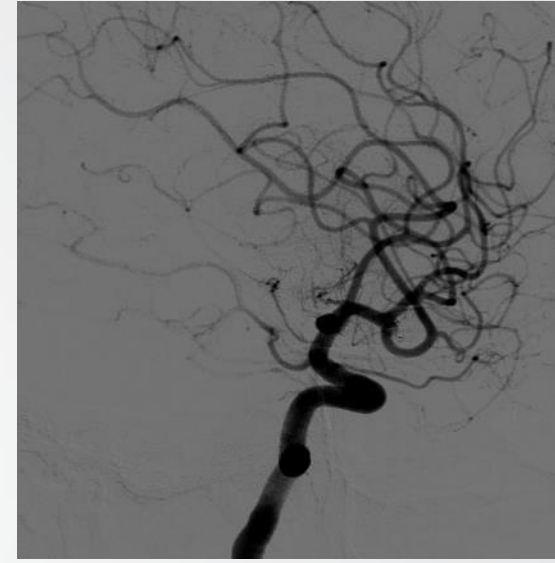
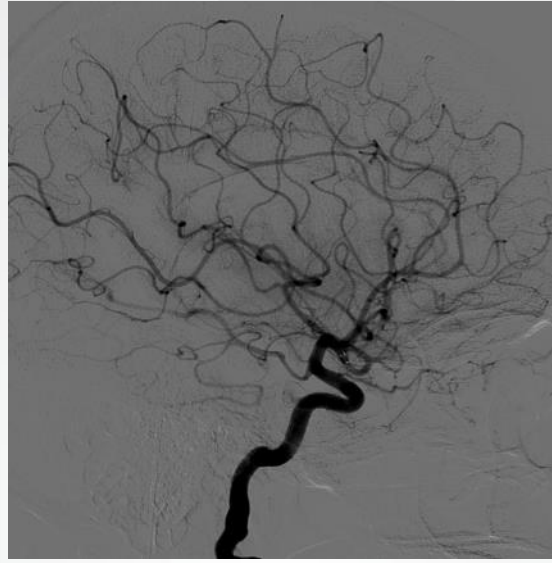
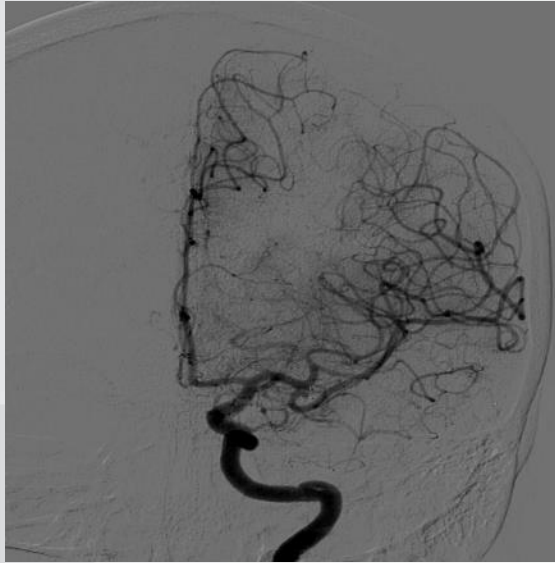FOLLOW UP

22.06.2018 Vaso CT



FOLLOW UP

22.10.2018 DSA

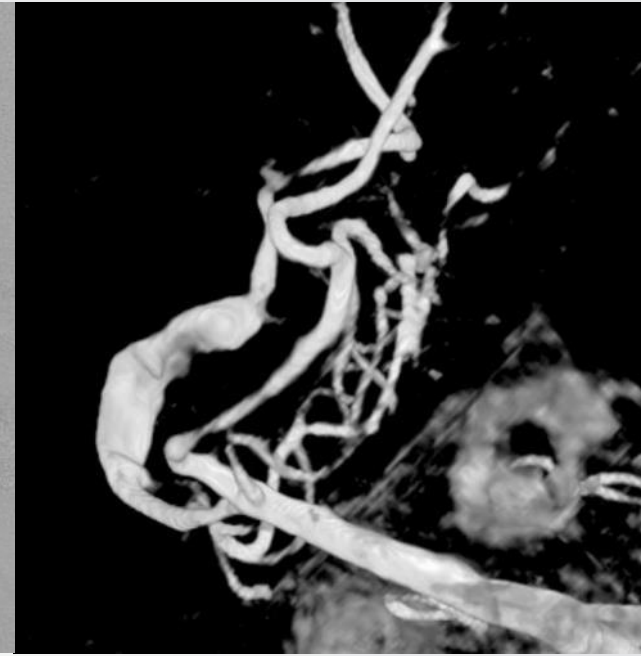
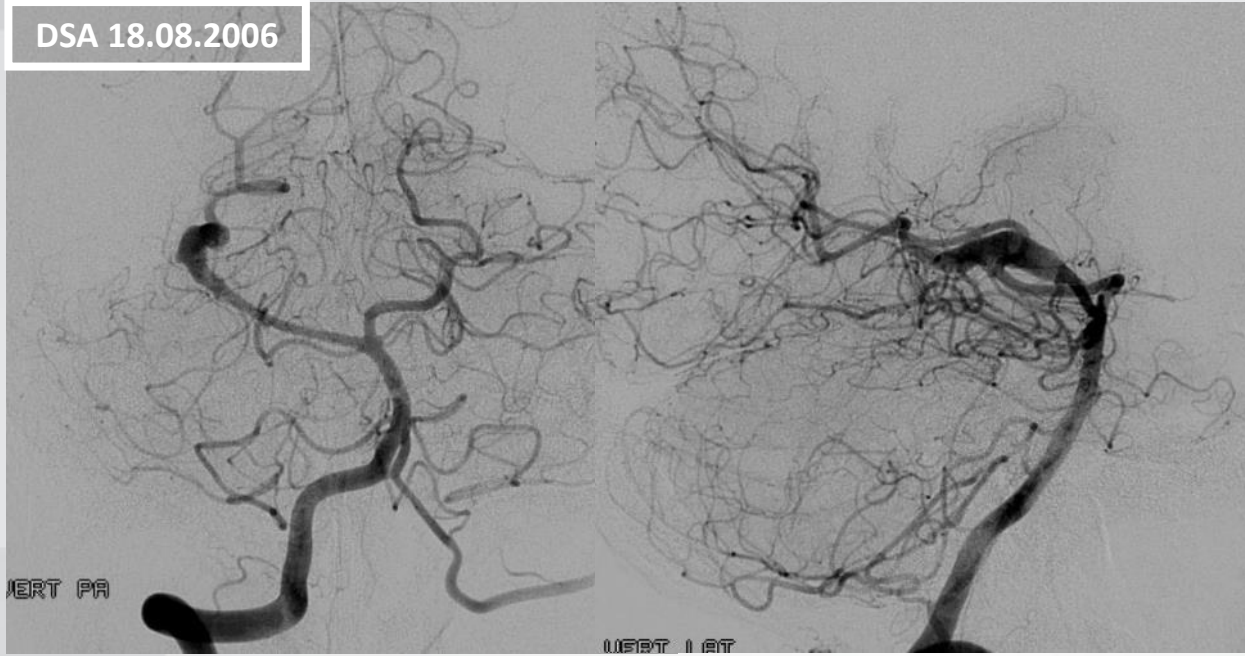

PATIENT 6 IK

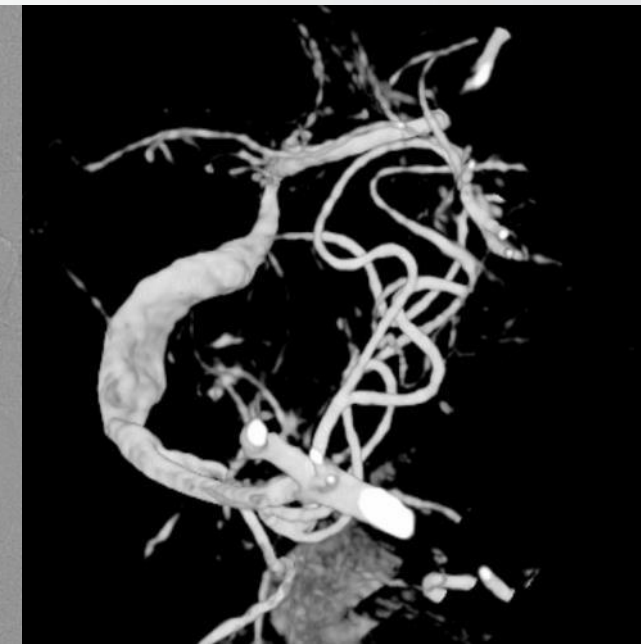
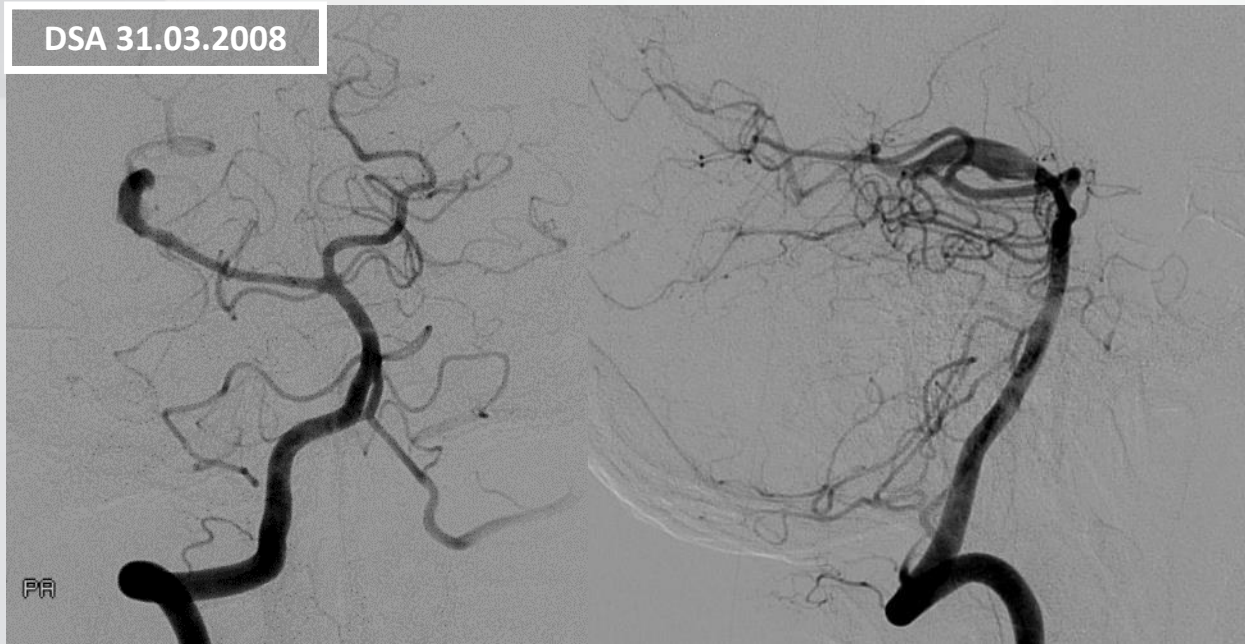- 44 Y M
- 2006 Presented with headaches MRI & DSA:
R PCA P2 segment fusiform aneurysm
- 2008 DSA no change
- 2017 DSA: progressive enlargement of lumen
and thrombosed part of aneurysm

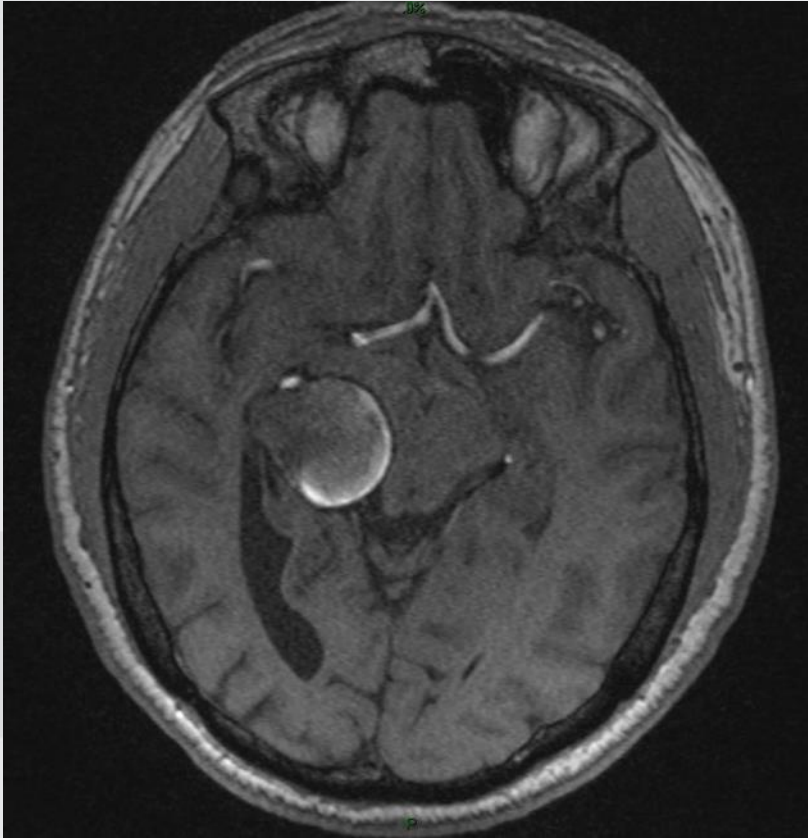


DSA 18.08.2006

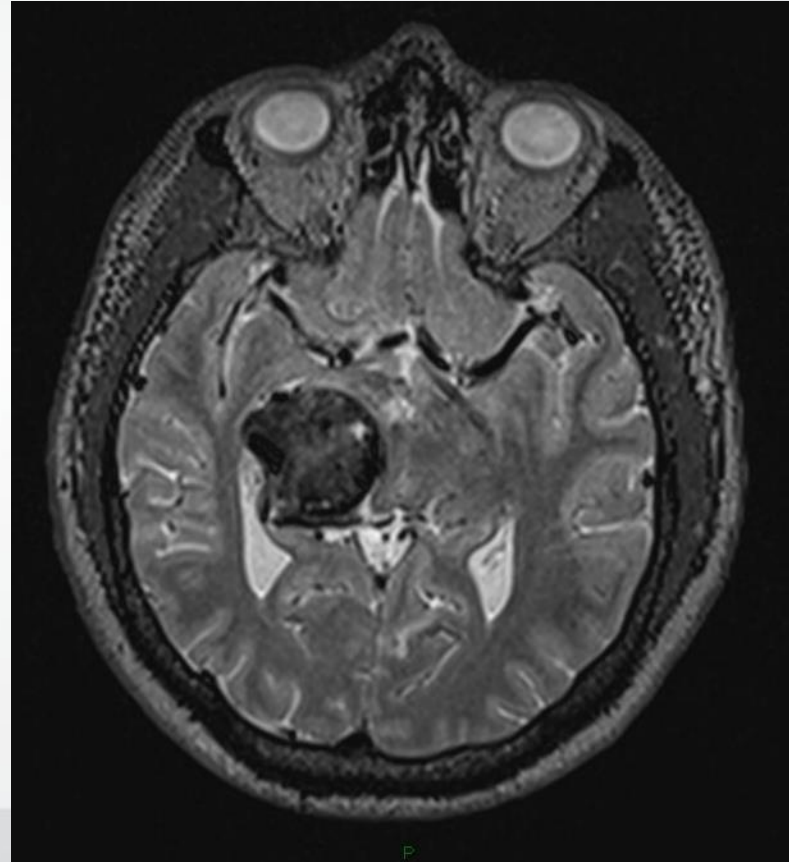


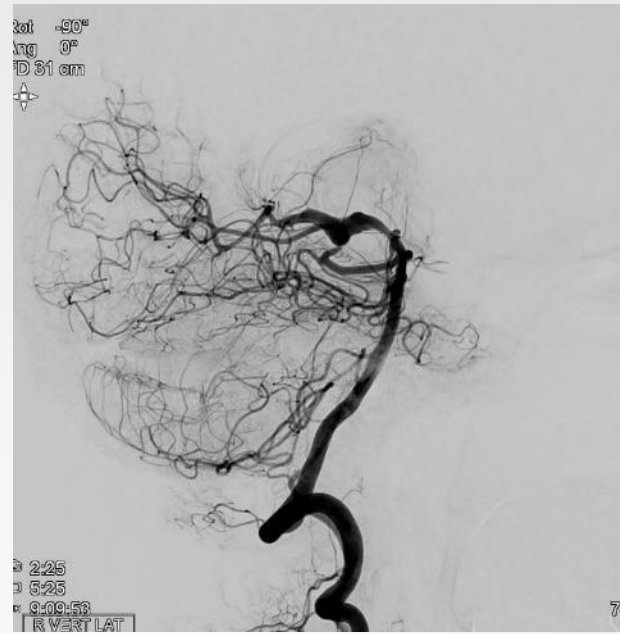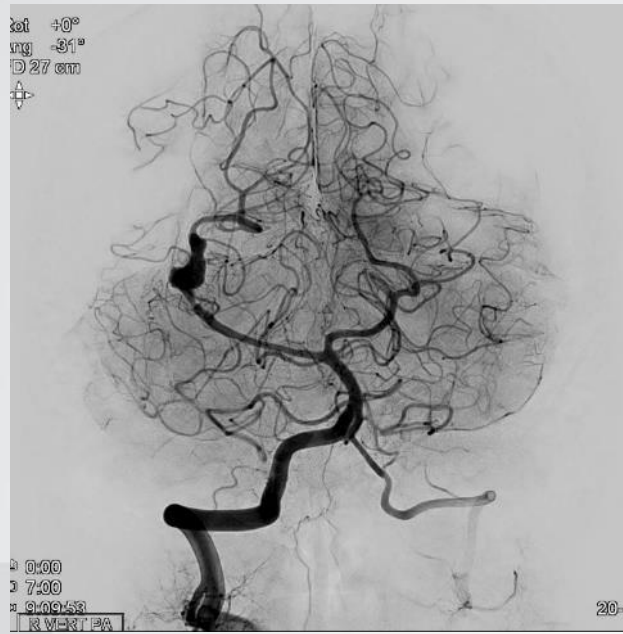
DSA 31.03.2008



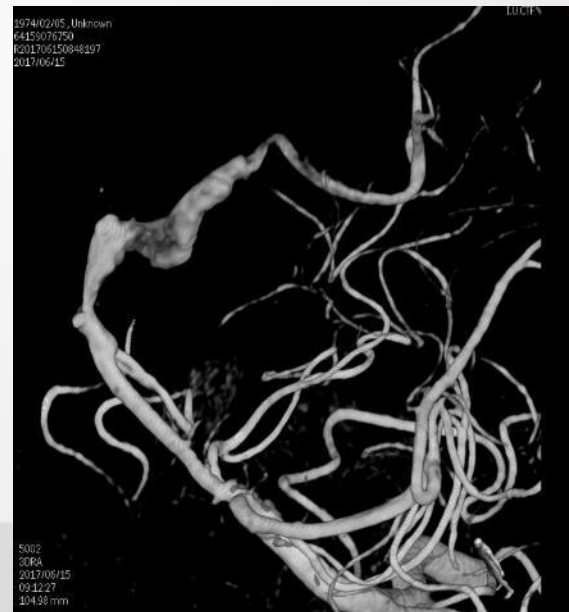
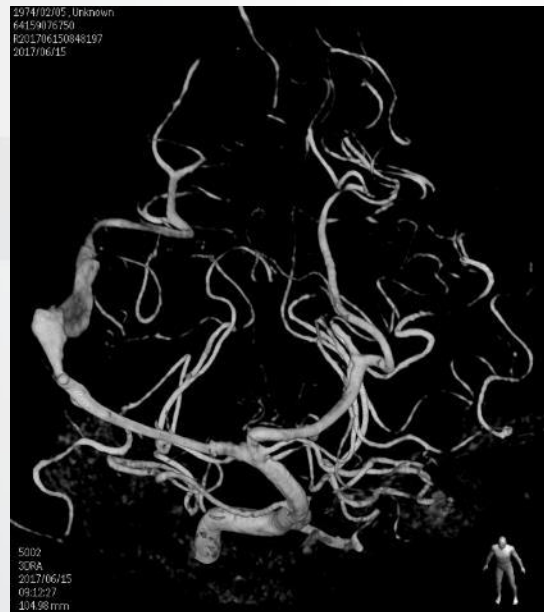
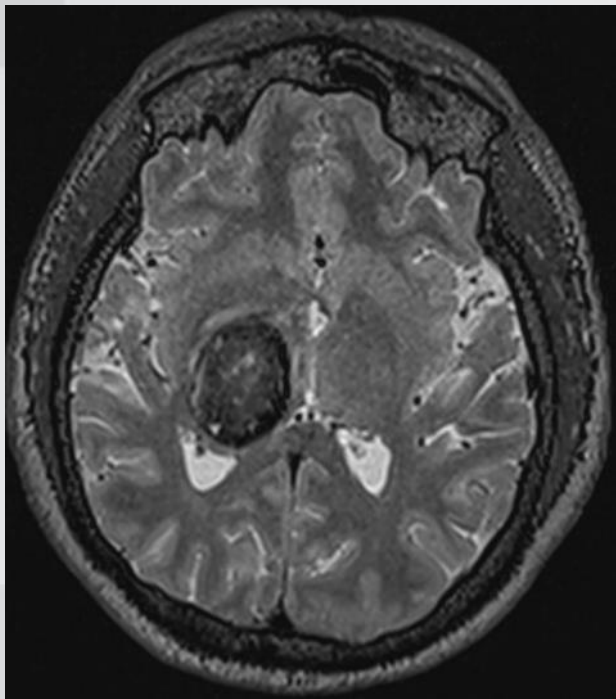
MRI 01.06.2017



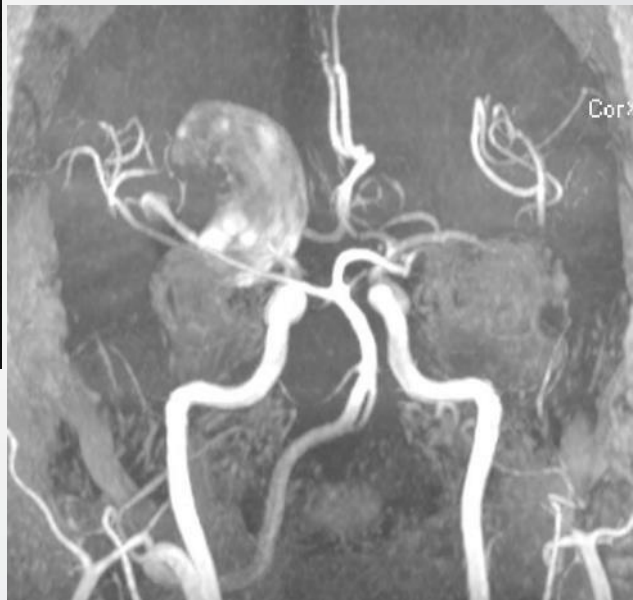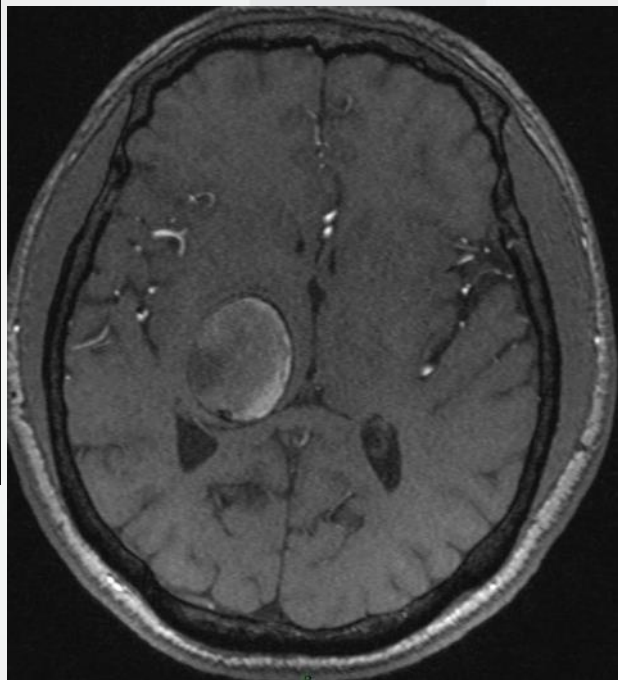


DSA 15.06.2017





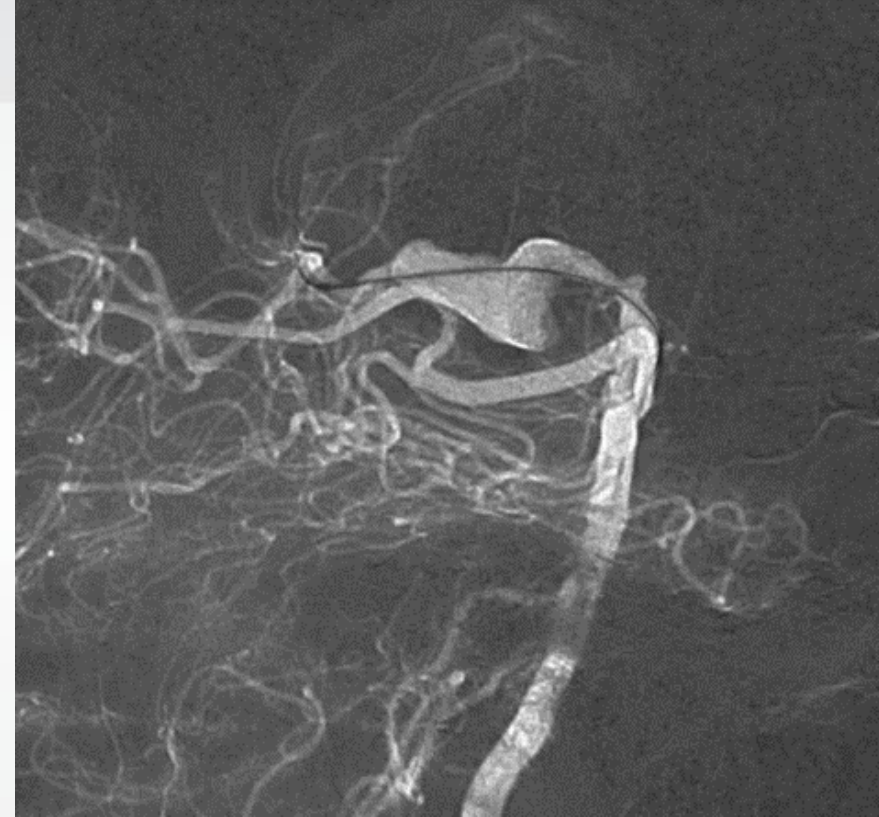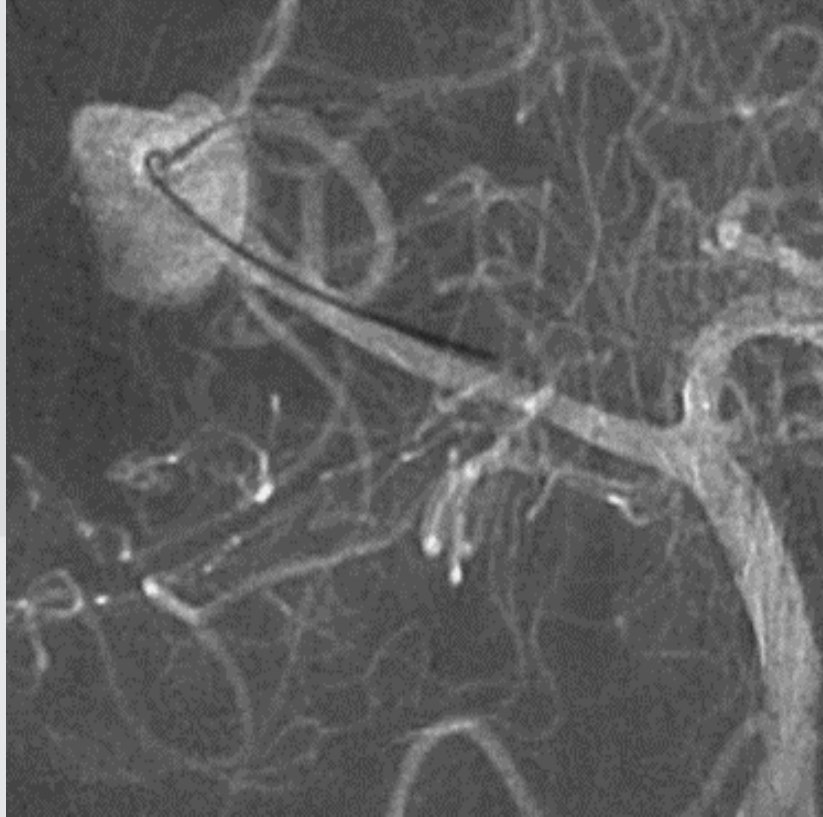MRA 04.04.2018



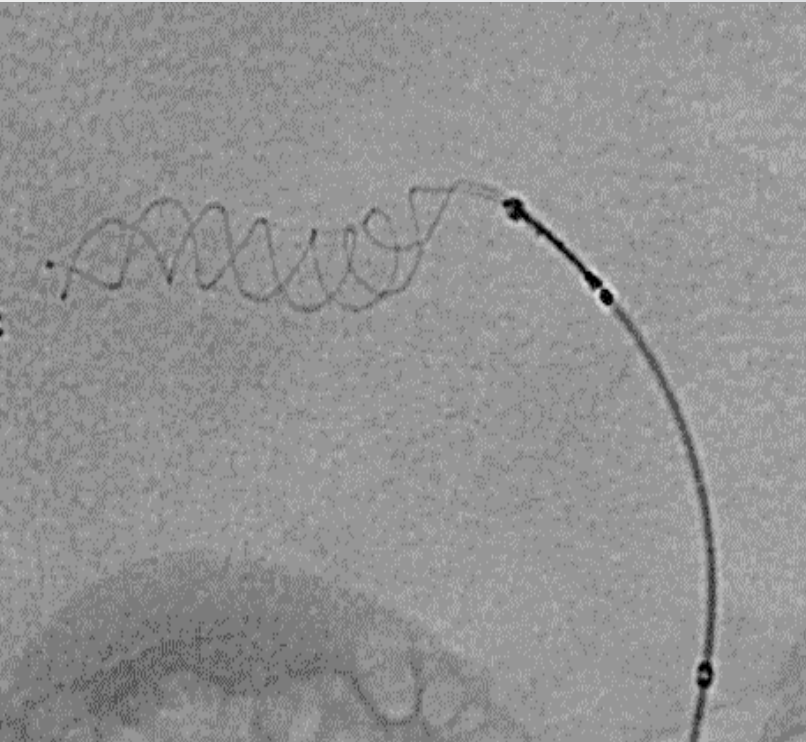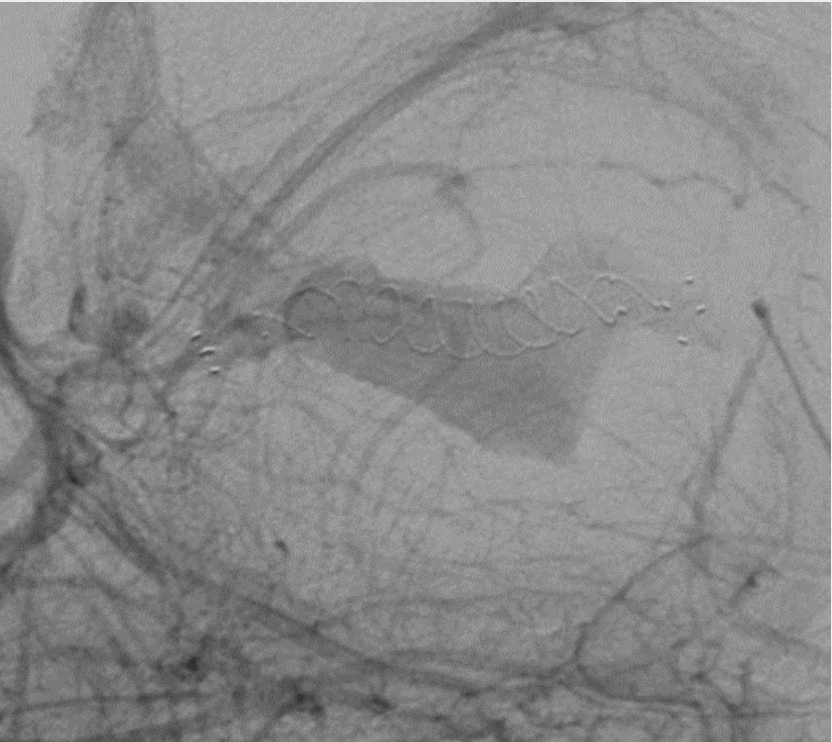
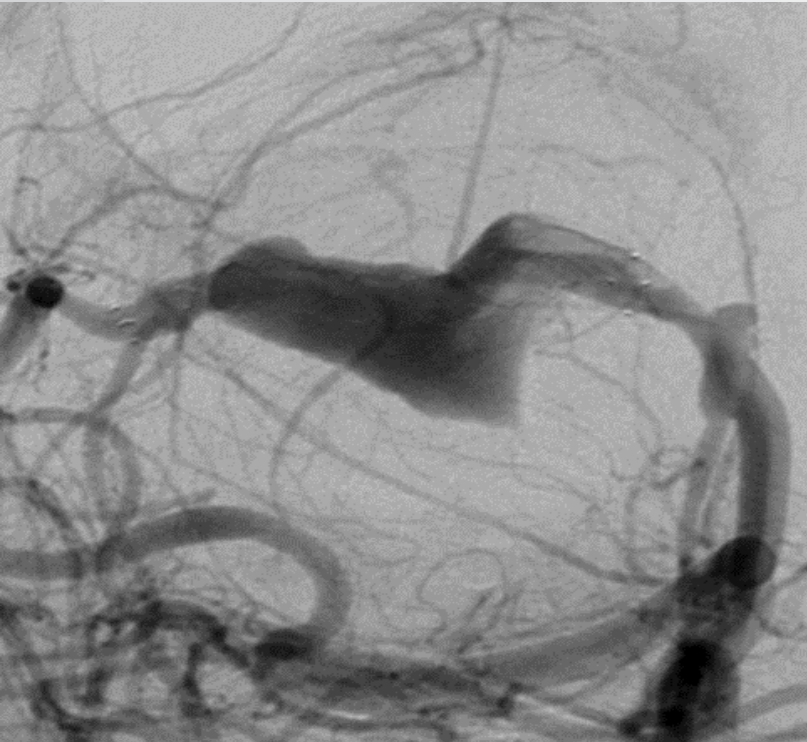
TREATMENT PLAN

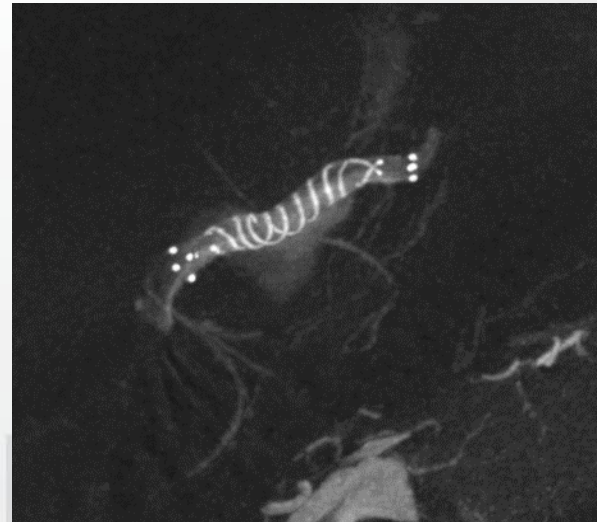
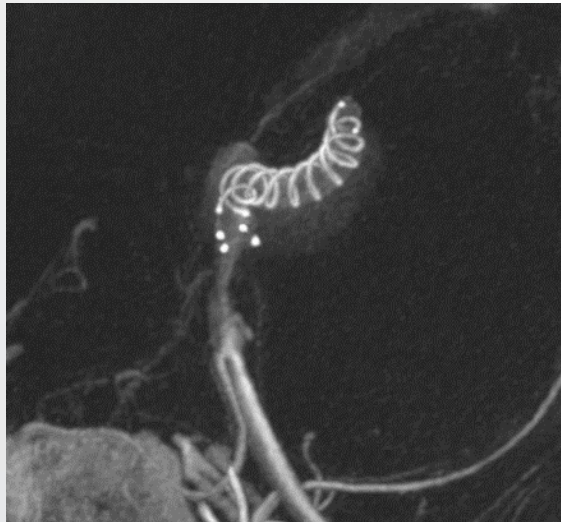
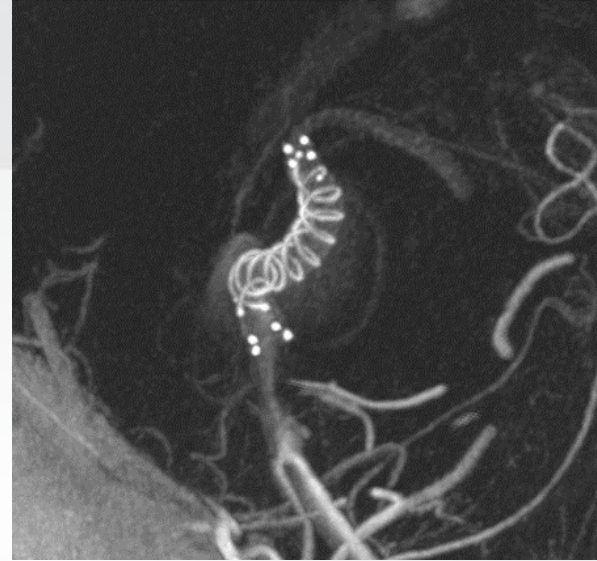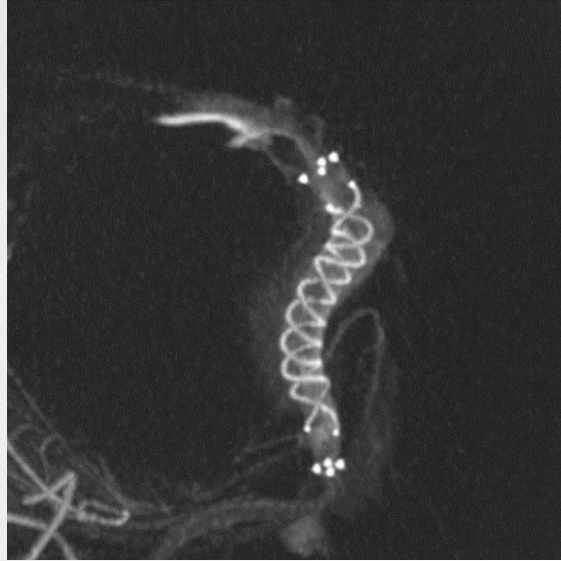- Flow diverter stent

TREATMENT

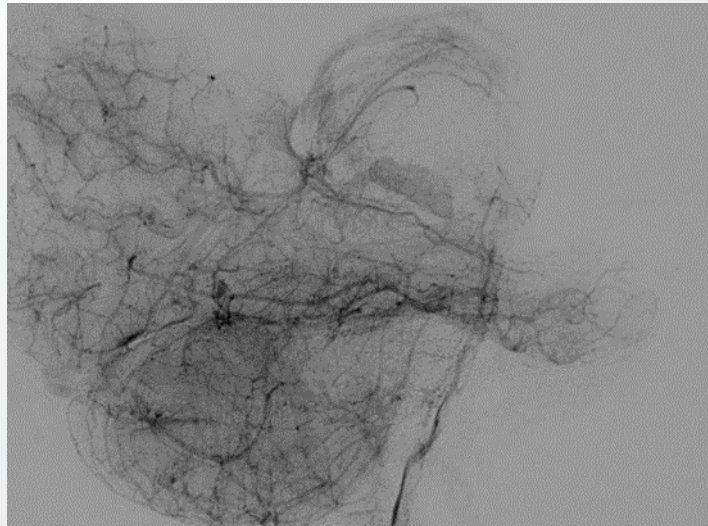
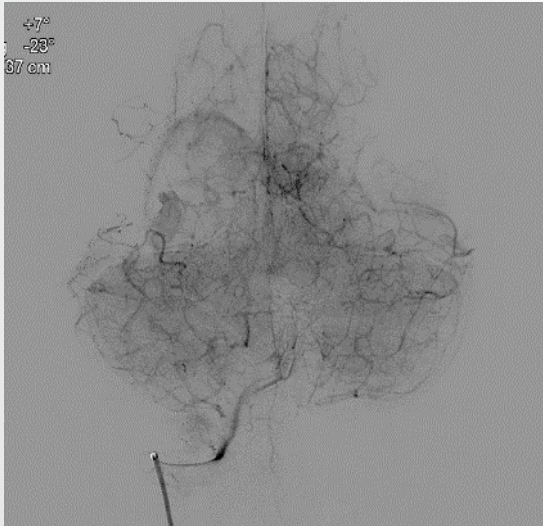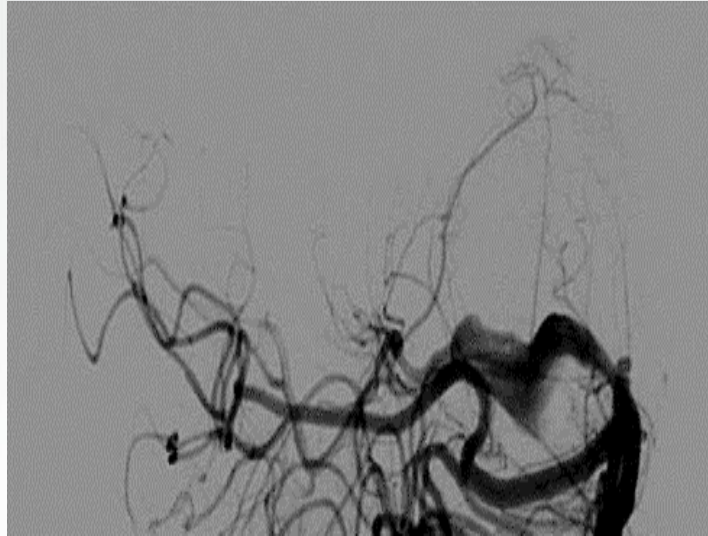
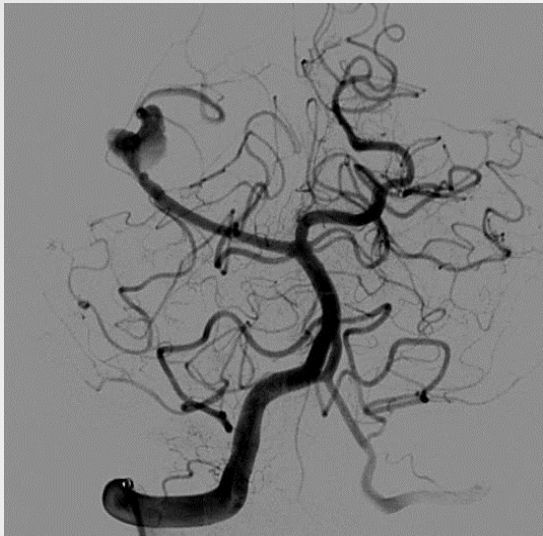


Size of the aneurysm : 16x7 mm
FD stent: FRED Jr. 3/32/27 mm



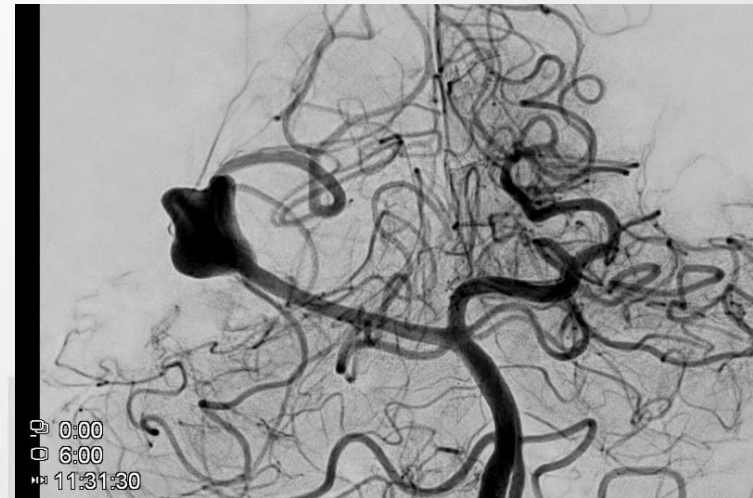
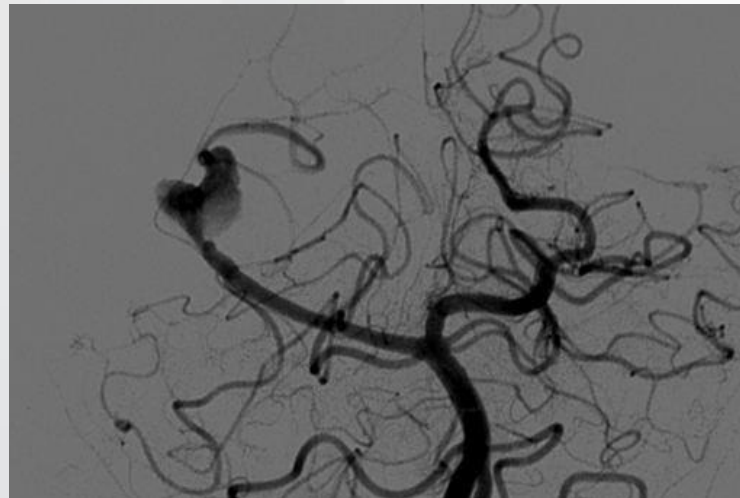
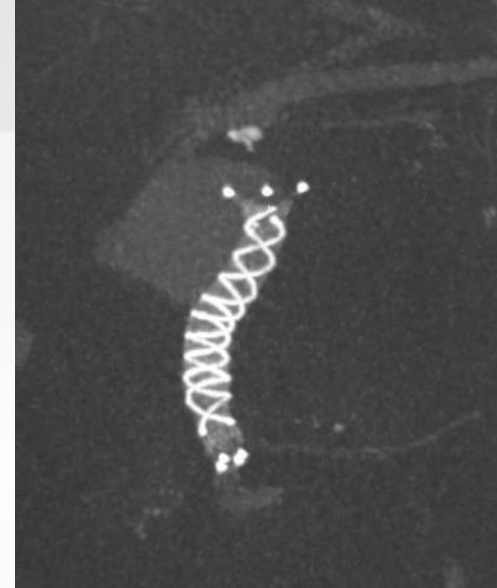
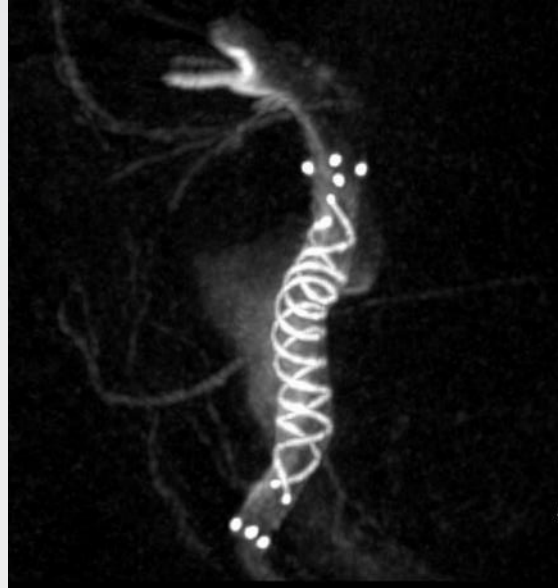


POST TREATMENT



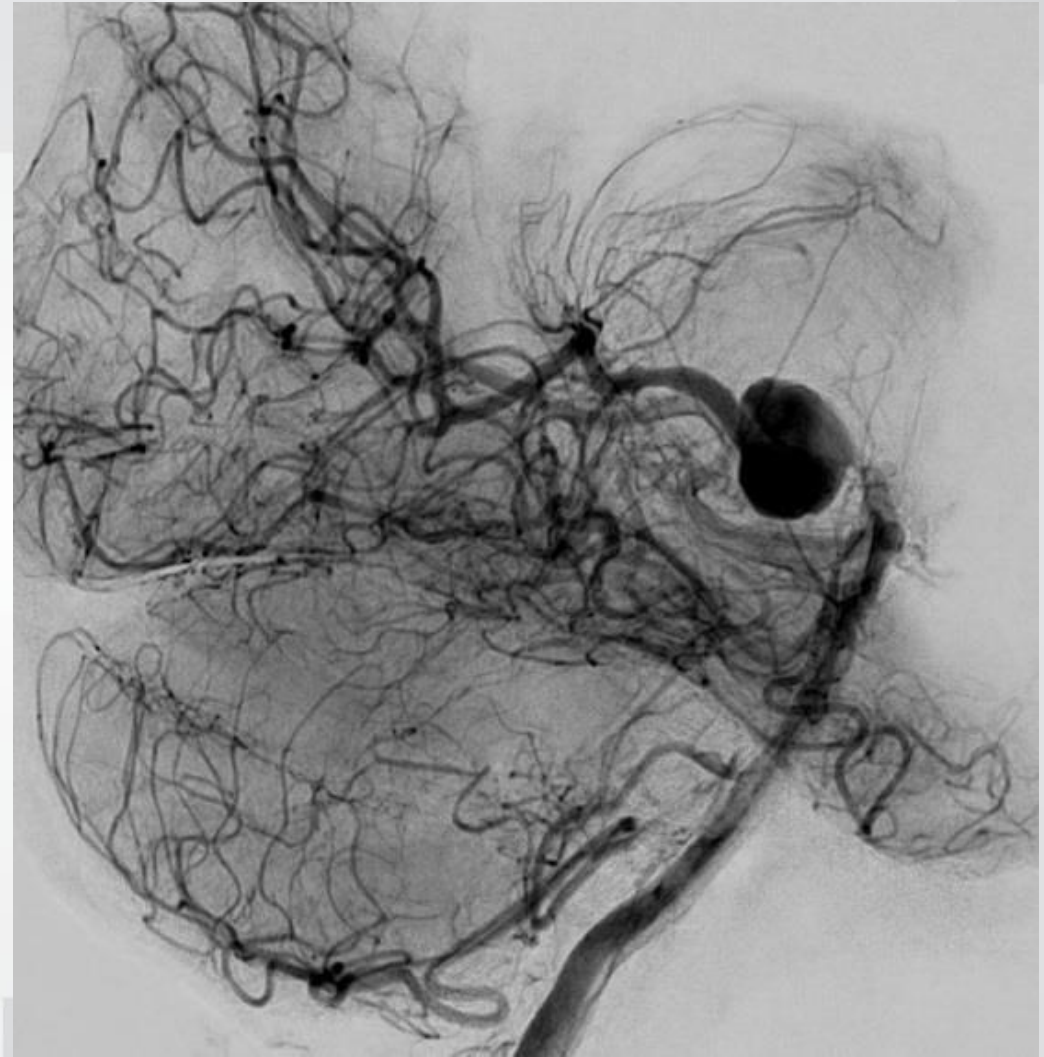
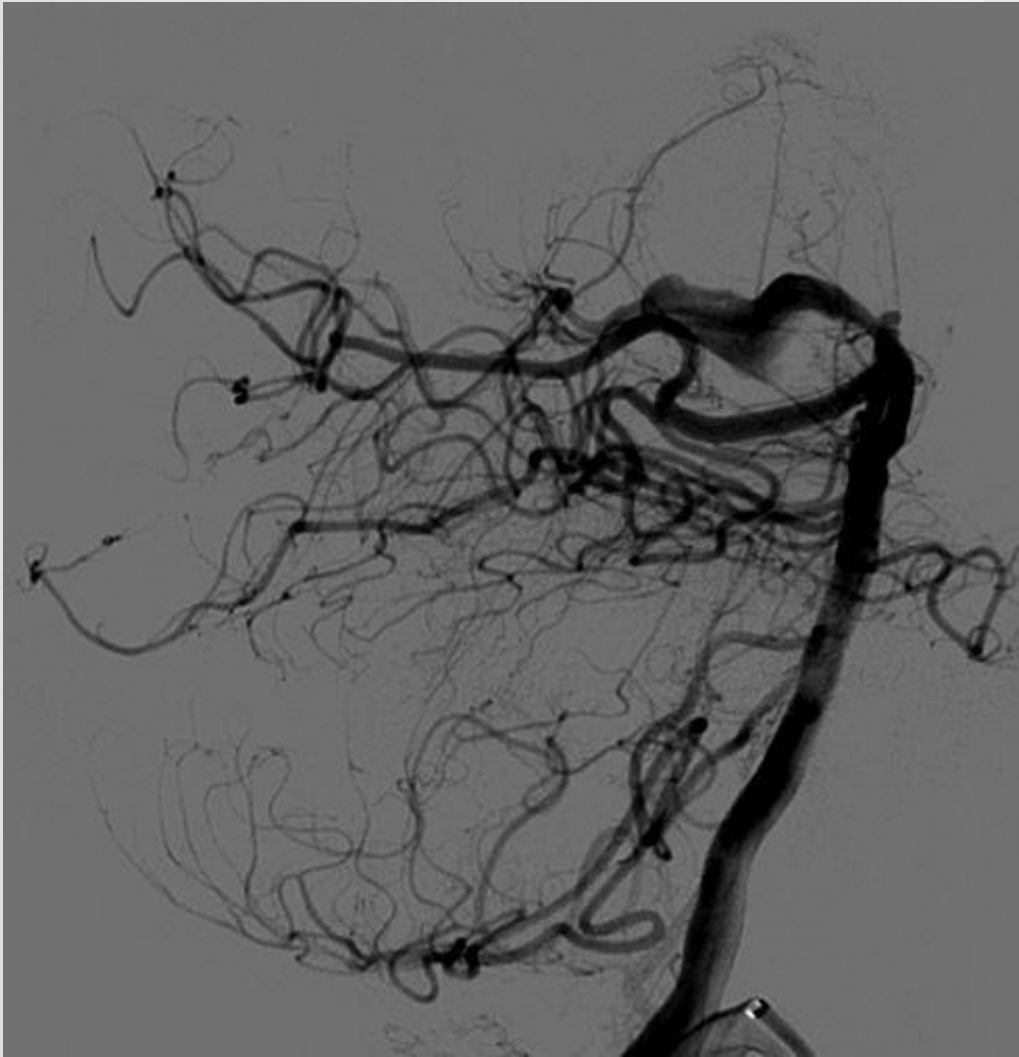
FOLLOW UP

06.07.2018



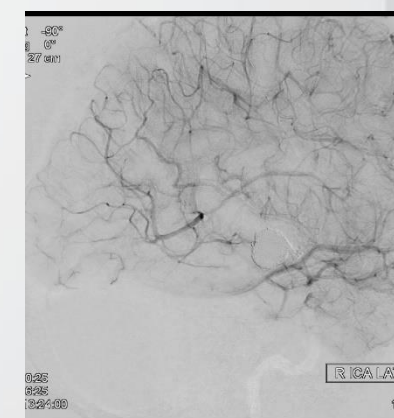
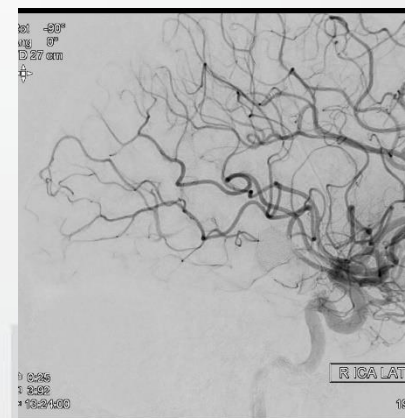
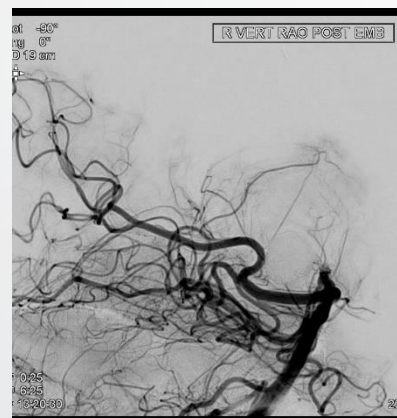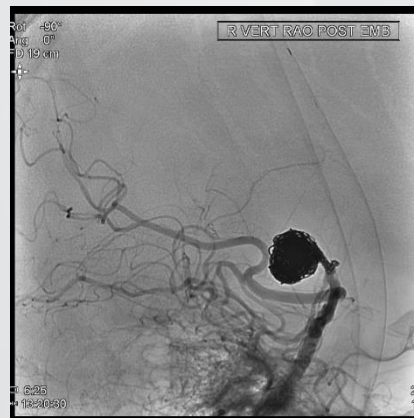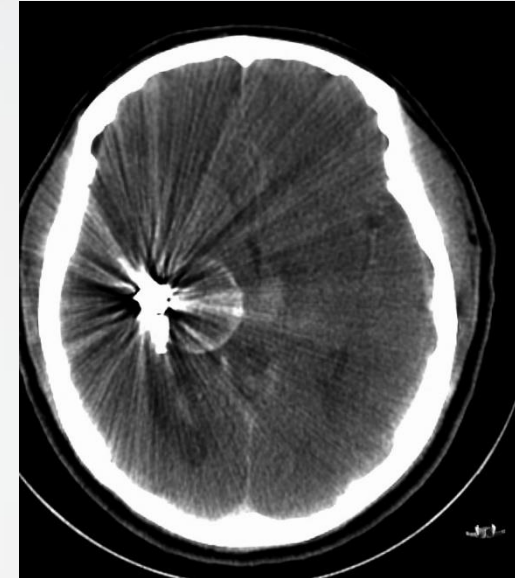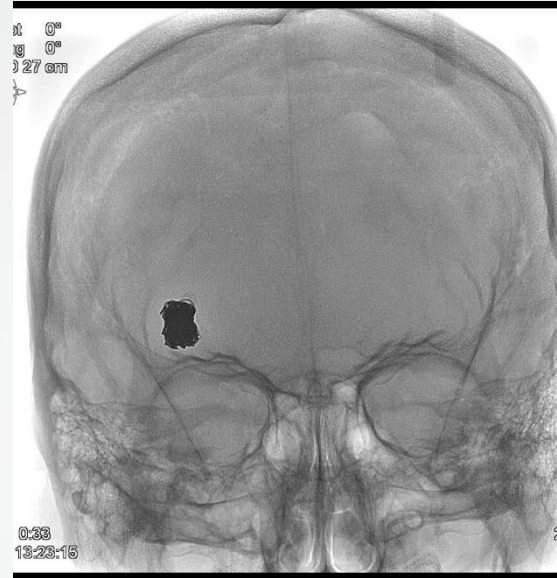
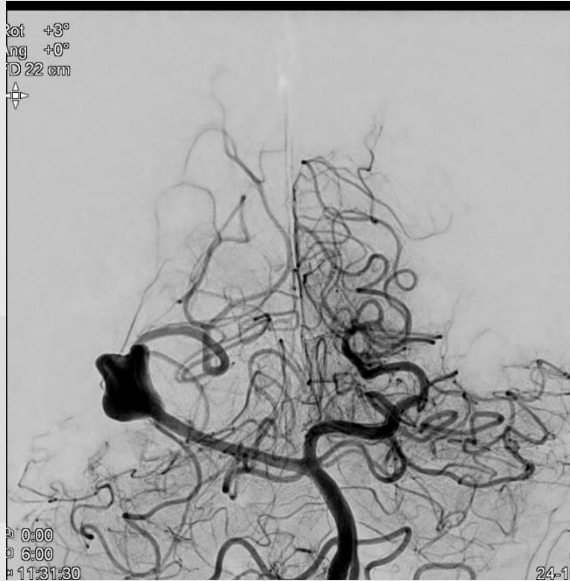FOLLOW UP

06.07.2018



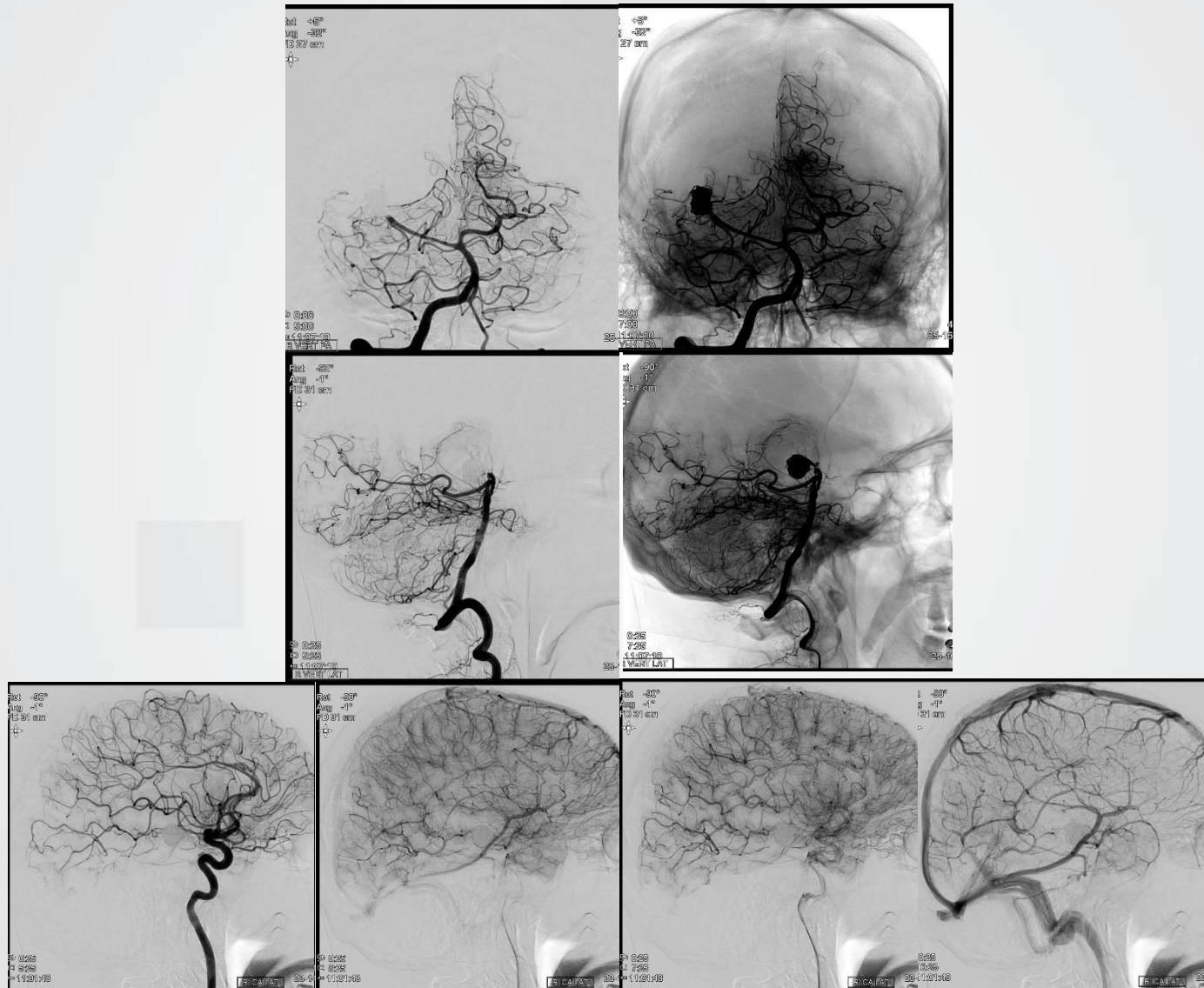
FOLLOW UP

7-2018



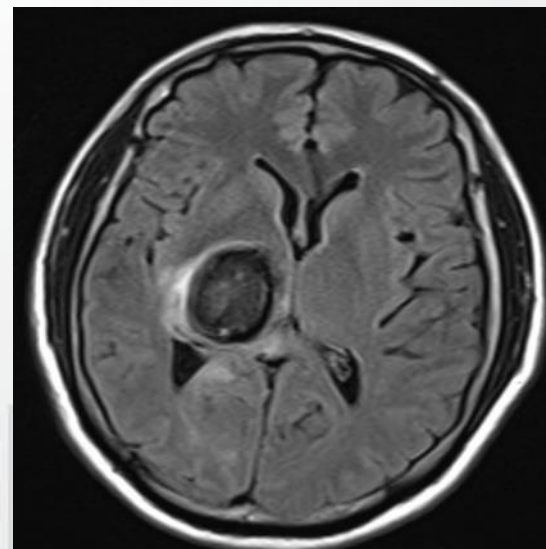
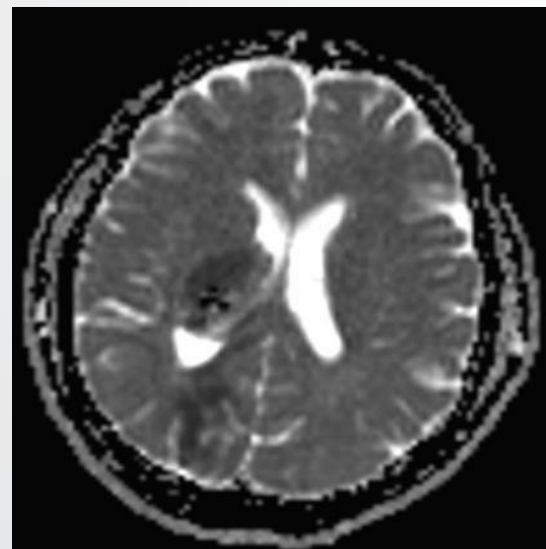
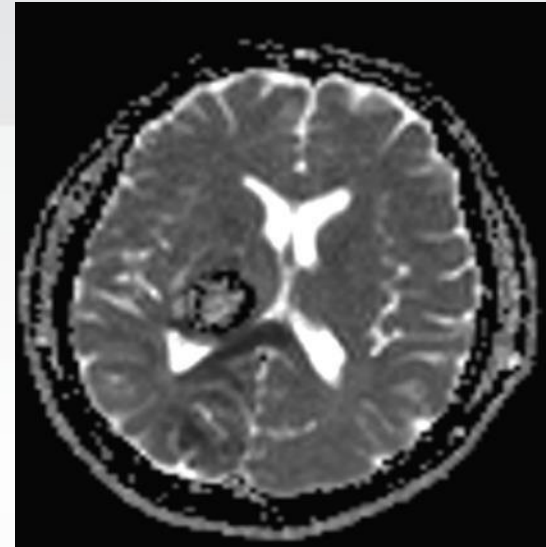
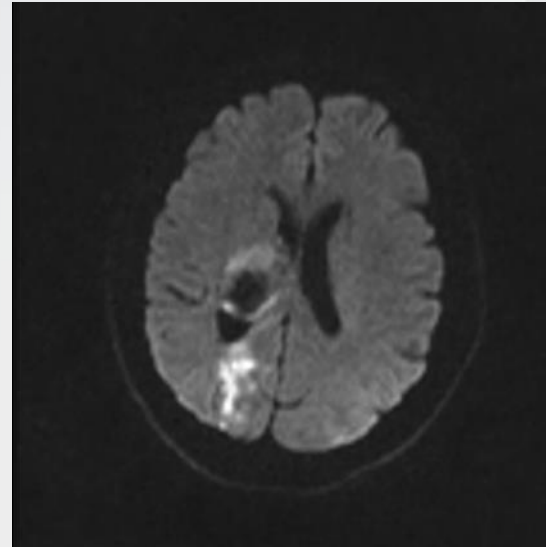
FOLLOW UP

7-2018



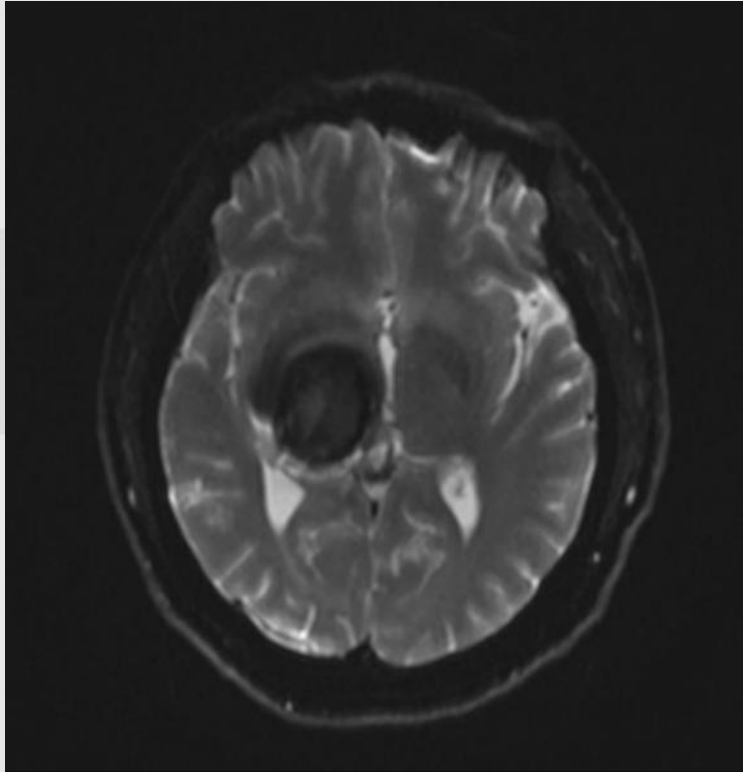
FOLLOW UP

25.07.2018

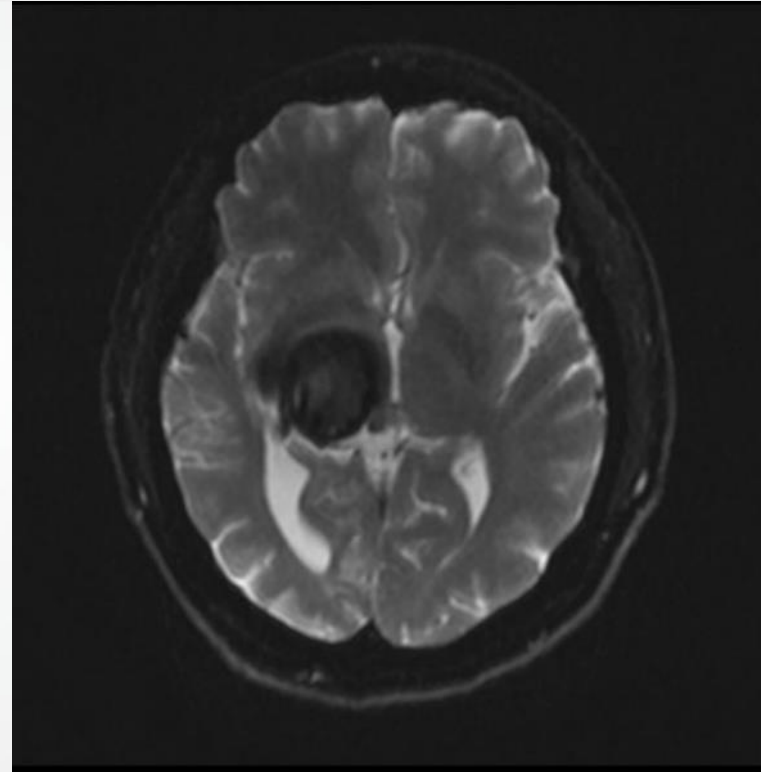


FOLLOW UP

09.08.2018

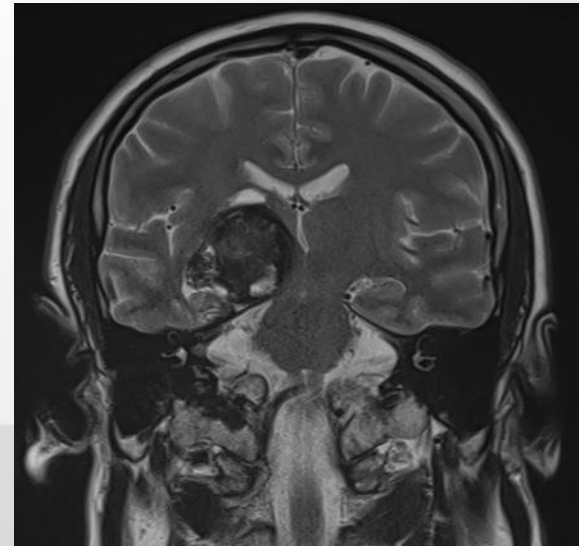
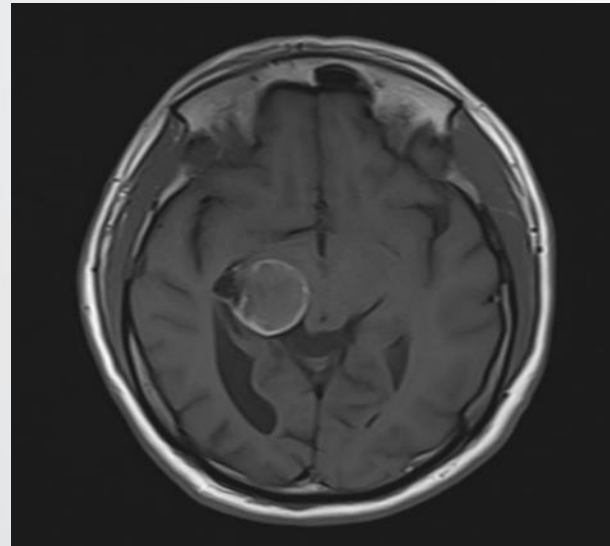
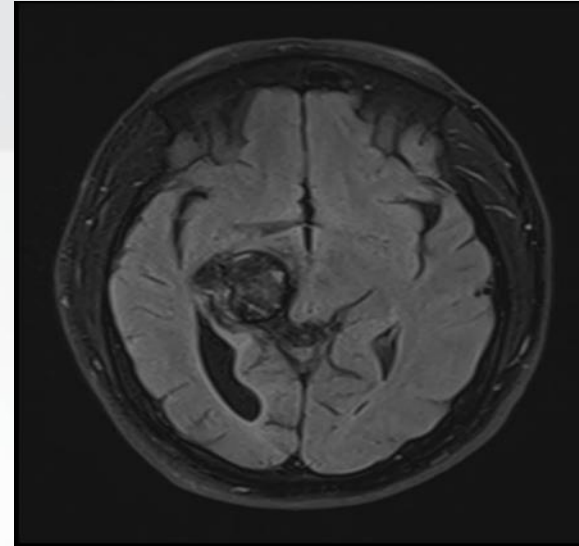
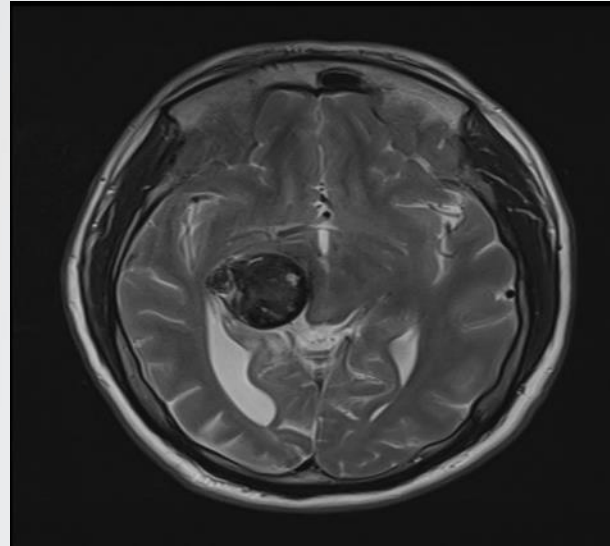


10.09.2018



FOLLOW UP

12.12.2018:MR

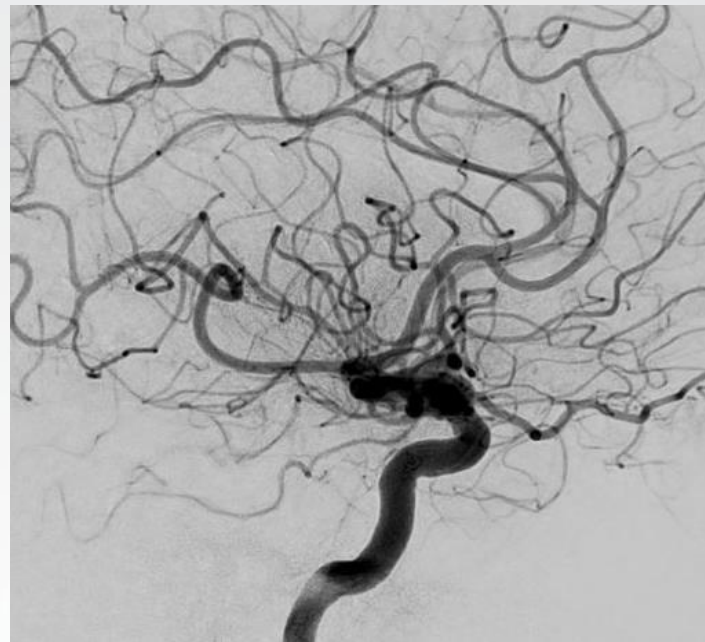
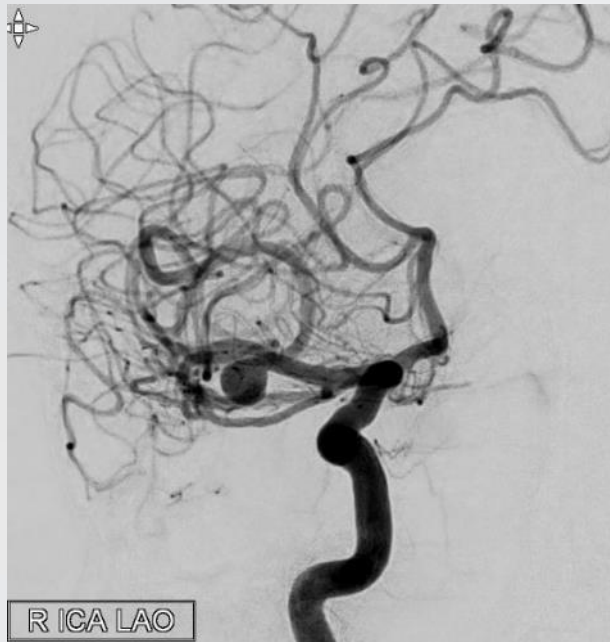

PATIENT 7 FD

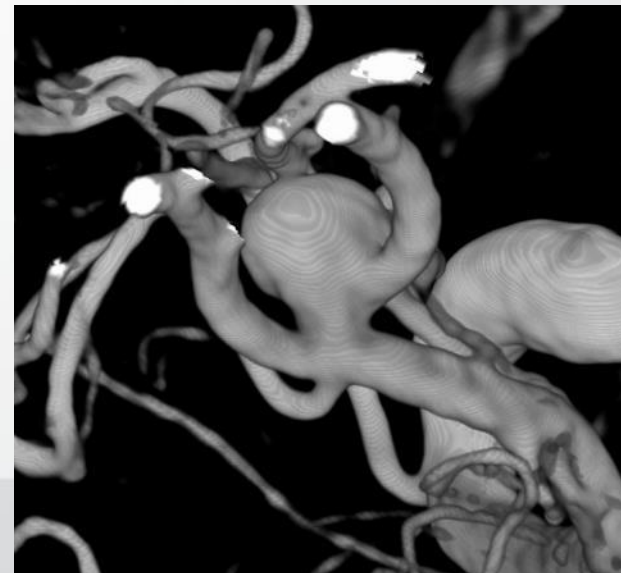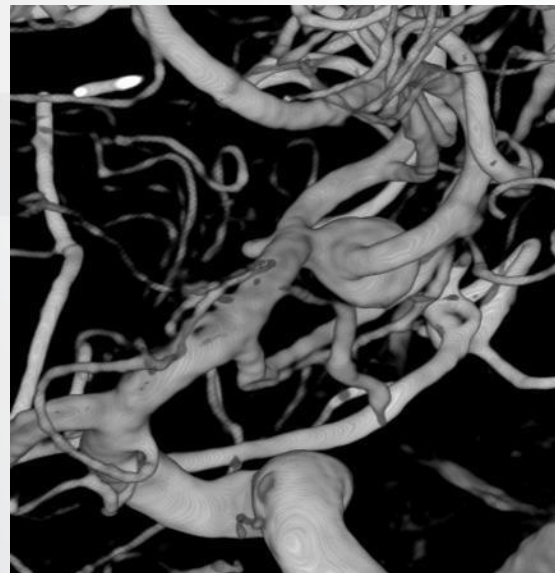- 50 Y M
- Presented by headache 2 years ago
- MRA-DSA:

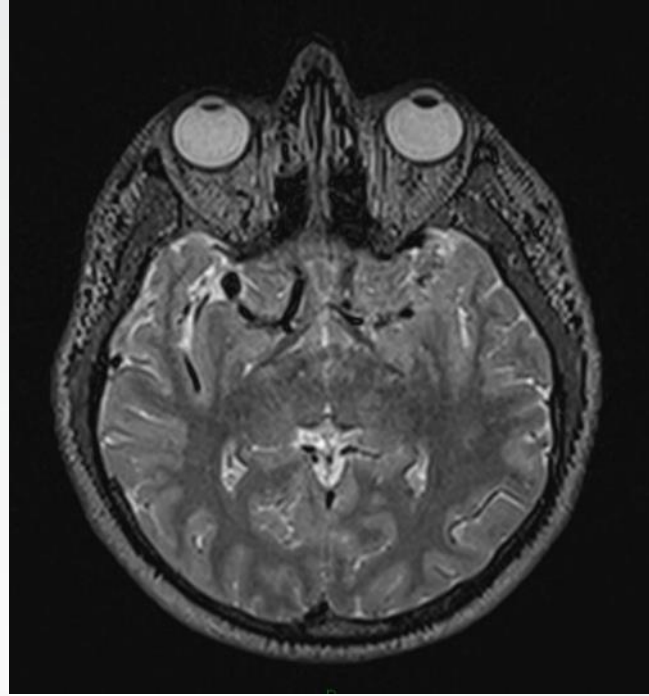
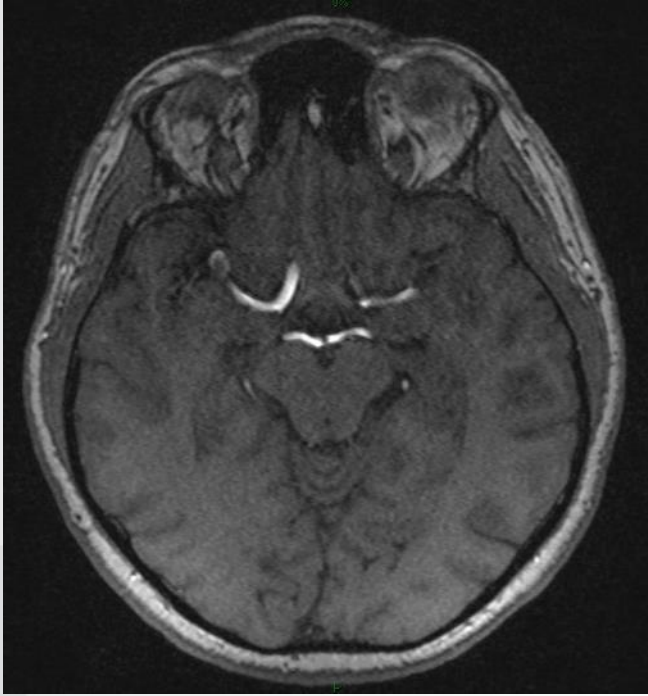
**R MCA aneurysm
(unruptured)**



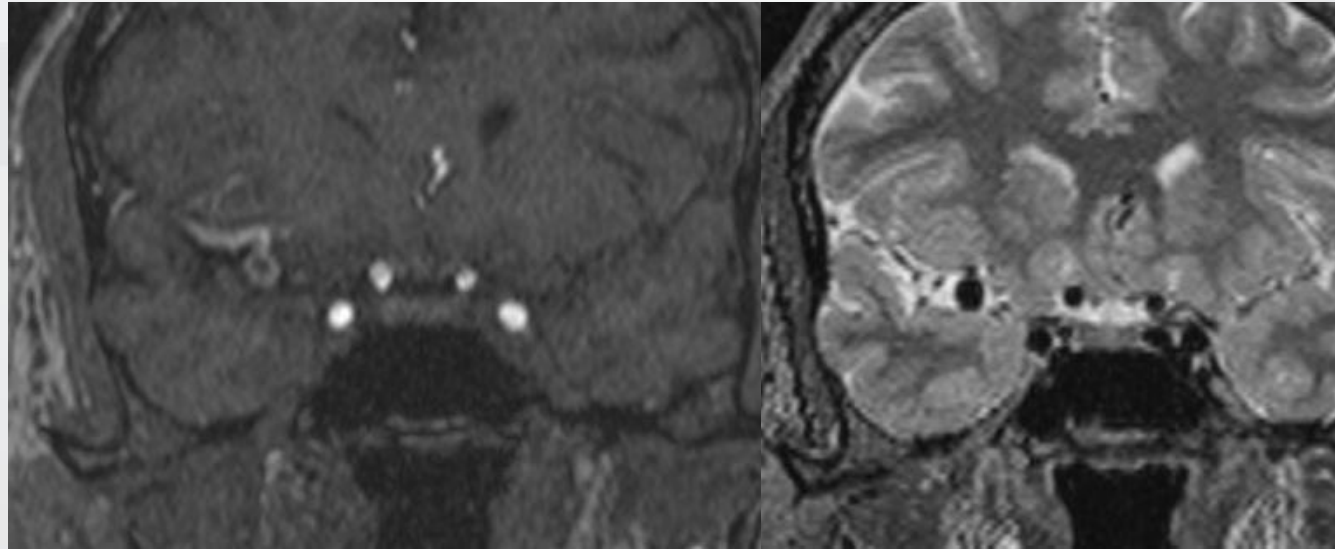


DSA 24.11.2016





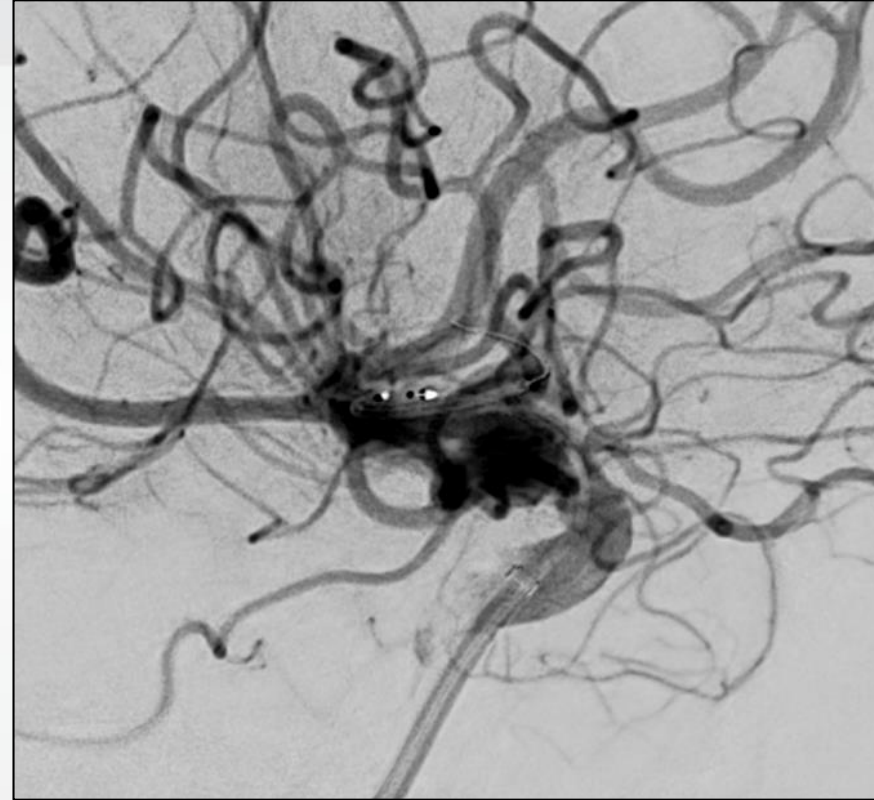
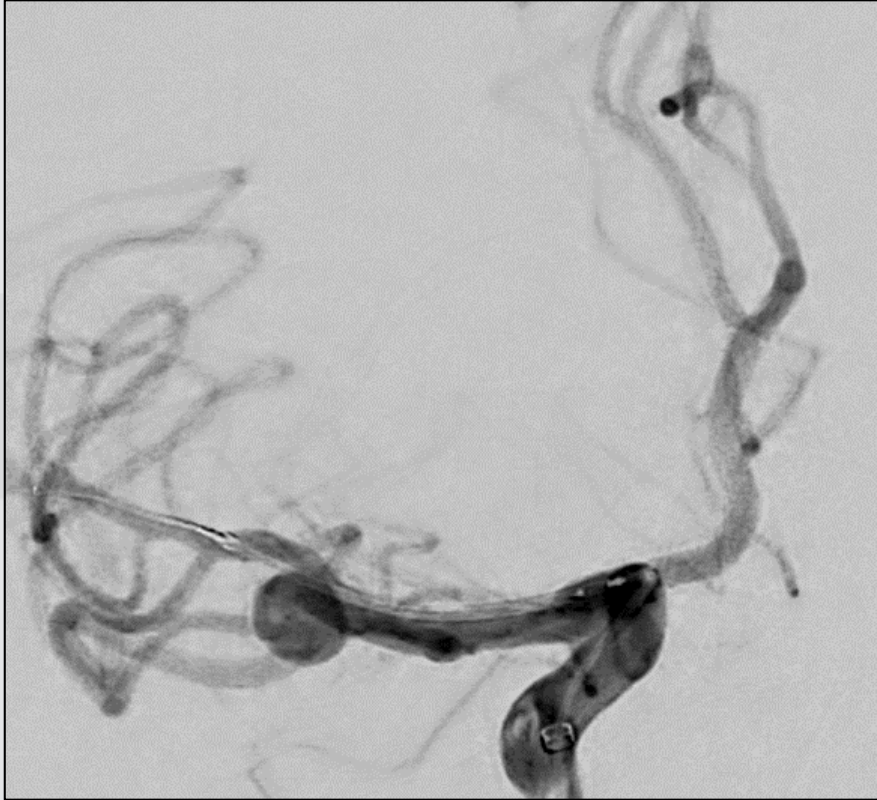
MRA 04.04.2018



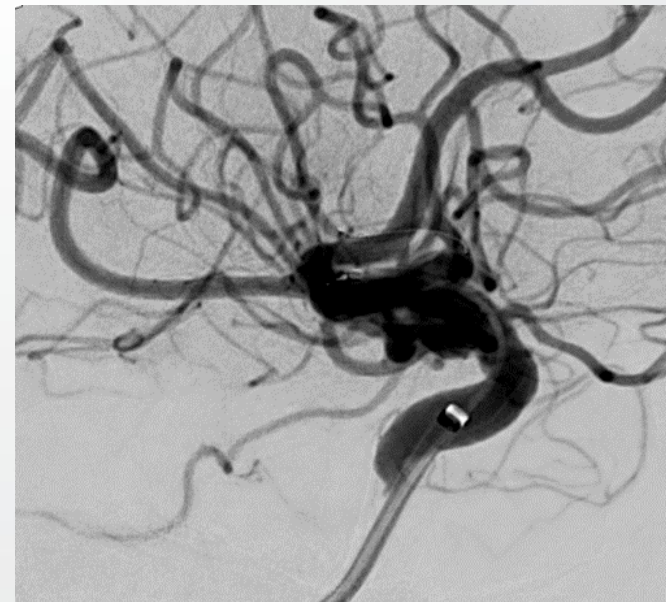
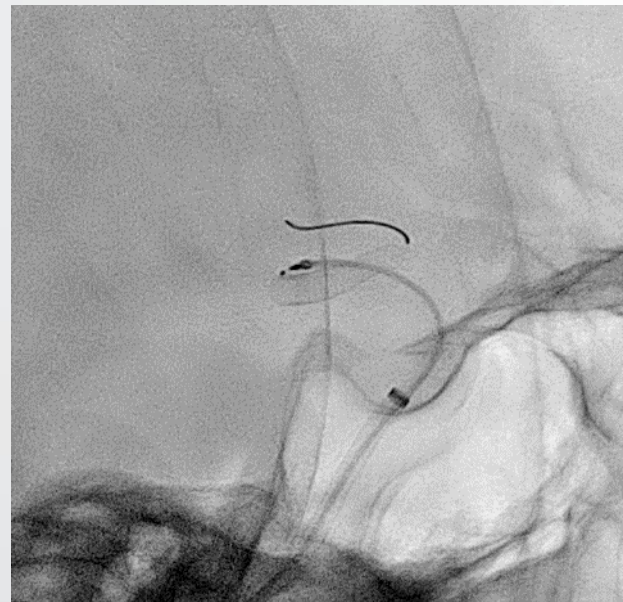
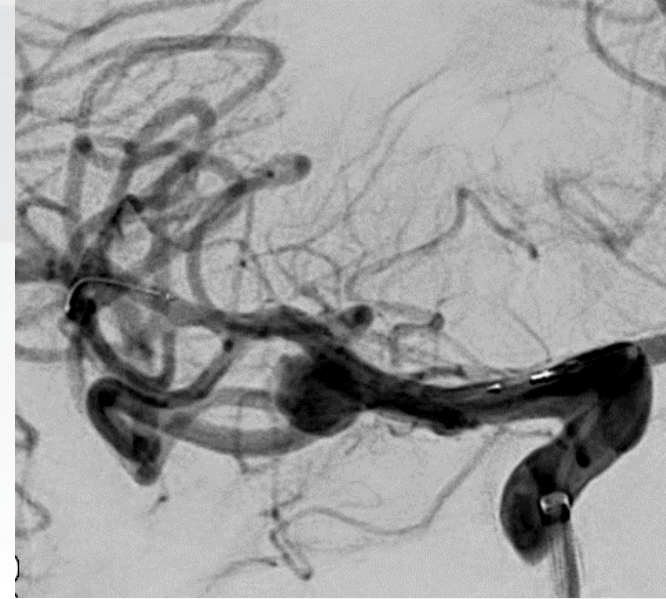
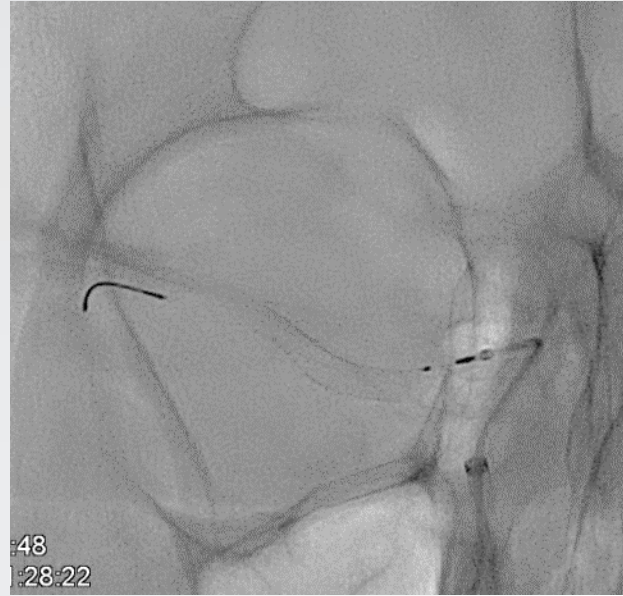
TREATMENT PLAN

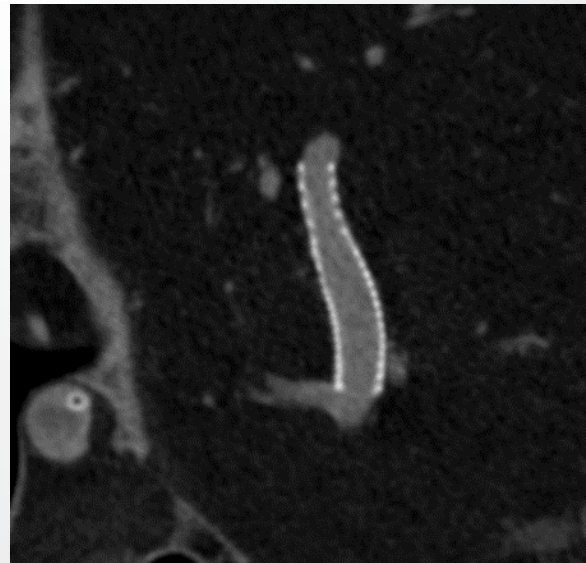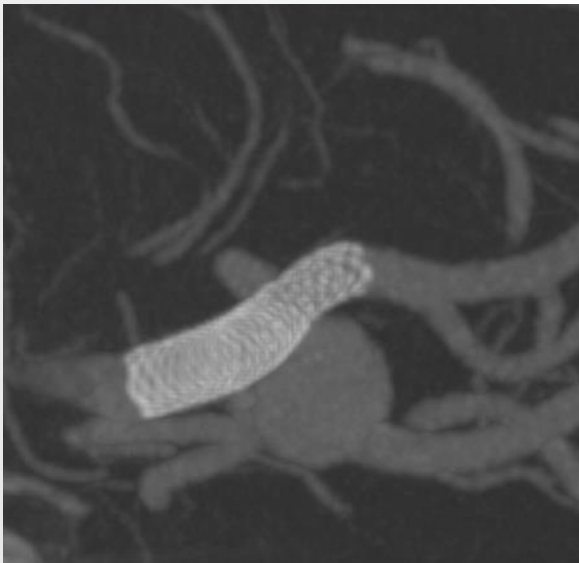
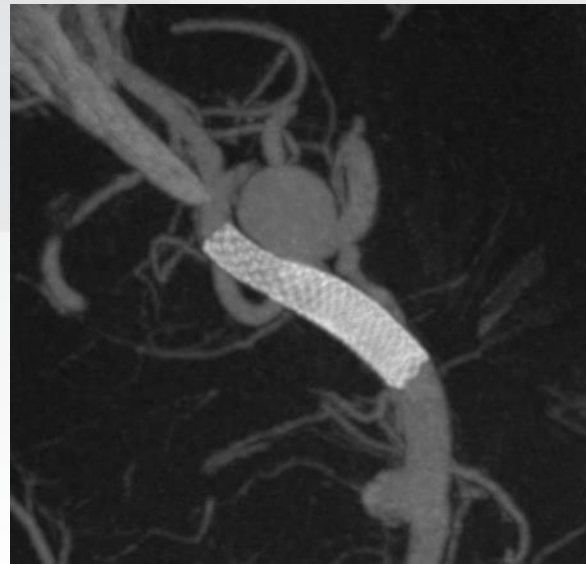
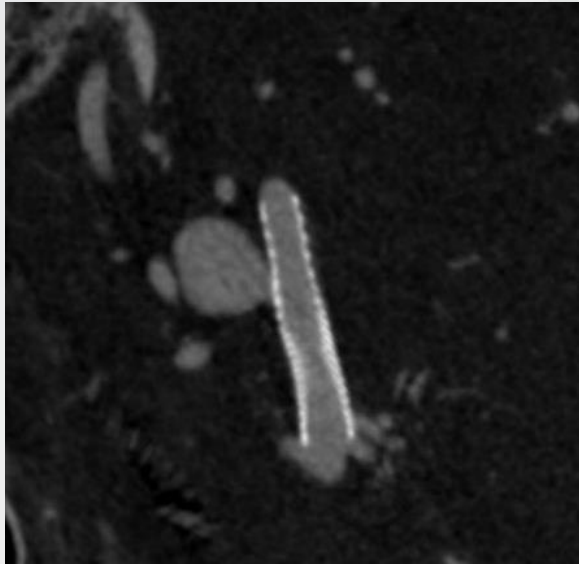
- Flow diverter stent

TREATMENT

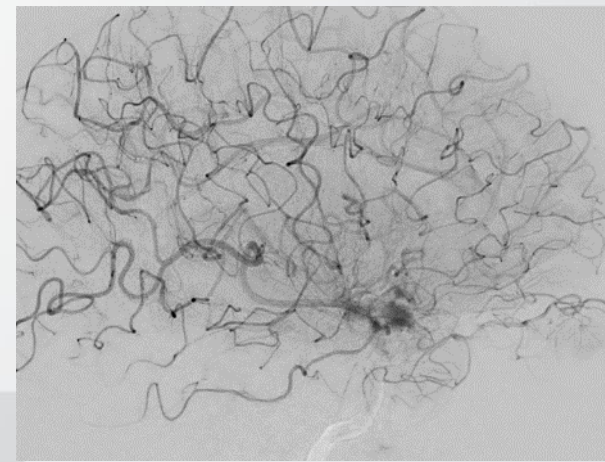
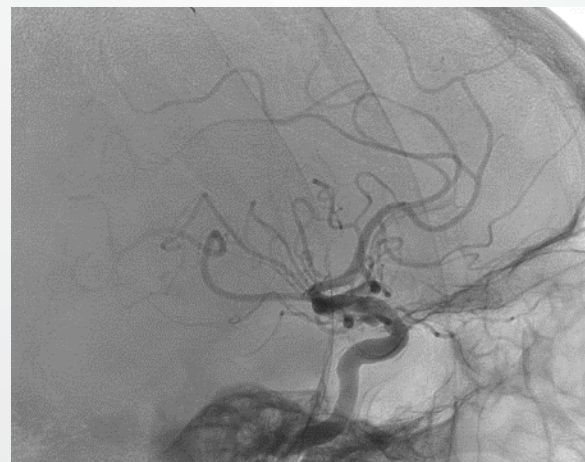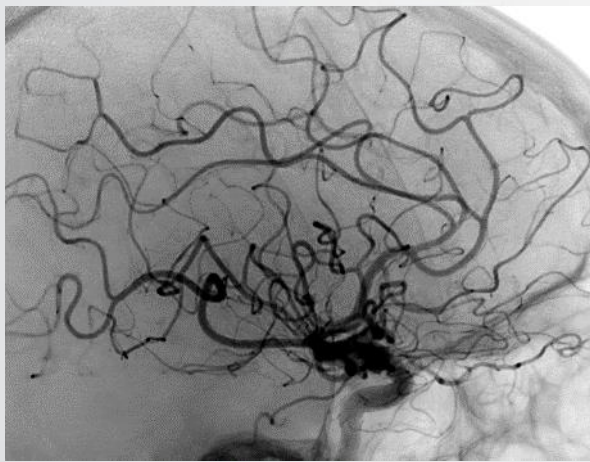
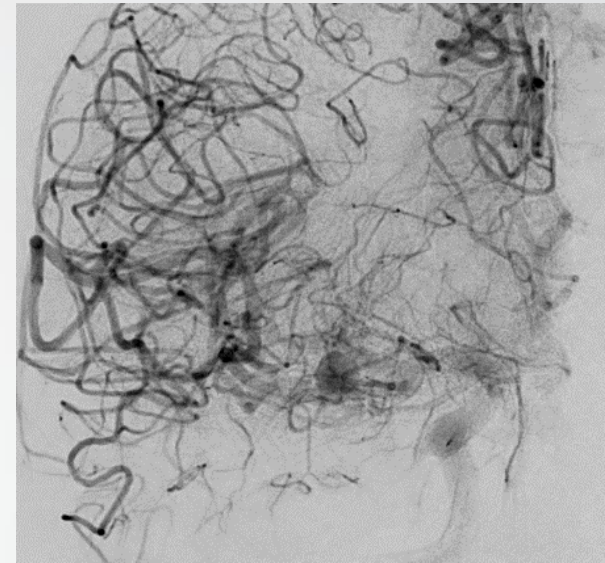
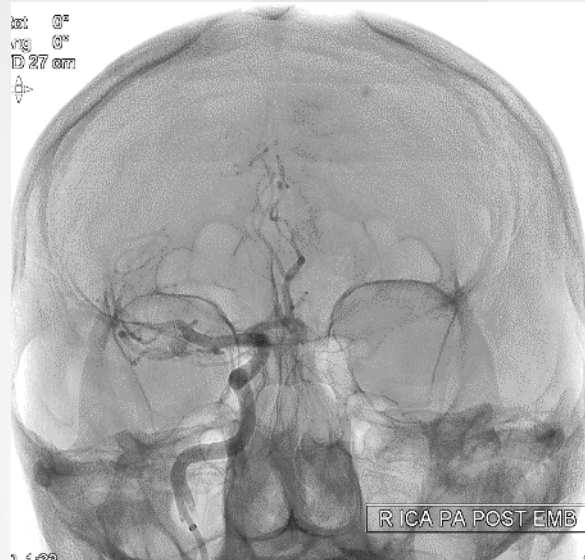
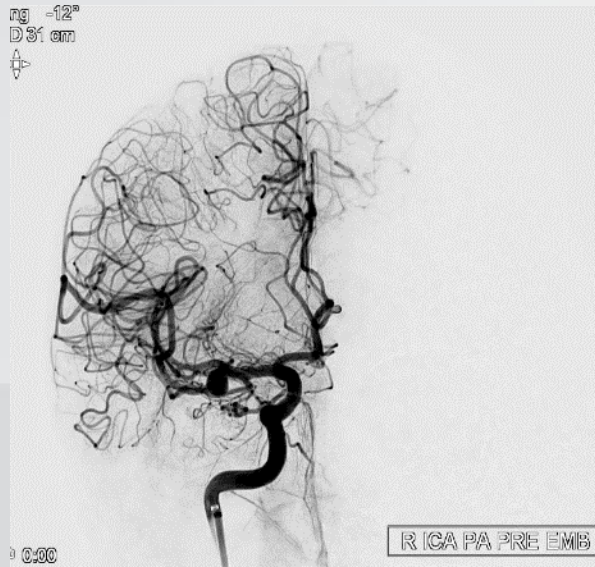


Size of the aneurysm : 7x6,5 mm
FD stent: Pipeline 3mm/14 mm





POST TREATMENT

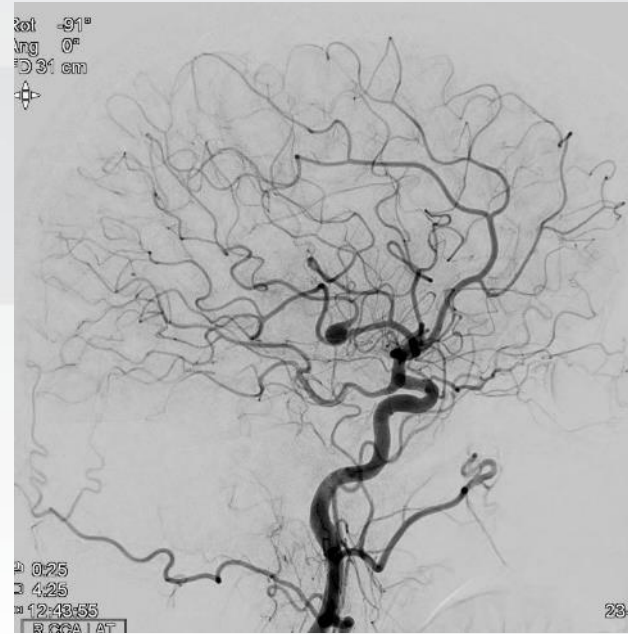
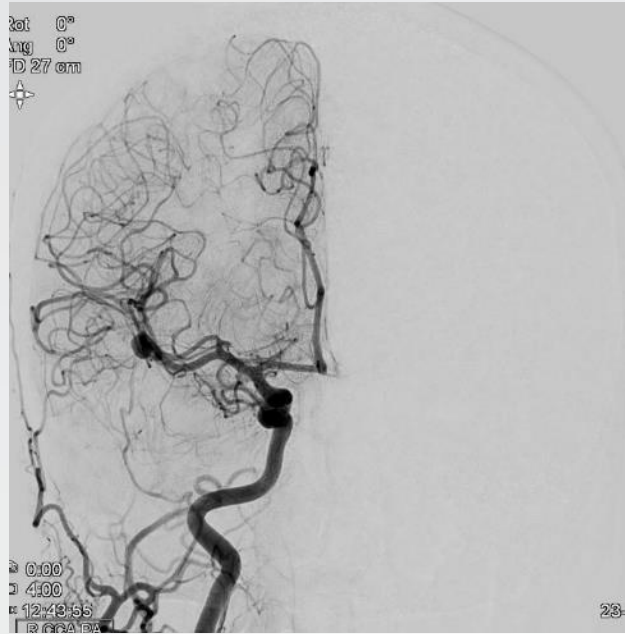

PATIENT 8 KK

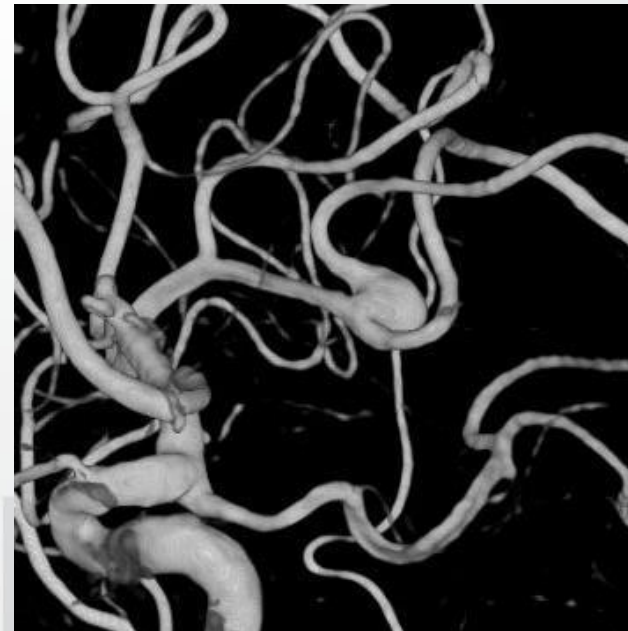
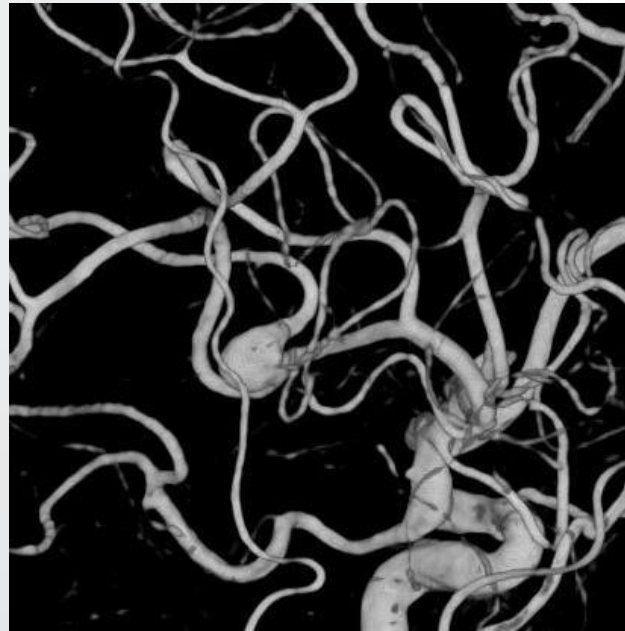
- 61 Y F
- Presented with headaches 3-years ago
- MRI & DSA:

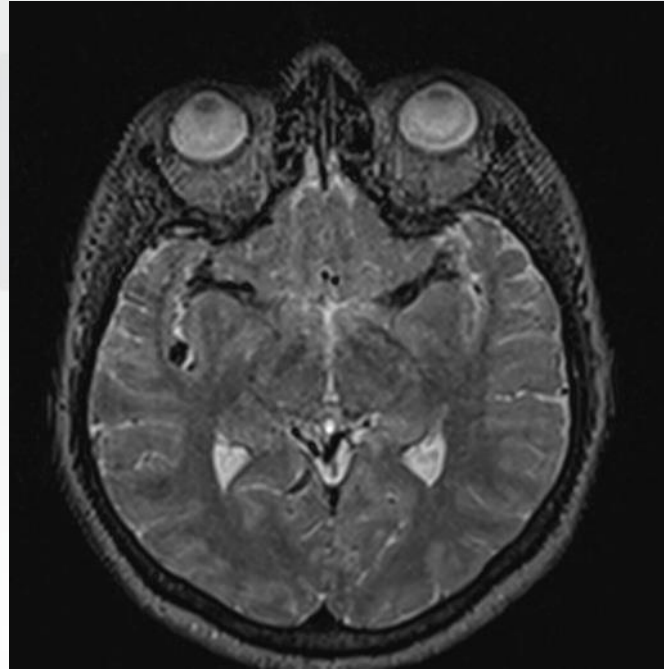
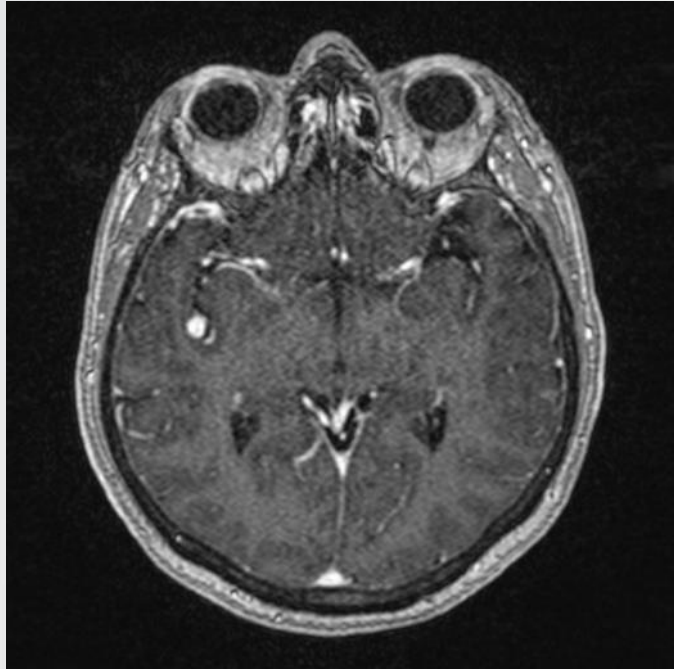
R MCA M2 segment aneurysm



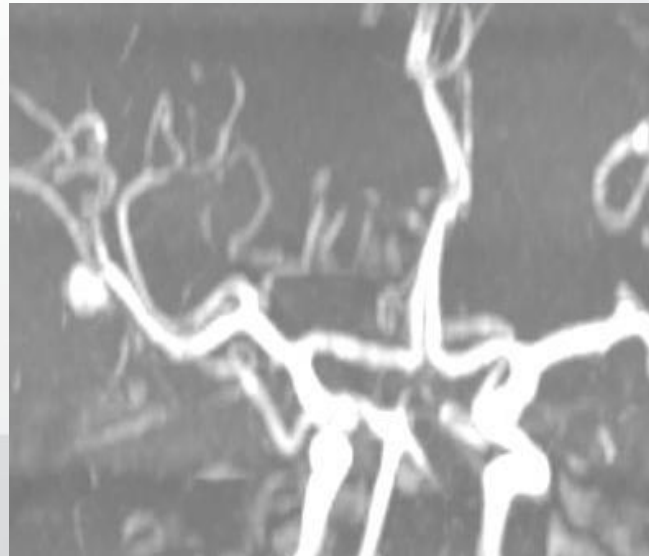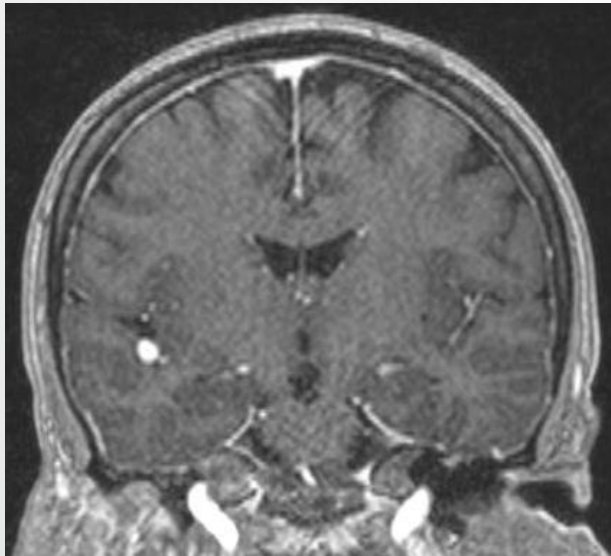


DSA 14.08.2017





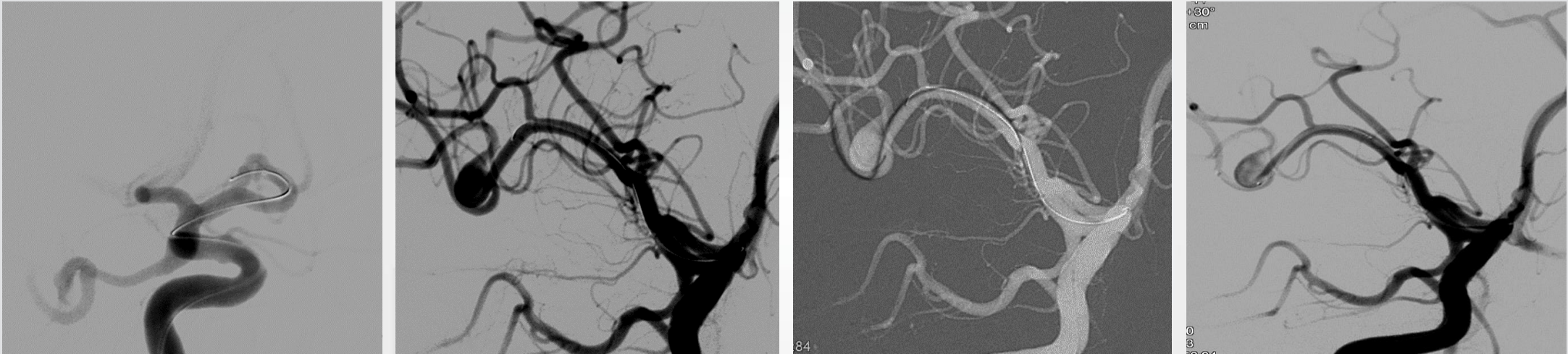MRI 04.04.2018



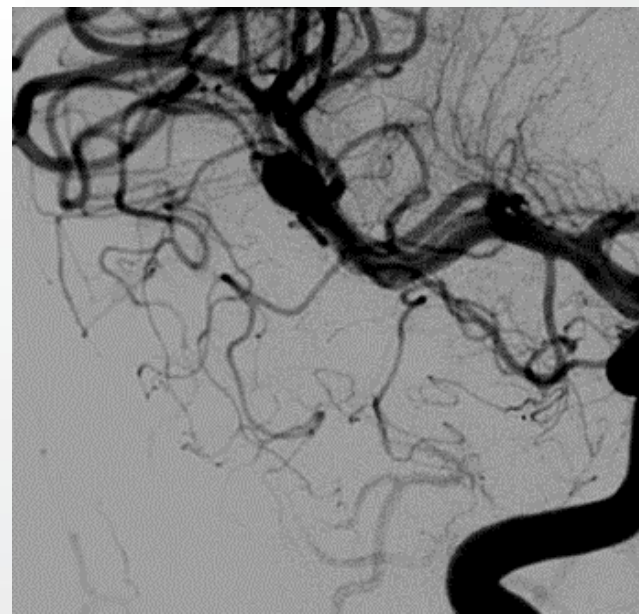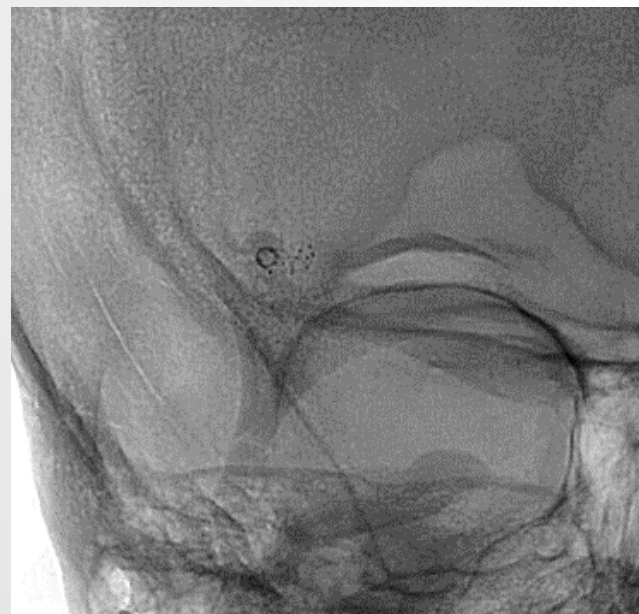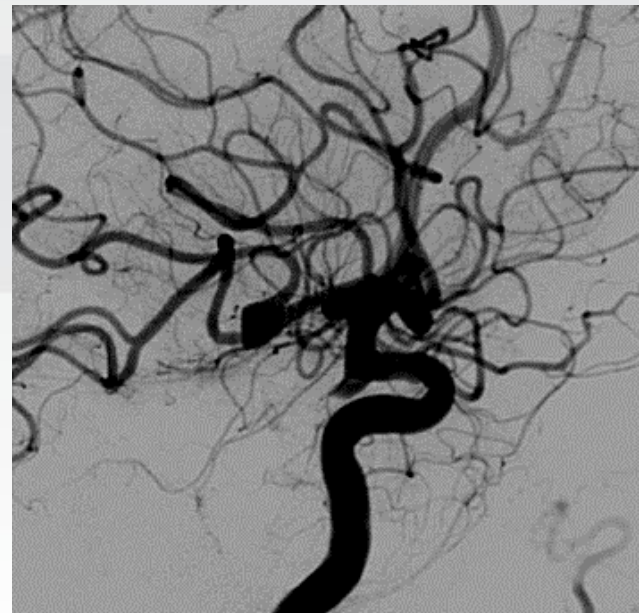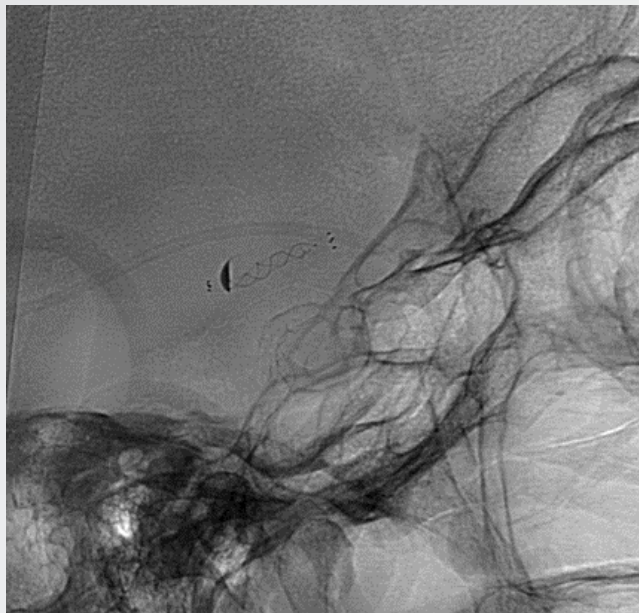
TREATMENT PLAN

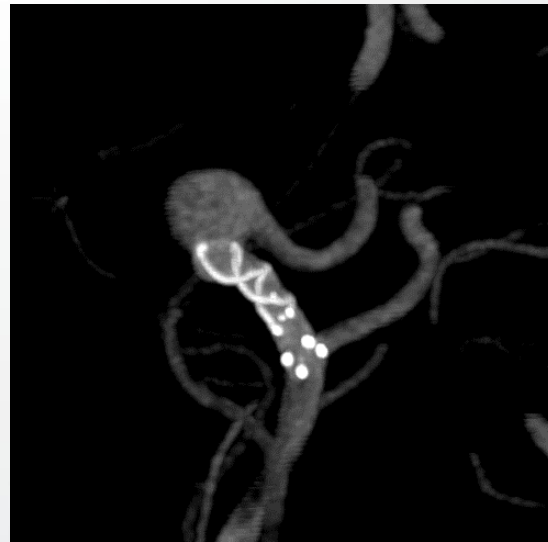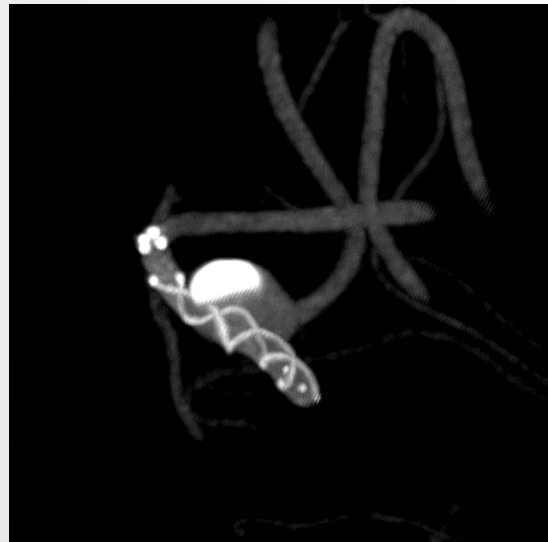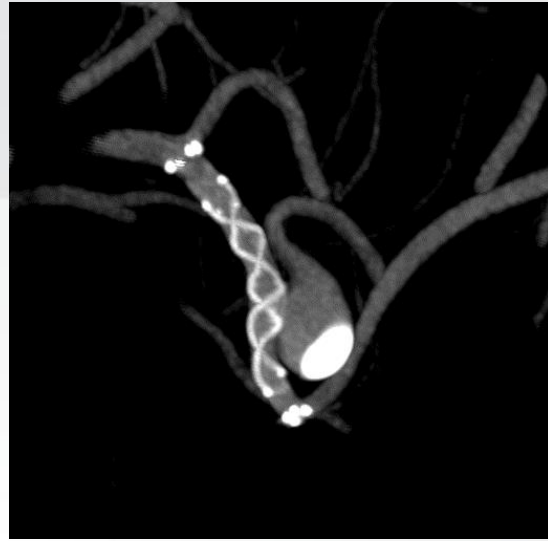
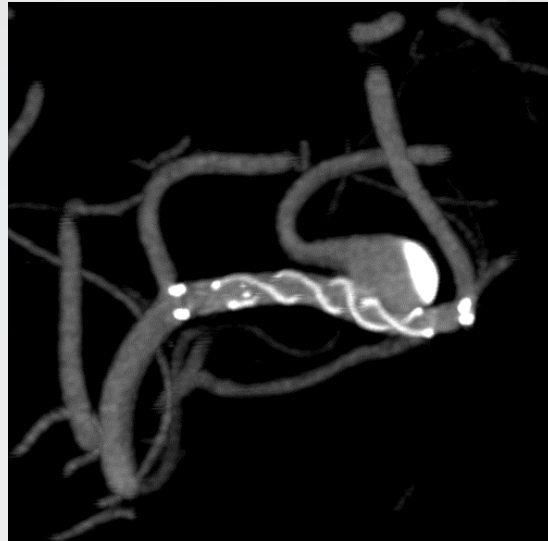
- Flow diverter stent

TREATMENT

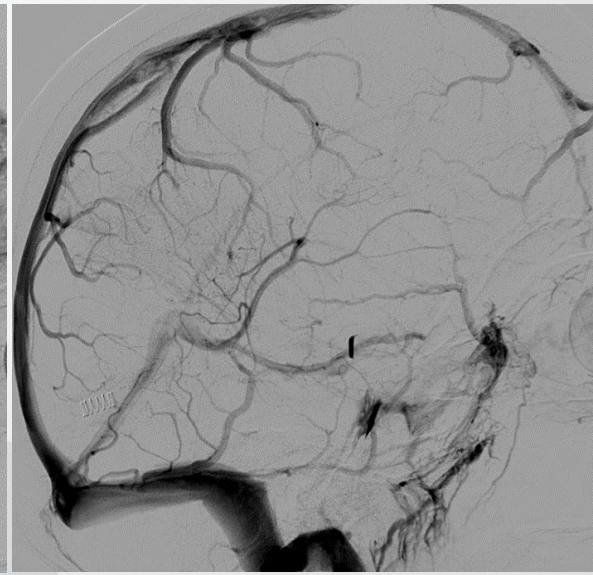
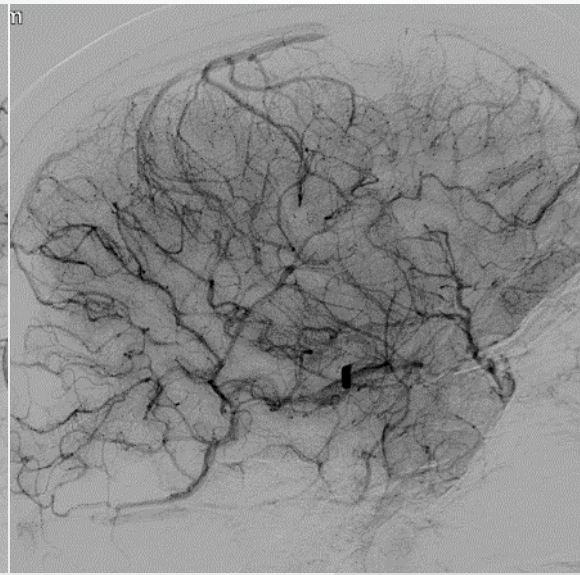
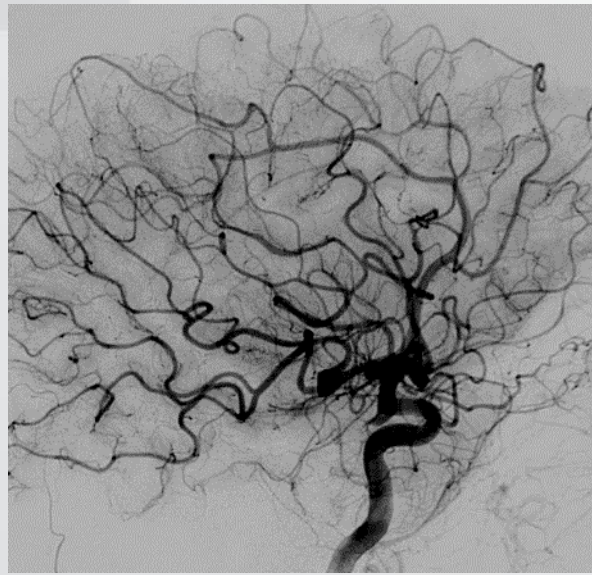
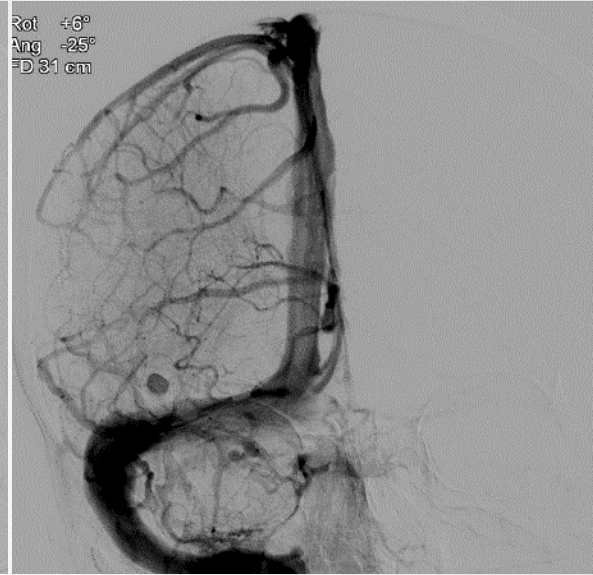
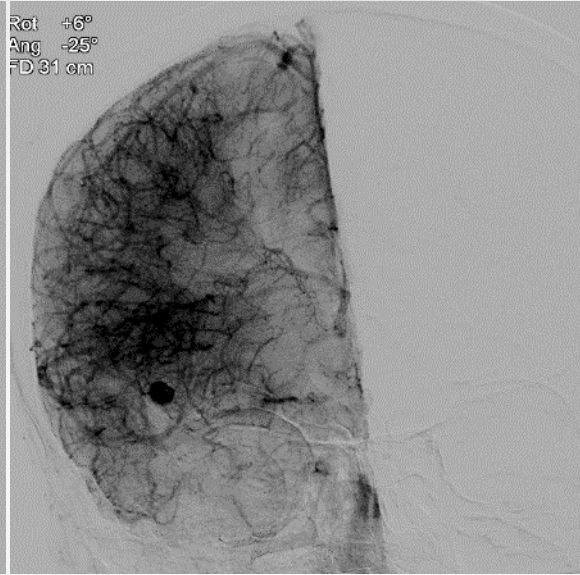
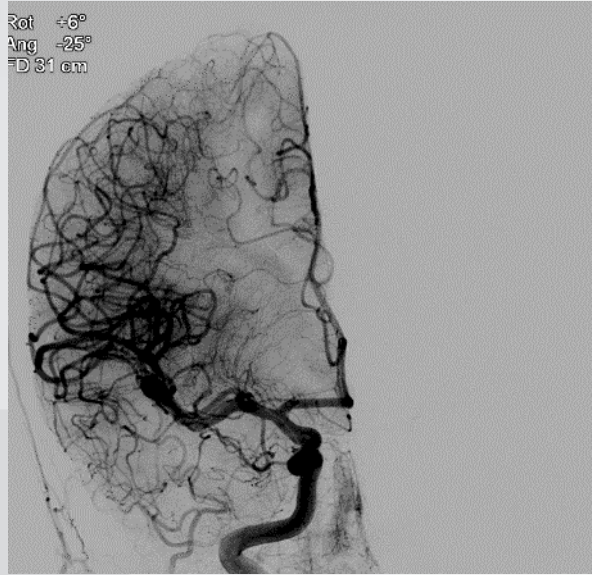

Size of the aneurysm : 7x5 mm
FD stent: FRED Jr. 2,5/18/13 mm



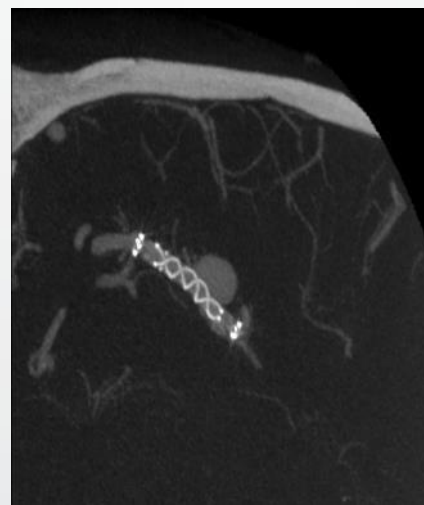
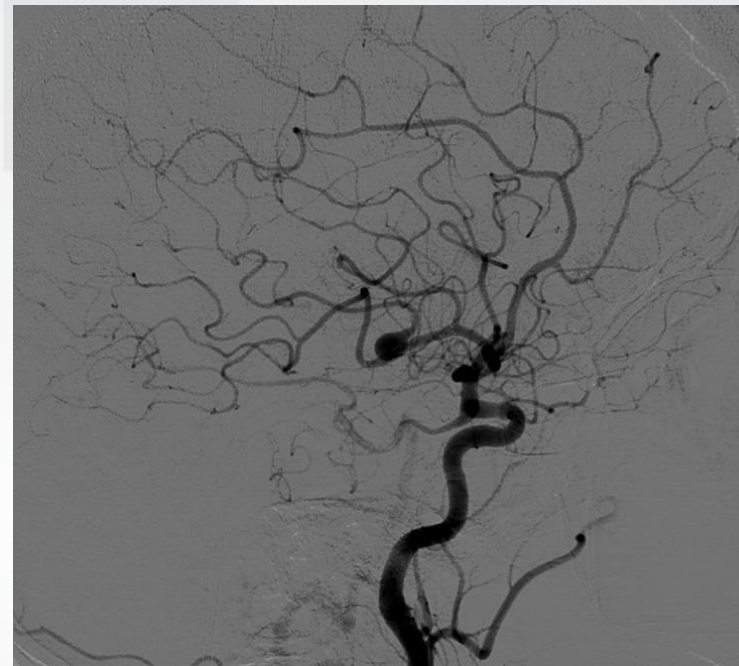
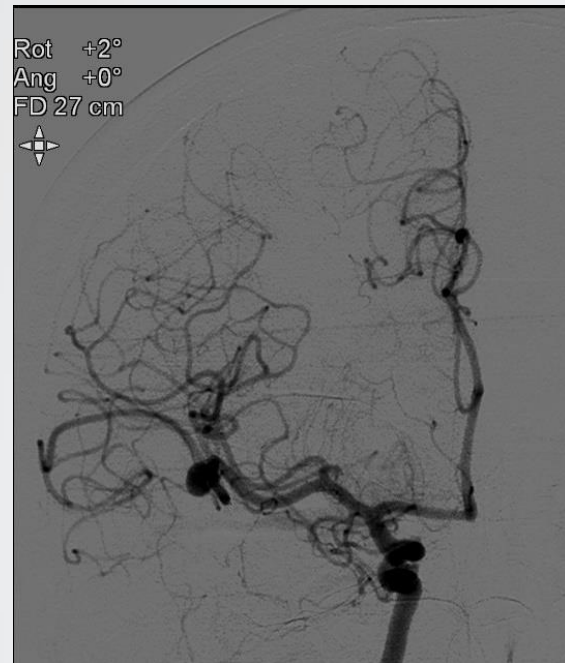


POST TREATMENT



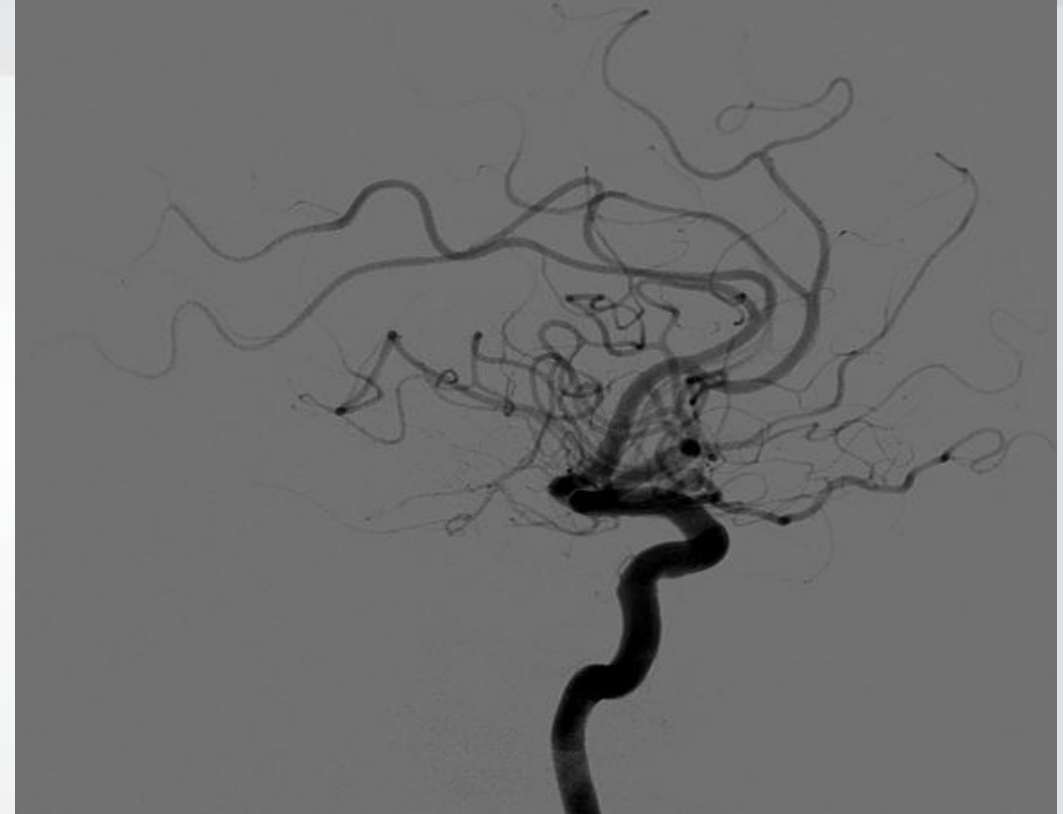
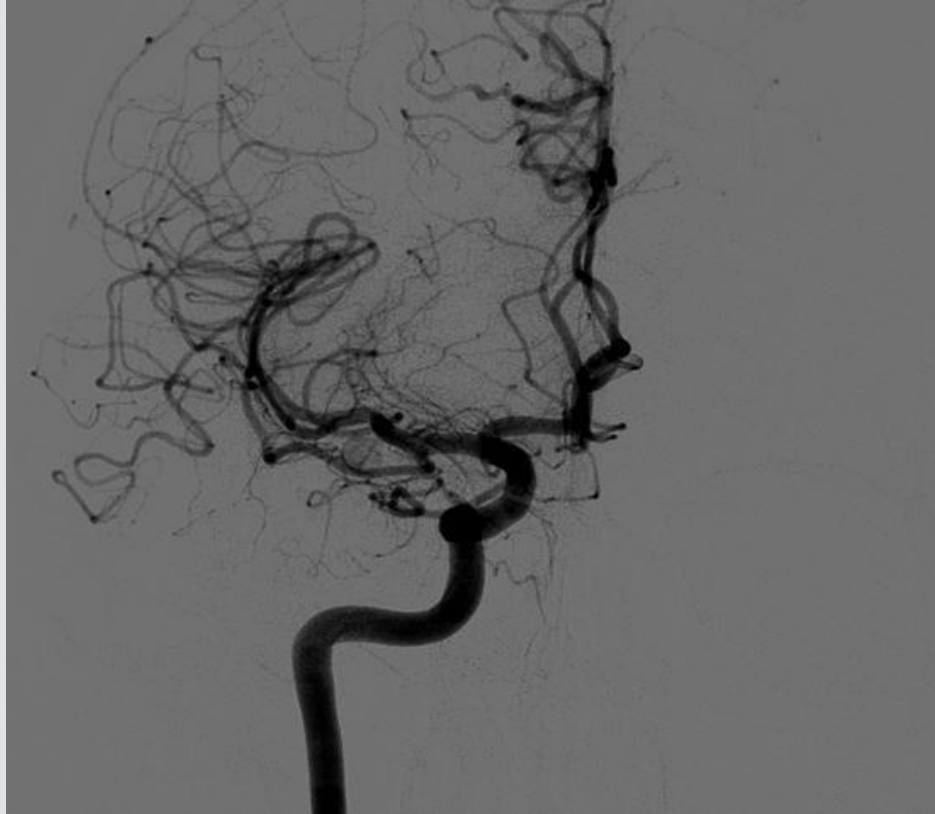
FOLLOW UP

DSA 31.12.2018



FOLLOW UP

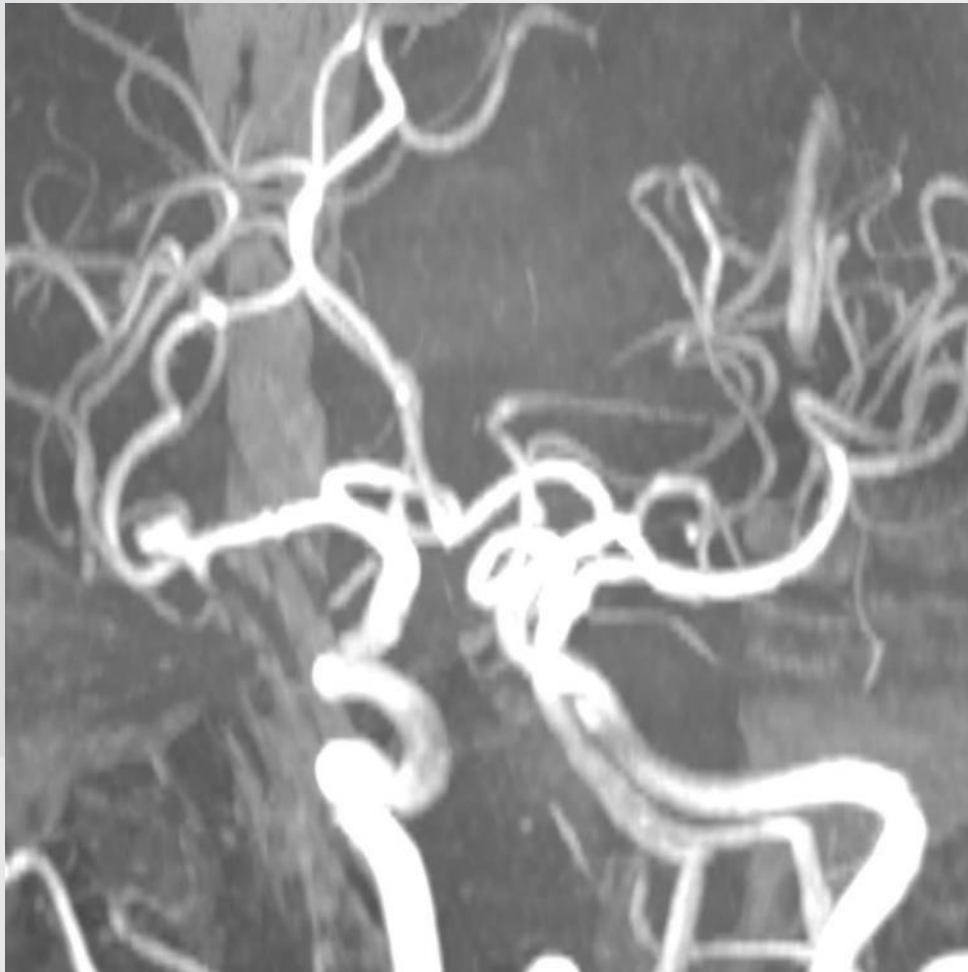05.11.2018



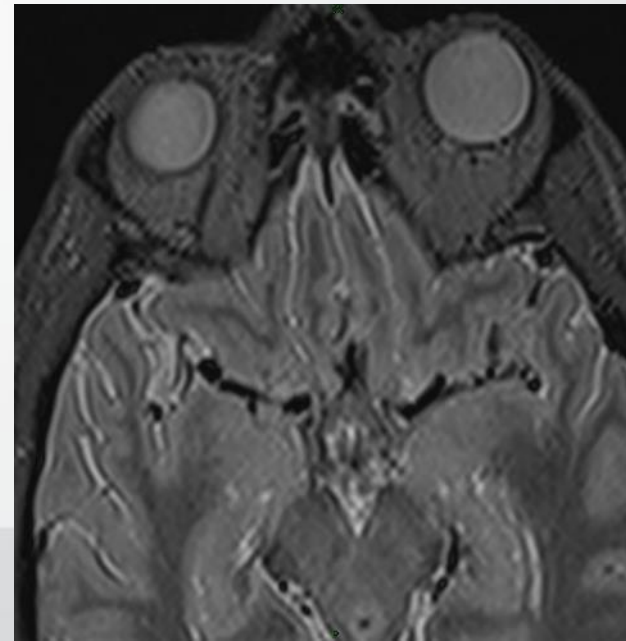
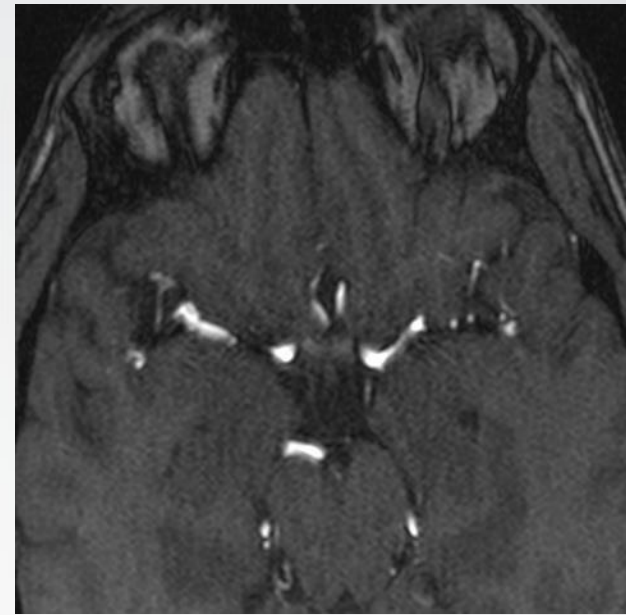
PATIENT 9 MIE

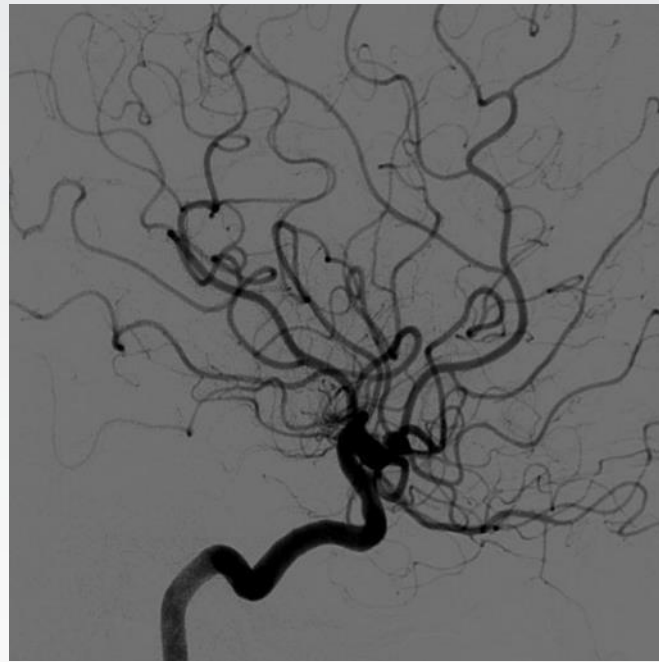
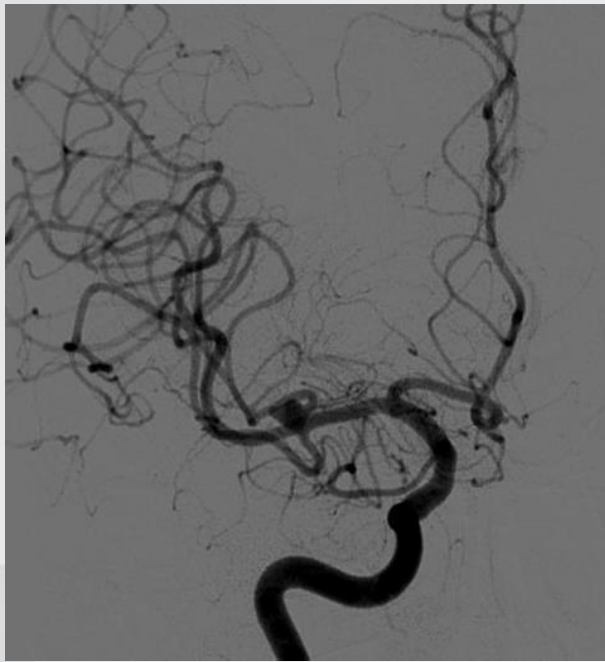
- 42Y M
- Presented by headache 4 months ago
- MRA-DSA:
**R MCA M1-M2 segment trifurcation
aneurysm**



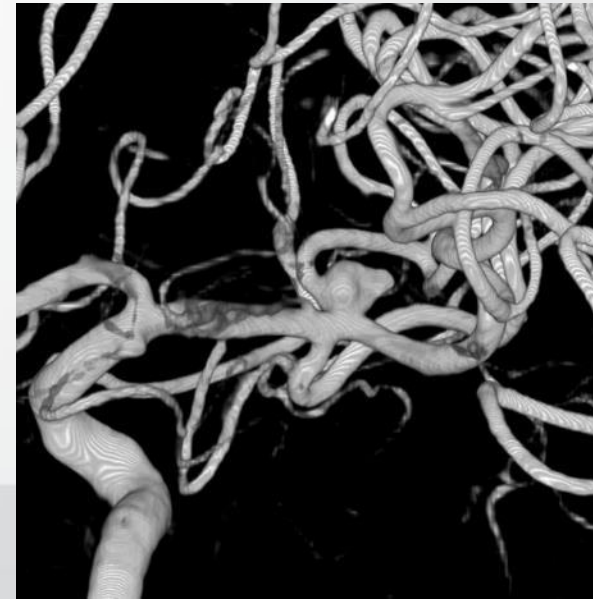
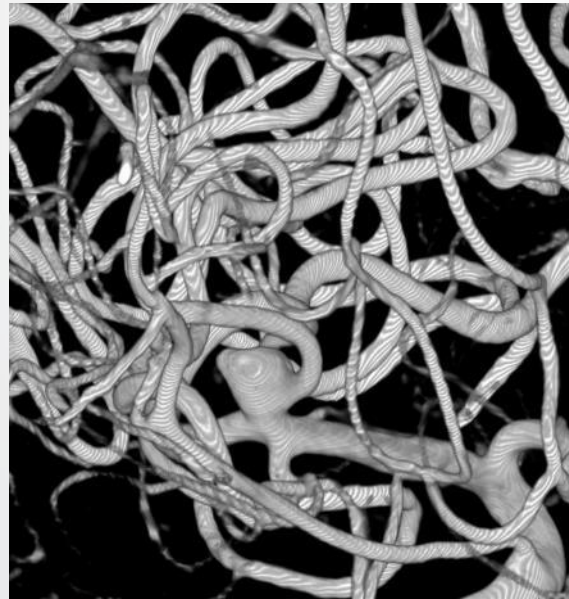
MRA 11.04.2018





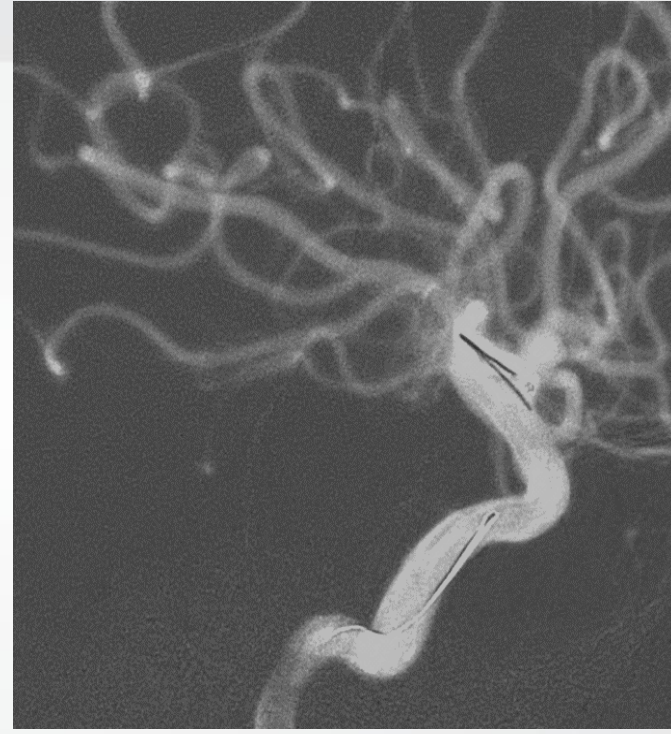
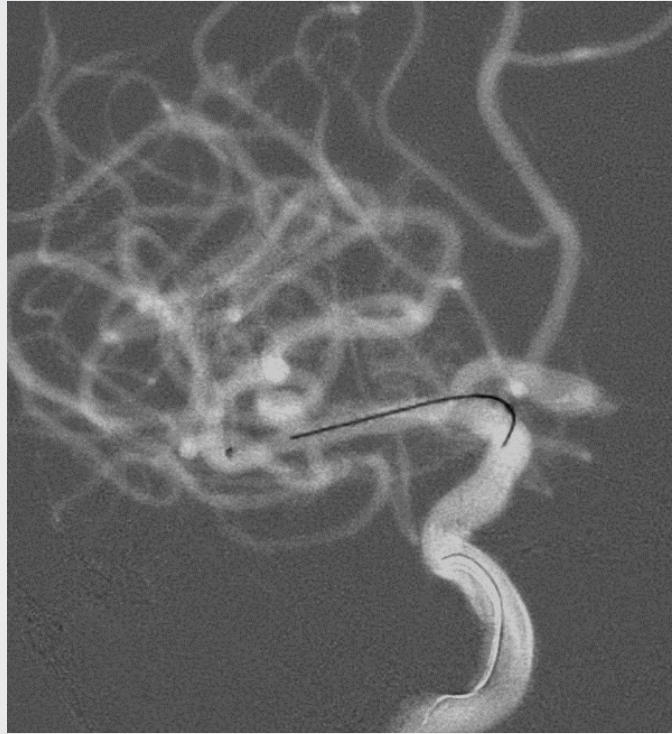
DSA 29.01.2018



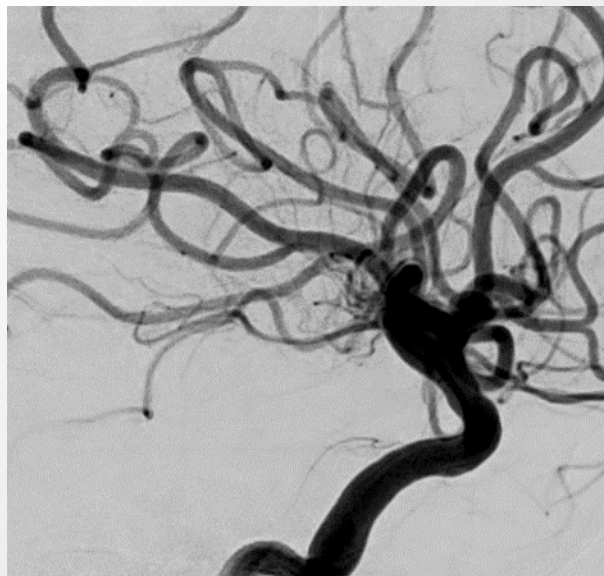
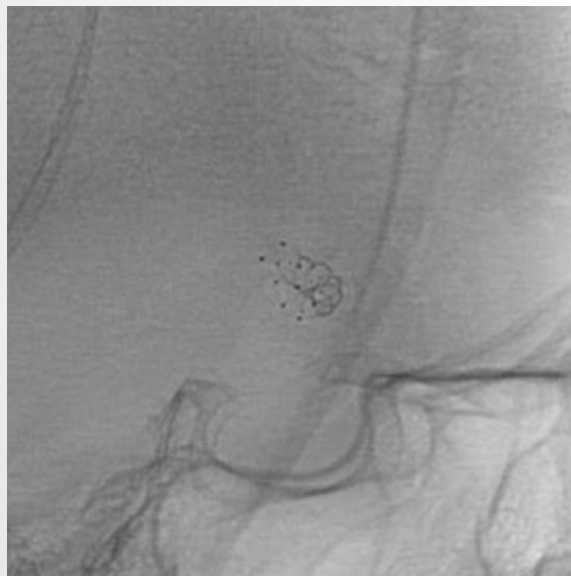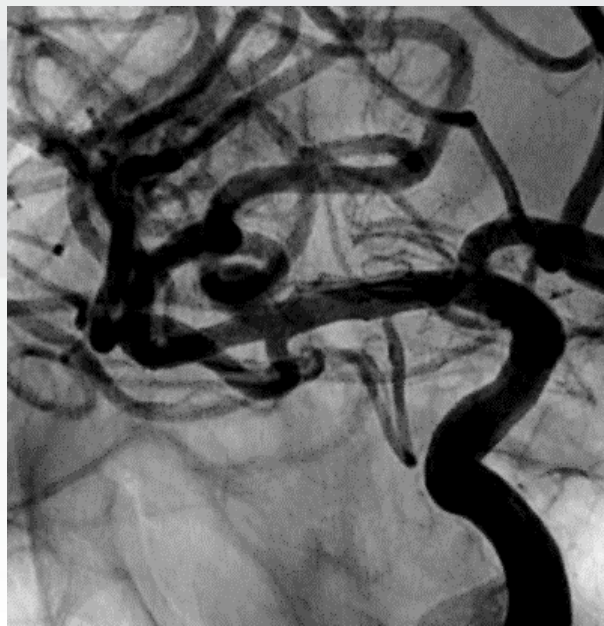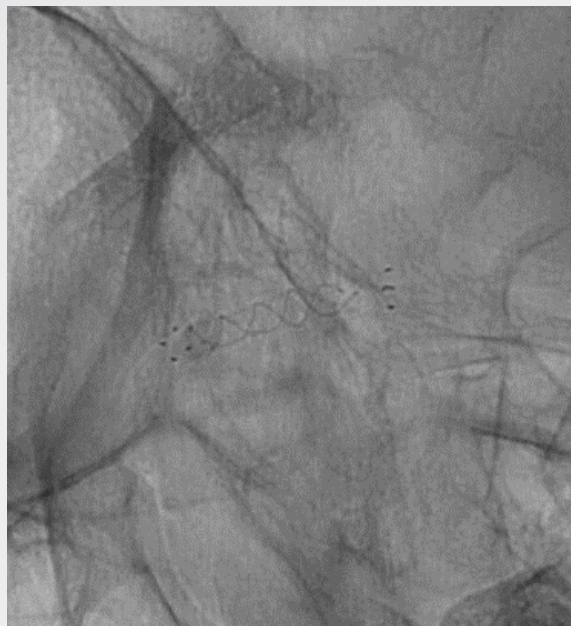
TREATMENT PLAN

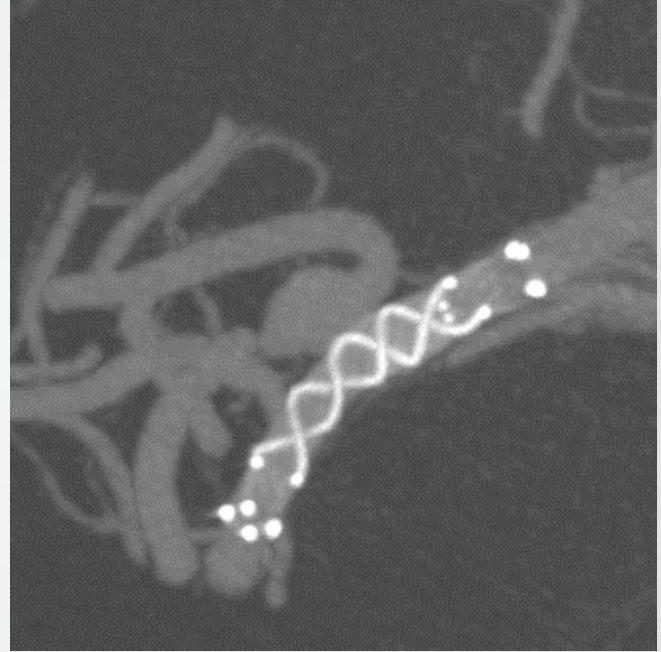
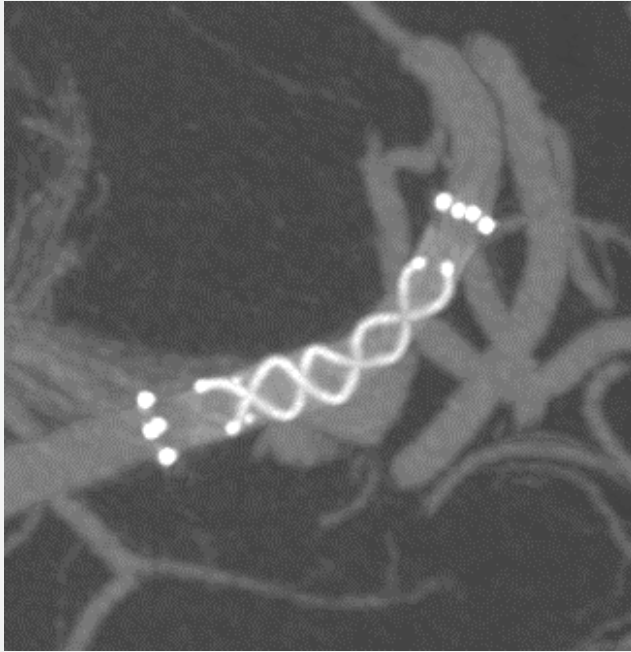
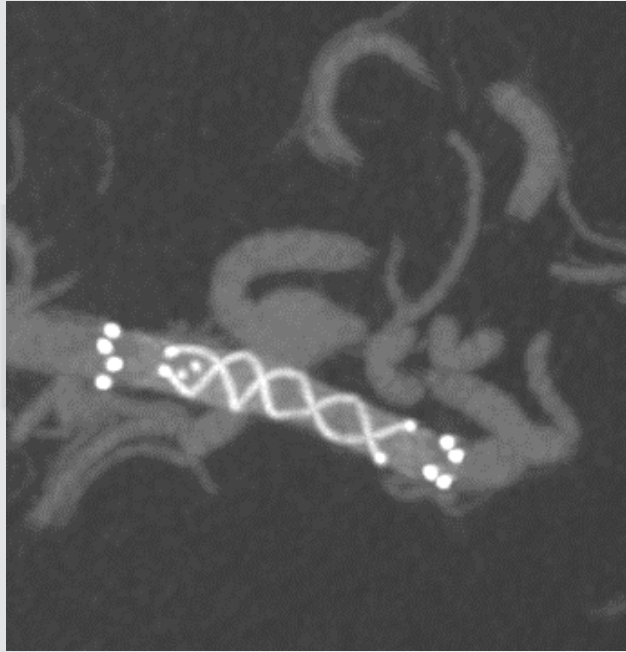
- Flow diverter stent

TREATMENT

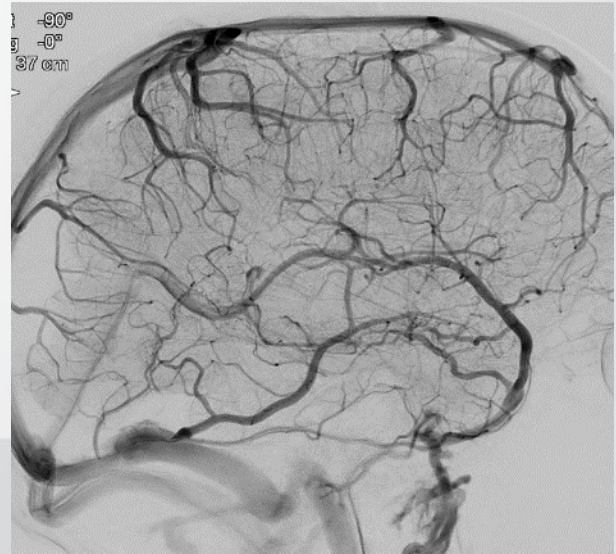
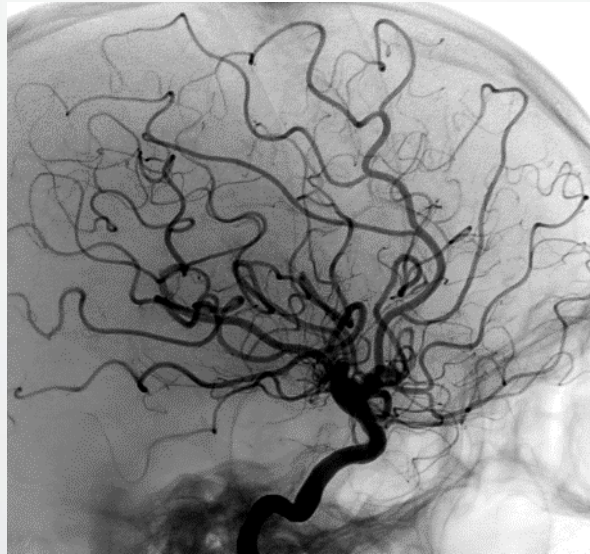
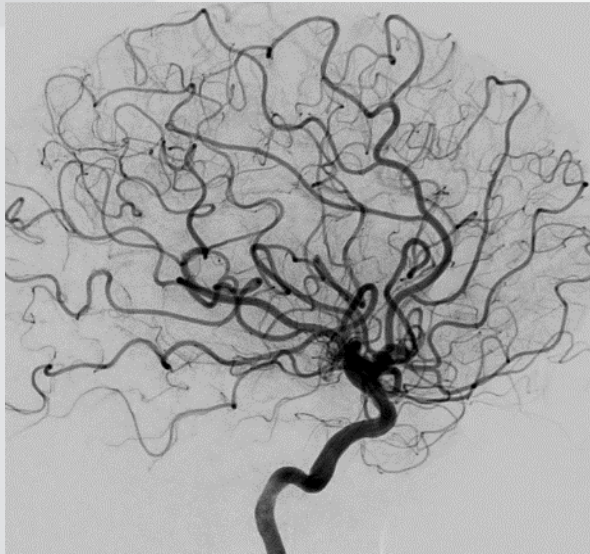
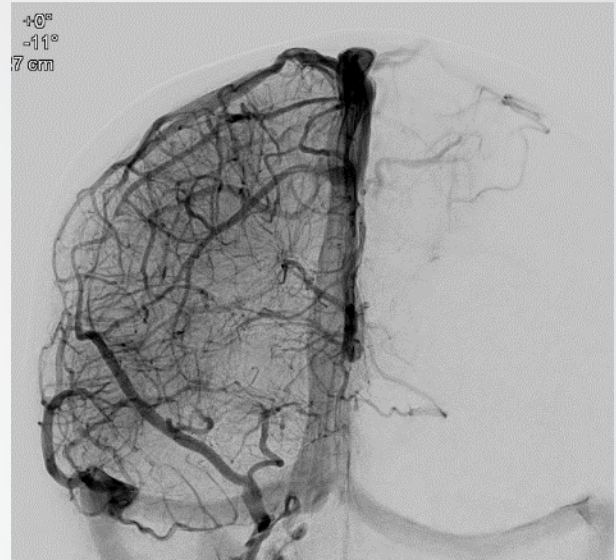
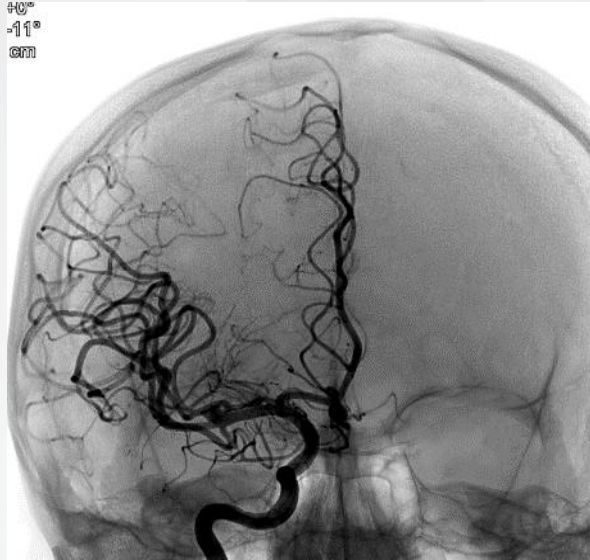
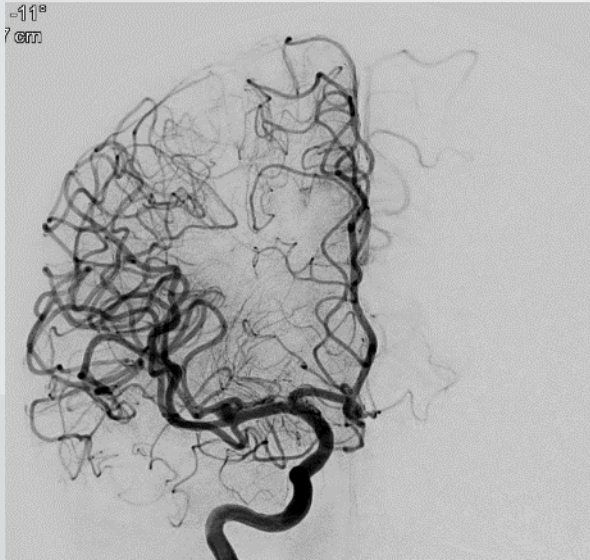

Size of the aneurysm : 4,5x4 mm
FD stent: Fred Jr 2,5/18/13 mm



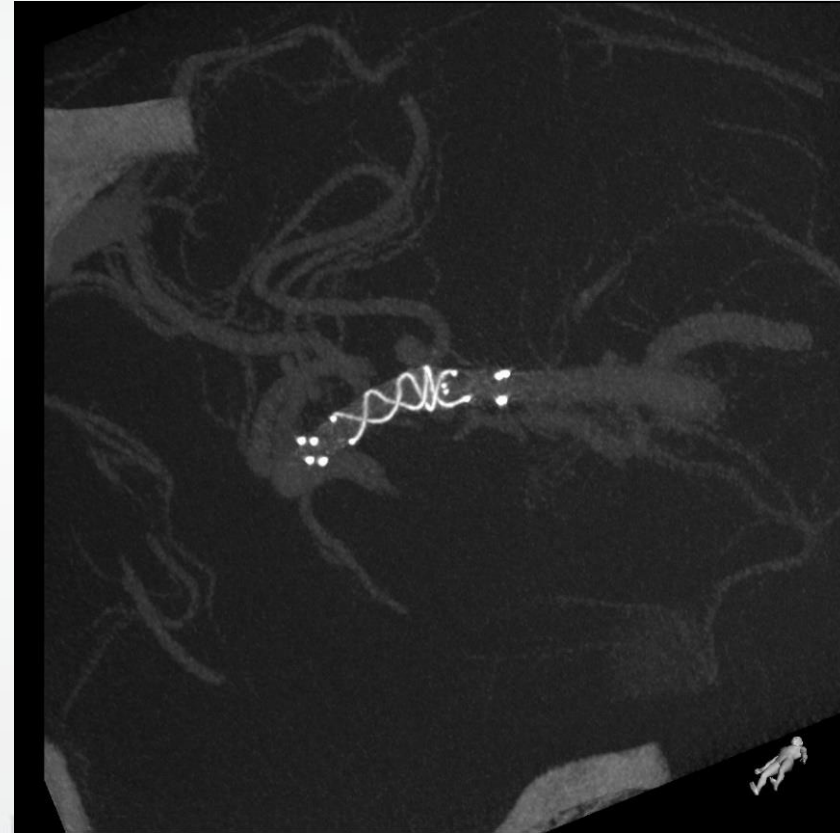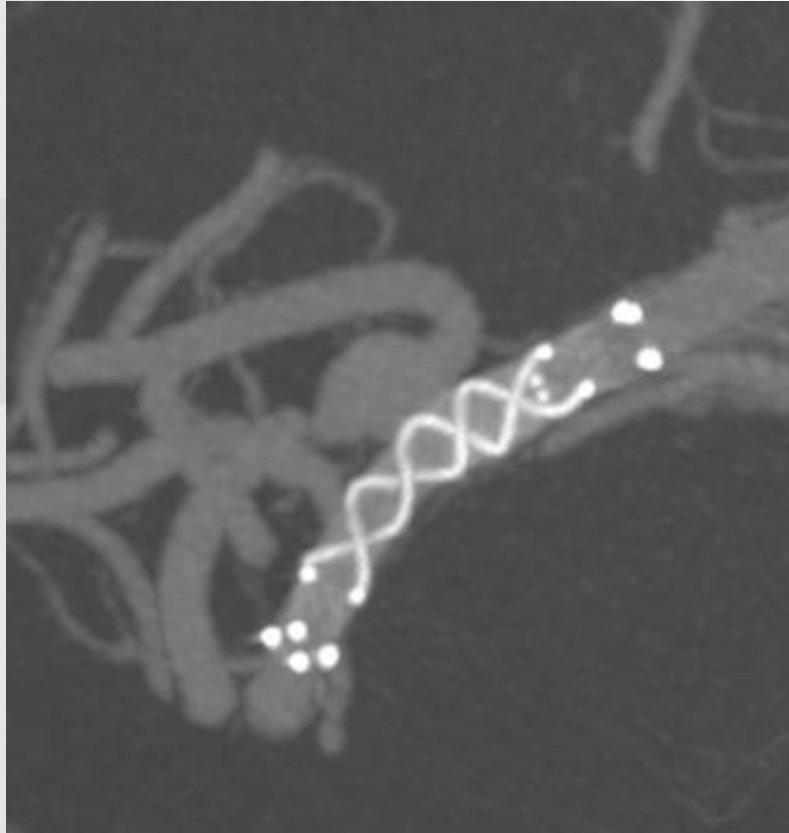


POST TREATMENT



FOLLOW UP

05.11.2018

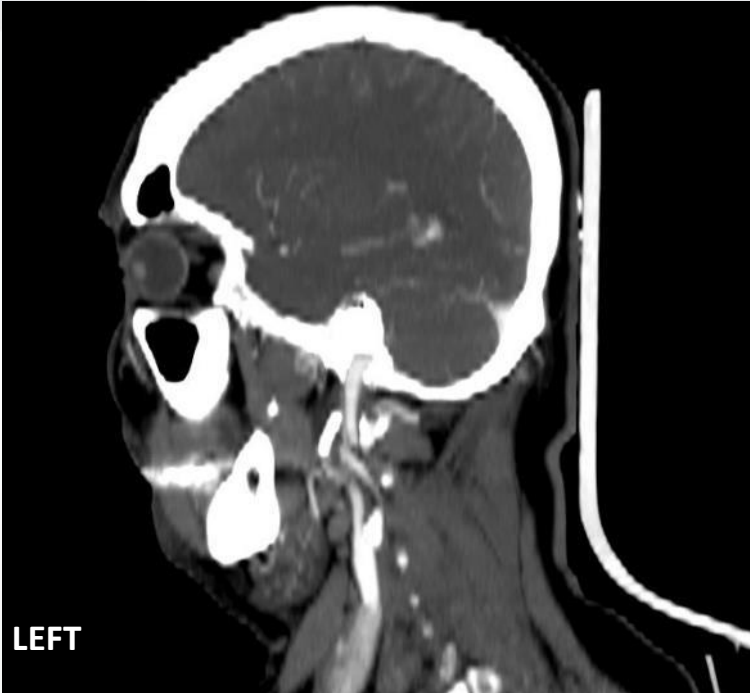
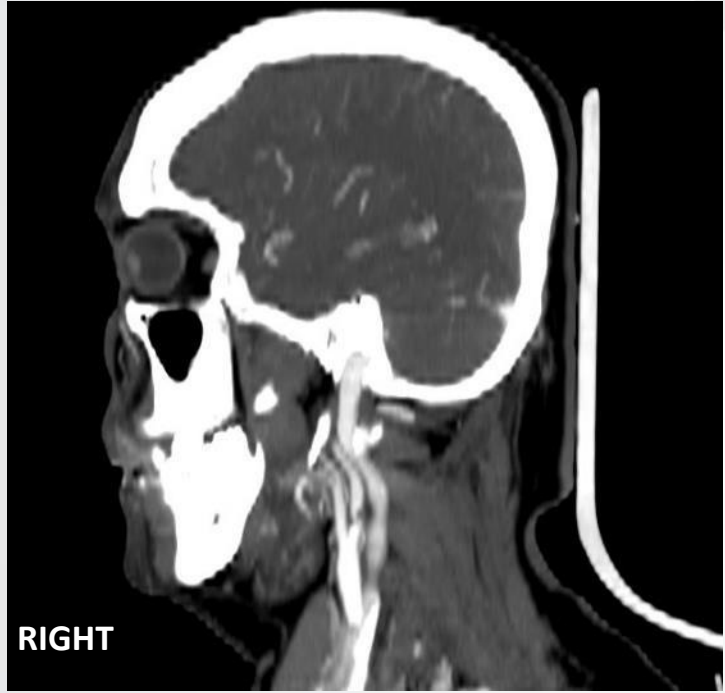


PATIENT 10 YS

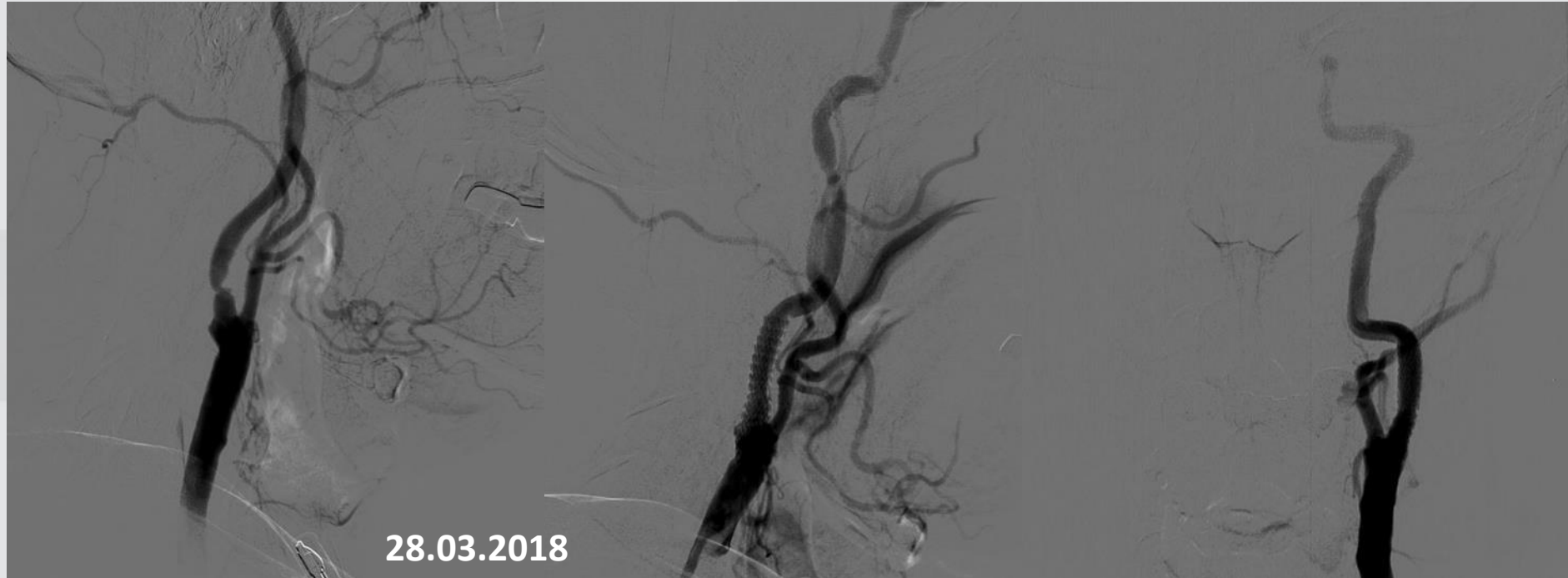- 63 Y M
- Presented with TIA
- CTA-DSA:
Bilateral ICA postbulbar segment stenosis
- L ICA postbulbar segment stenosis treated with stent 1 month ago



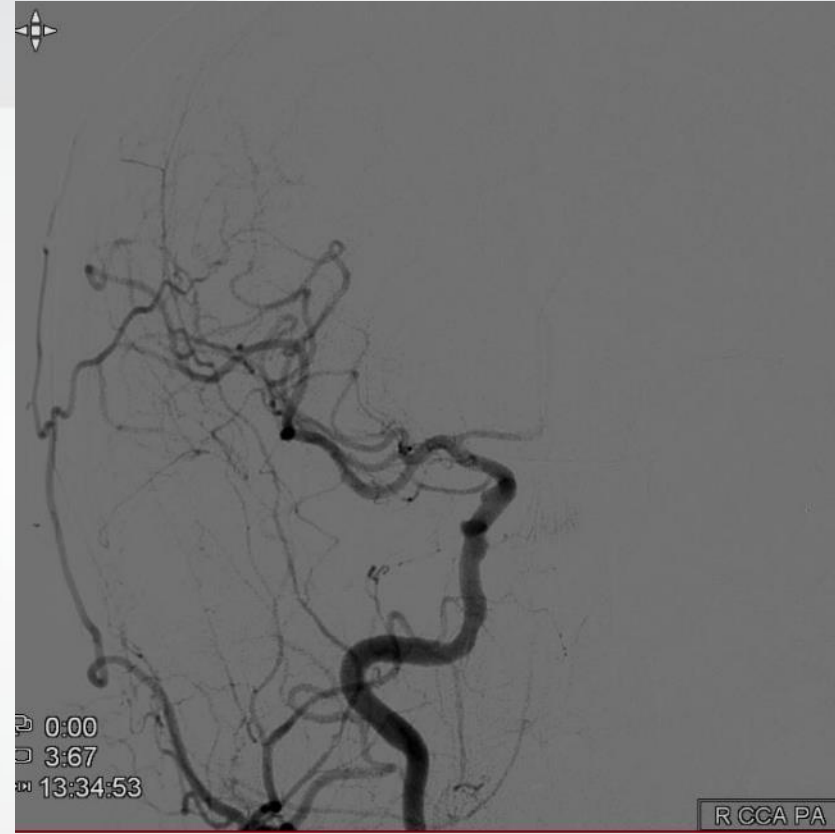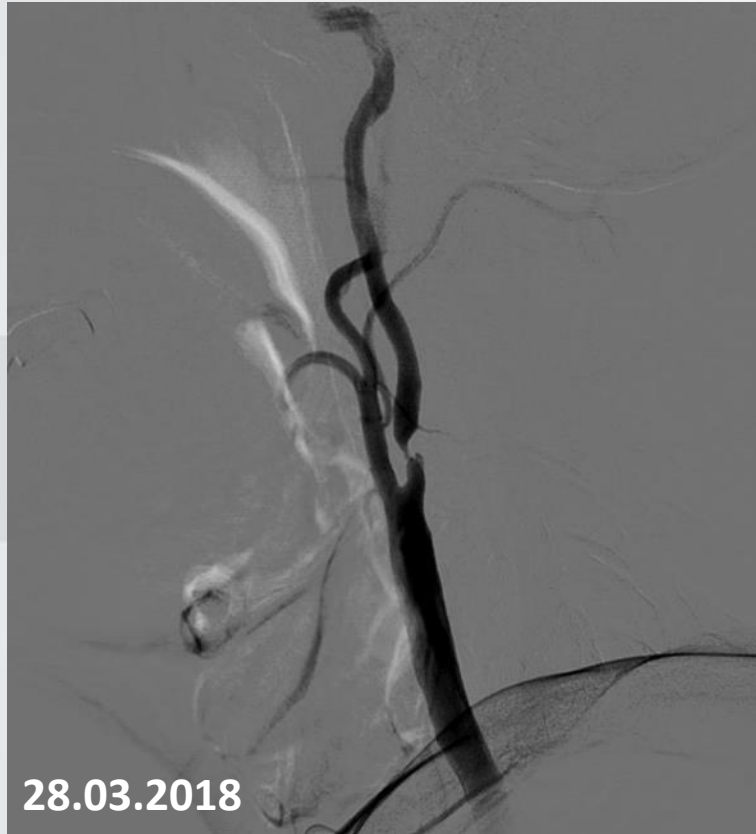CTA 15.02.2018



L ICA STENT TREATMENT



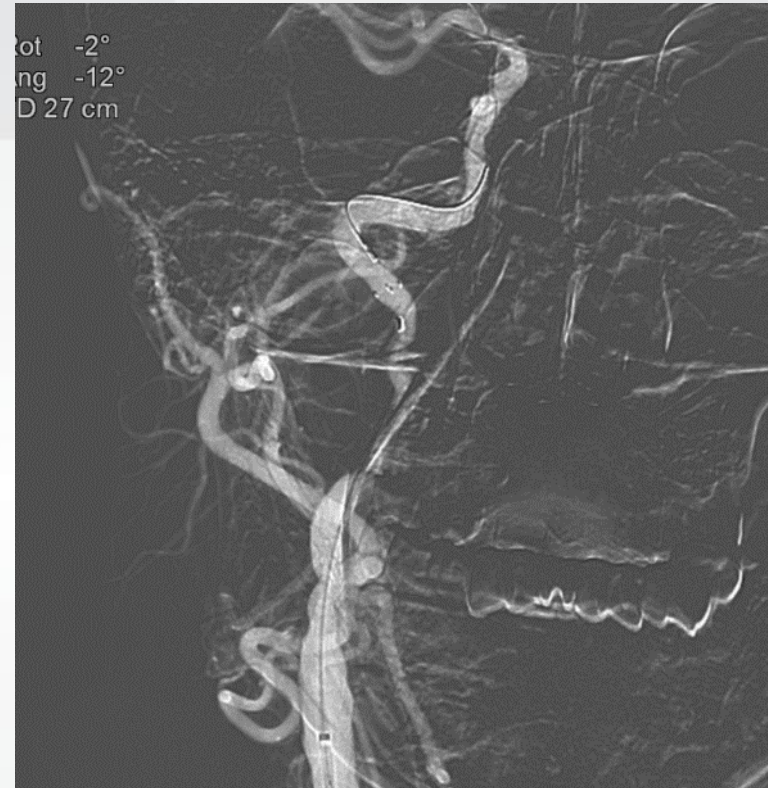
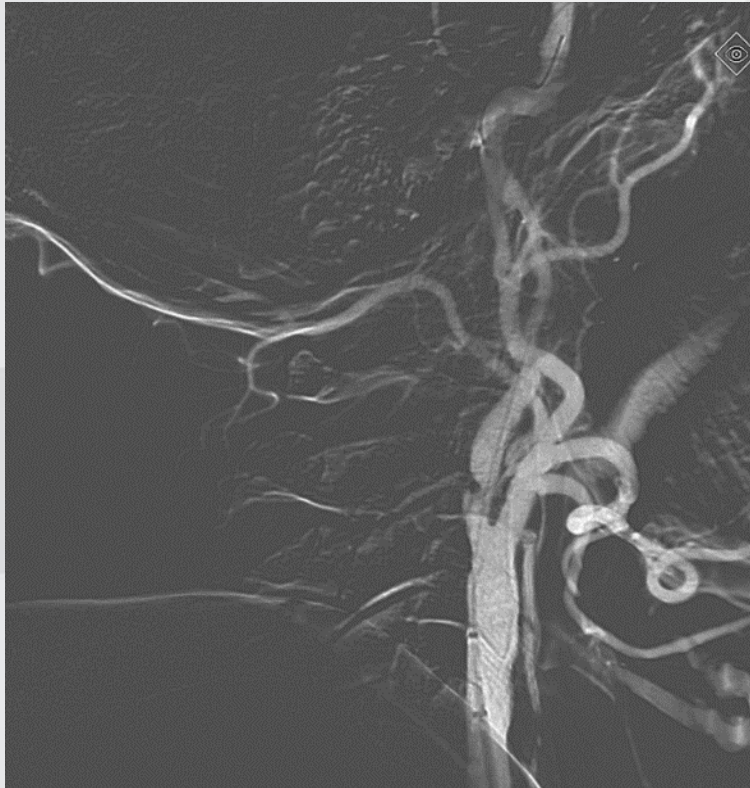R ICA Stenosis



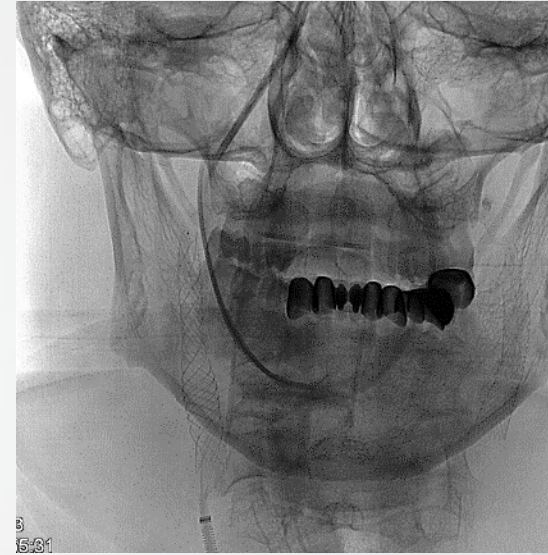
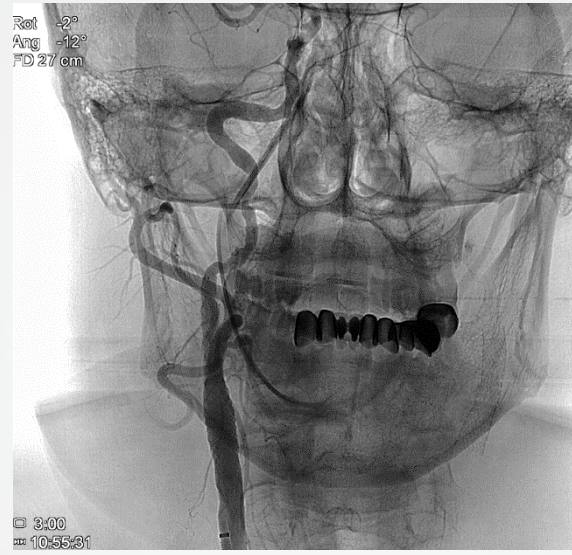
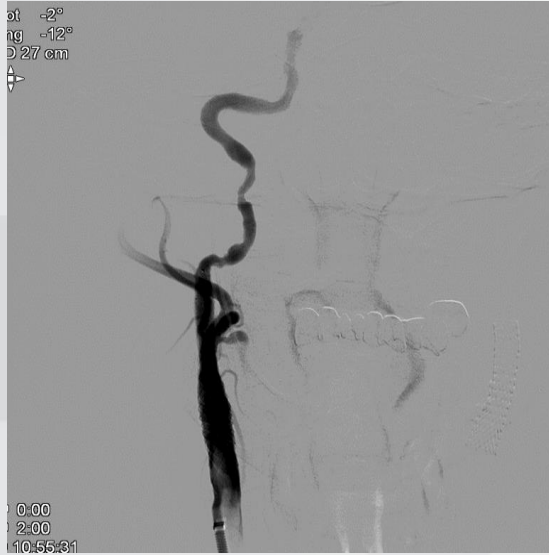TREATMENT PLAN

- Angioplasty /stent to R ICA

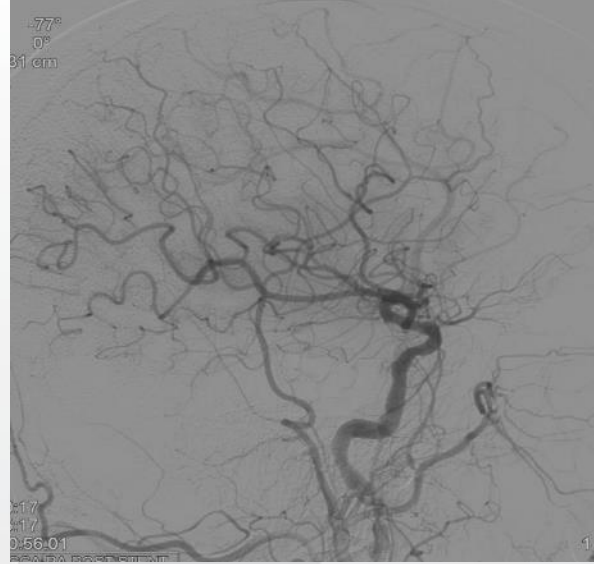
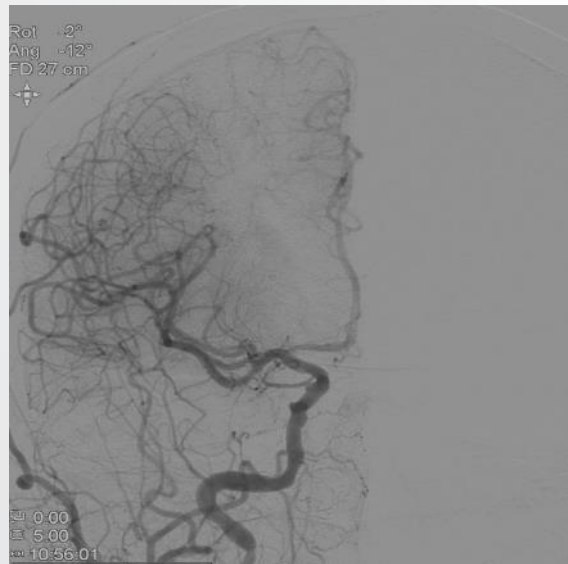
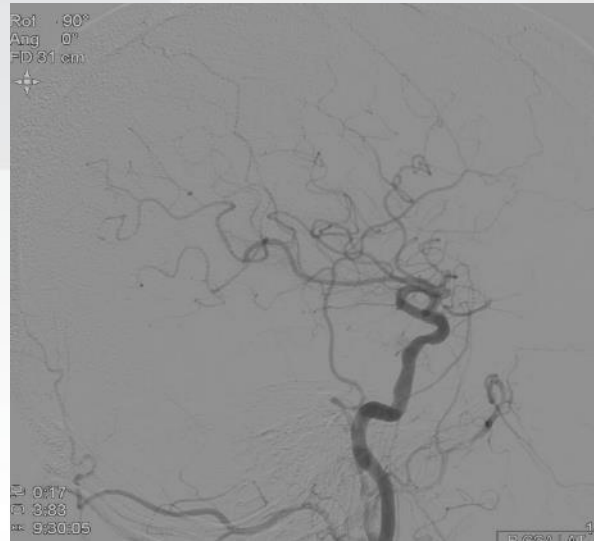
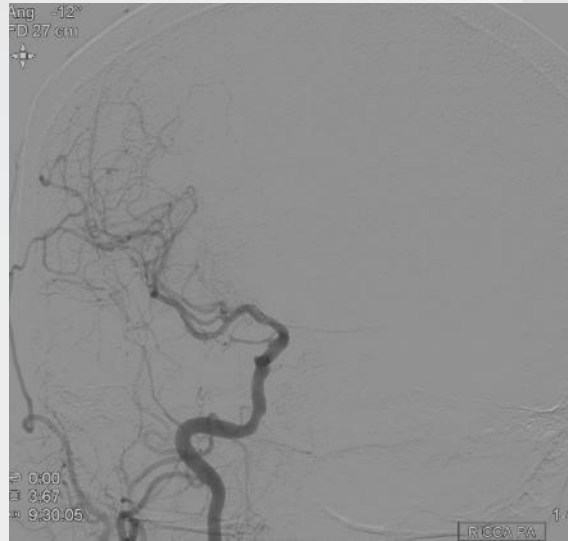
TREATMENT




Carotid Stent System : CASPER 8mm/30mm



POST TREATMENT



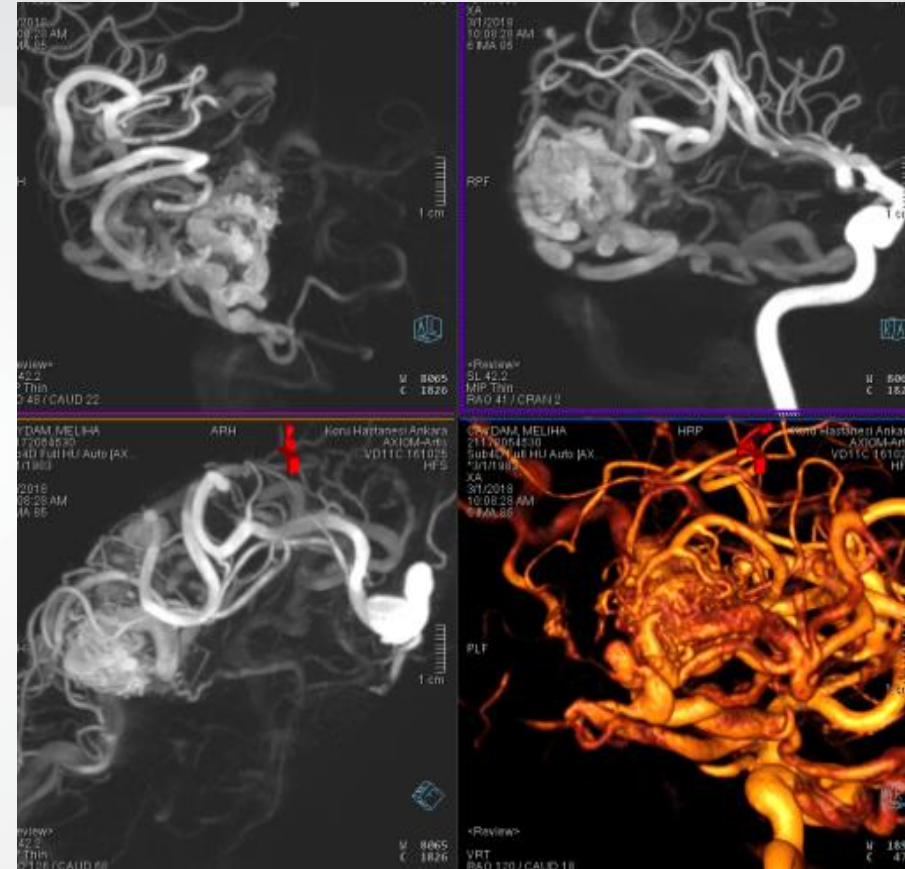


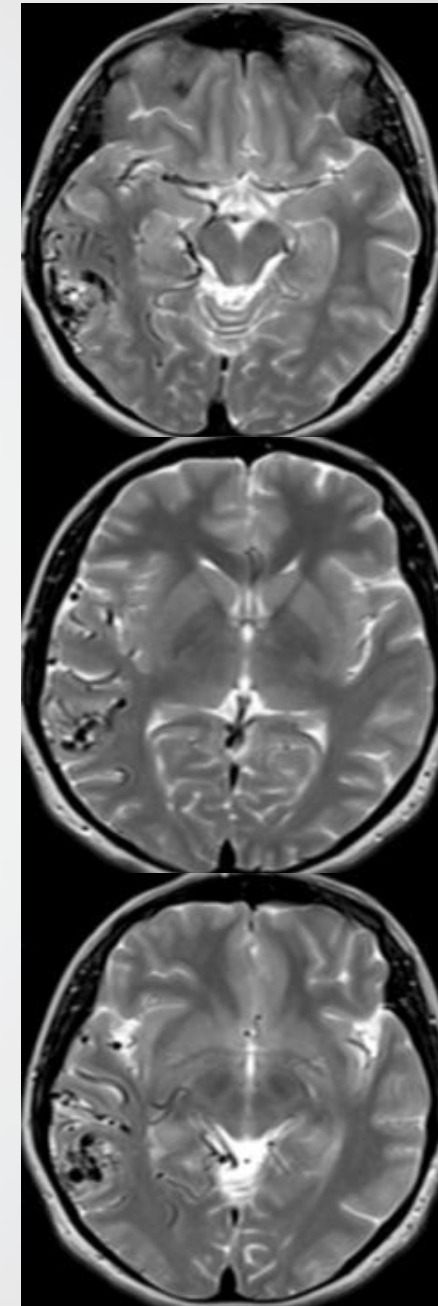
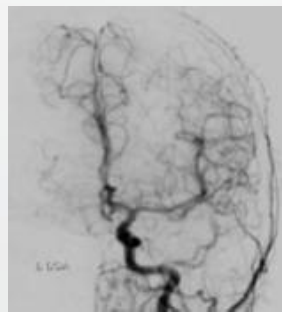
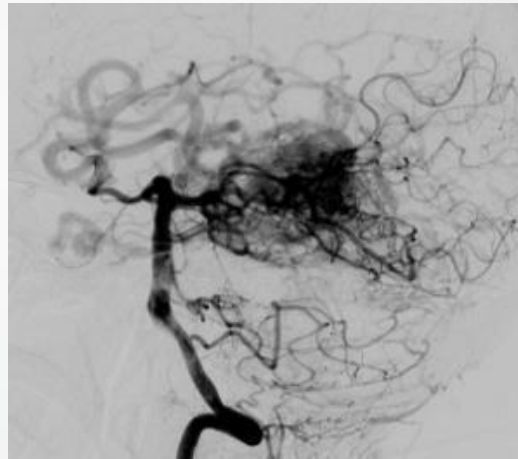
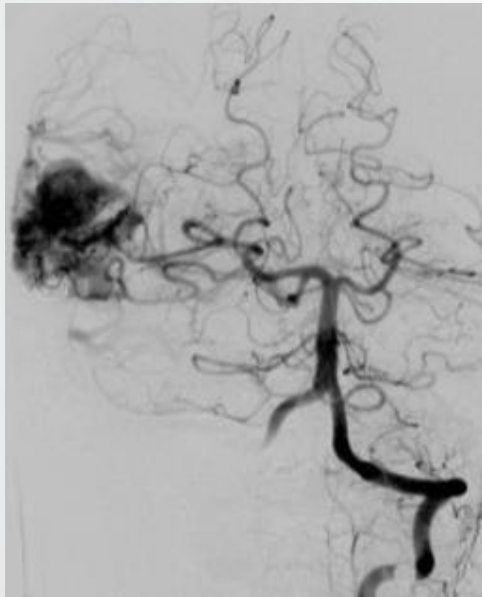
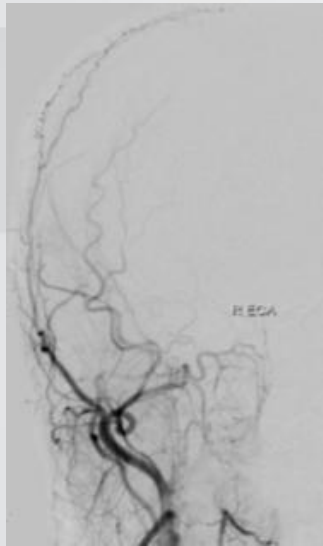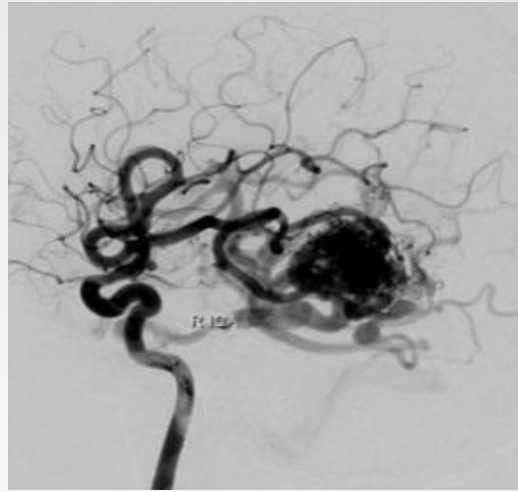
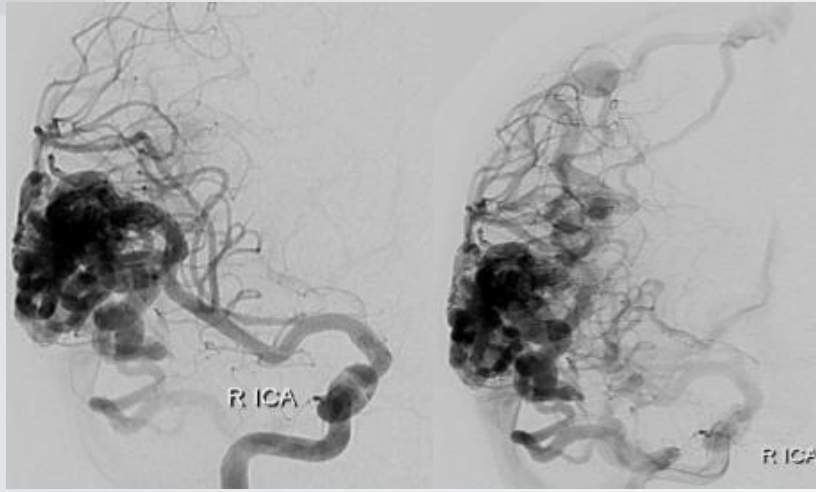
WLNC 2018

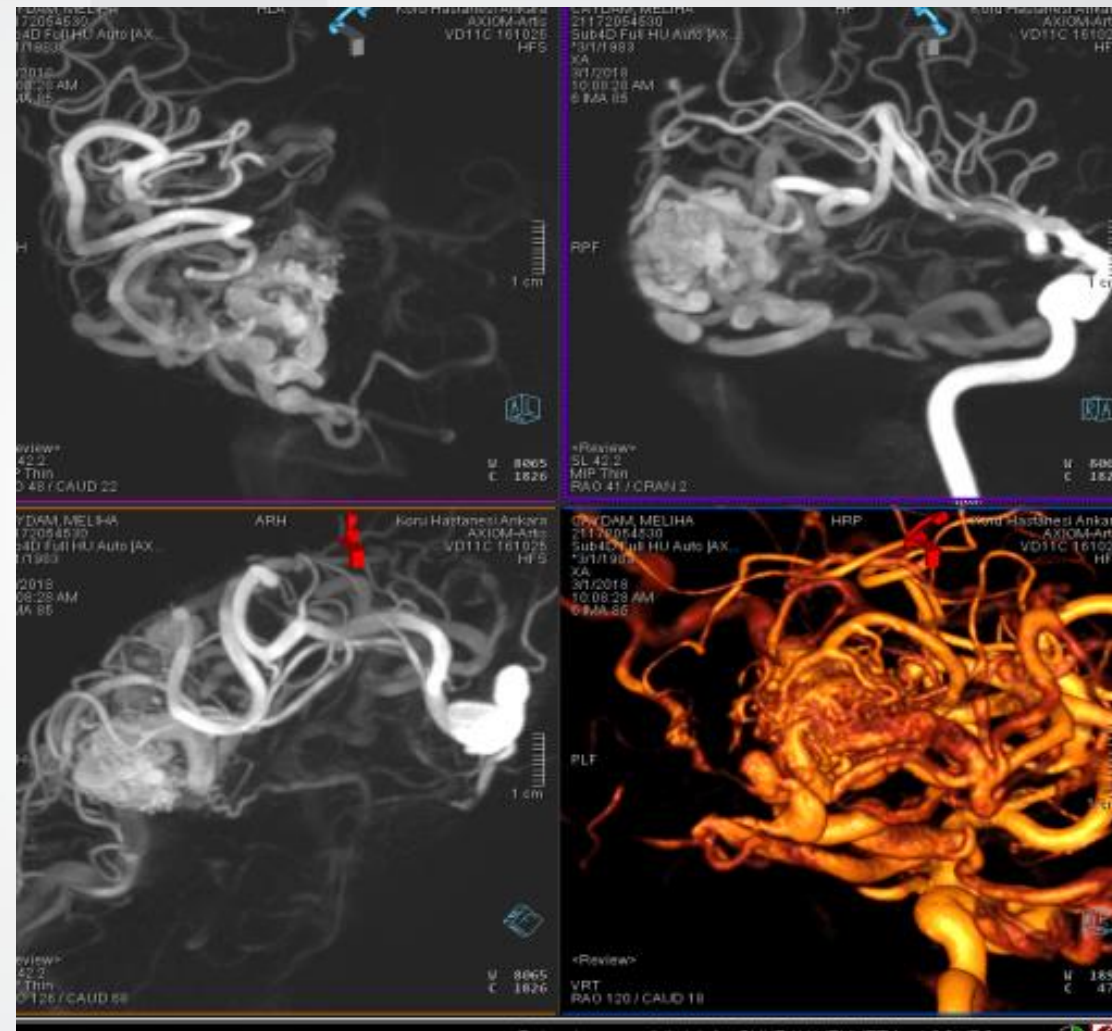
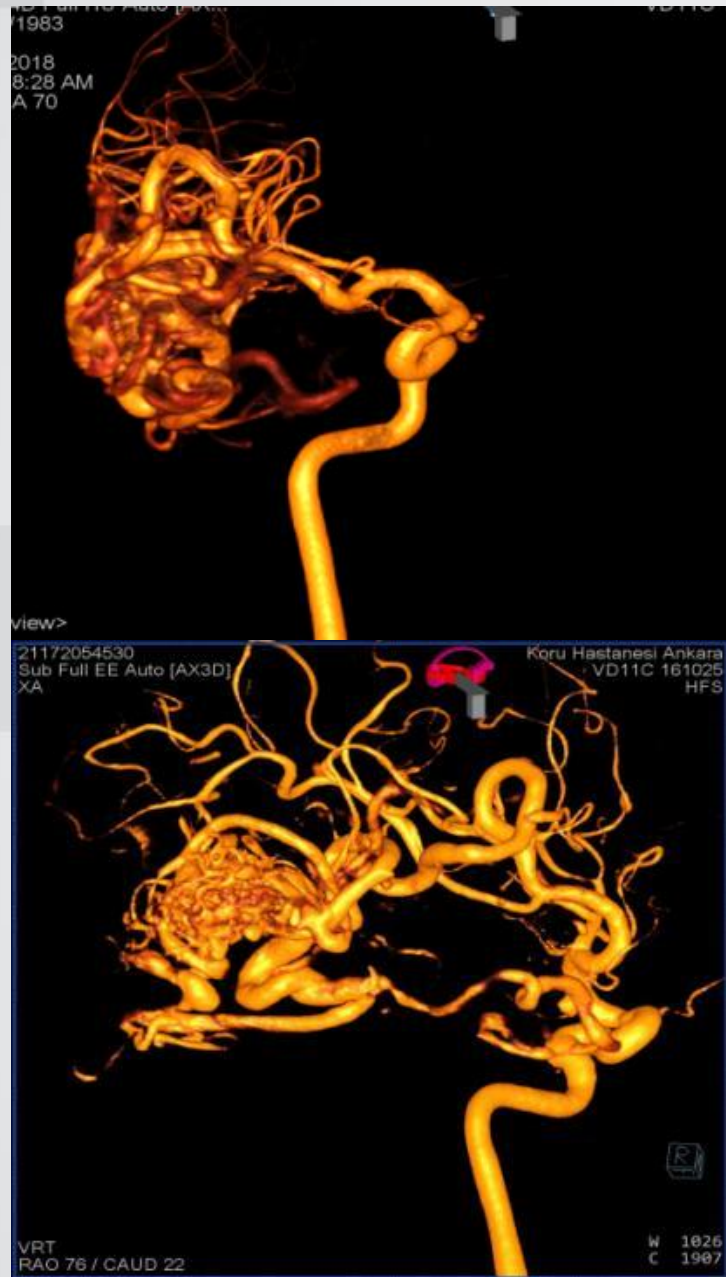ANKARA CASES

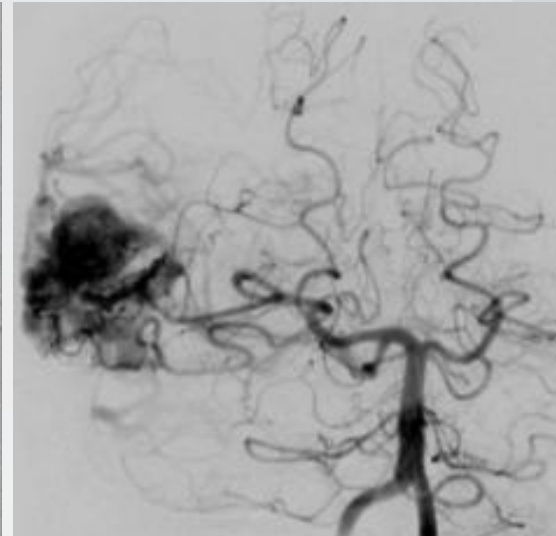
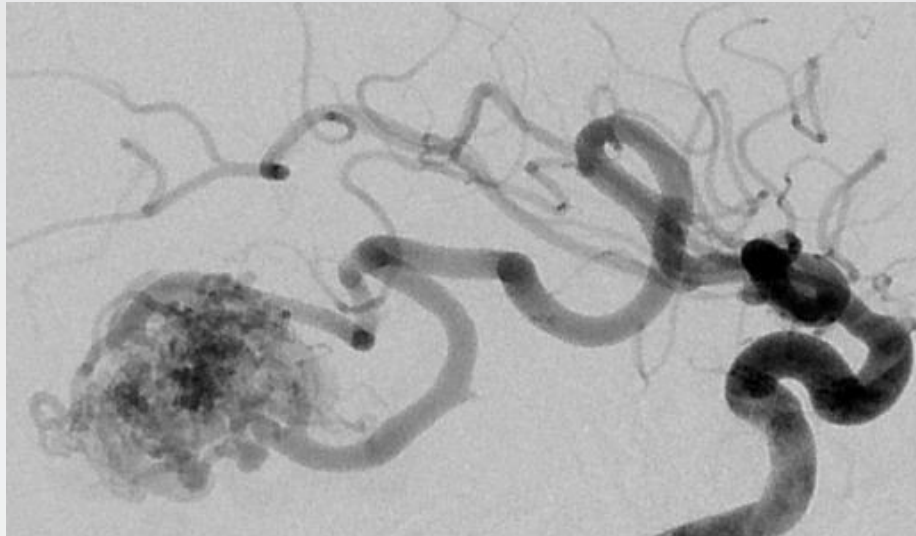
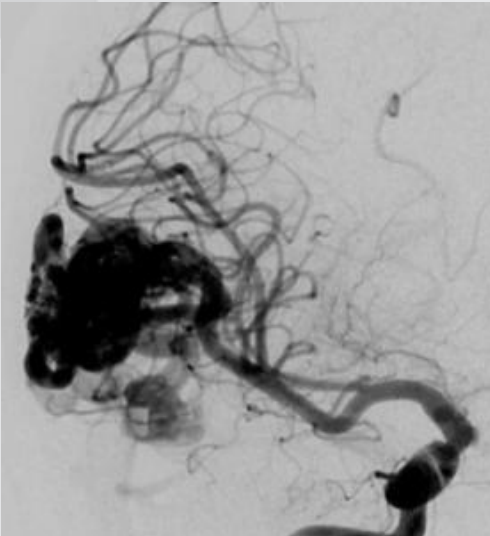
PATIENT 1

- **35 yo, female**
- Headache
- Right temporal AVM , grade II, with venous aneurysms
- Fed by two R MCA feeders and one post temp-PCA feeder
- Complete intranidal flow control is targeted with DL balloon and two detachable catheters to close the AVM





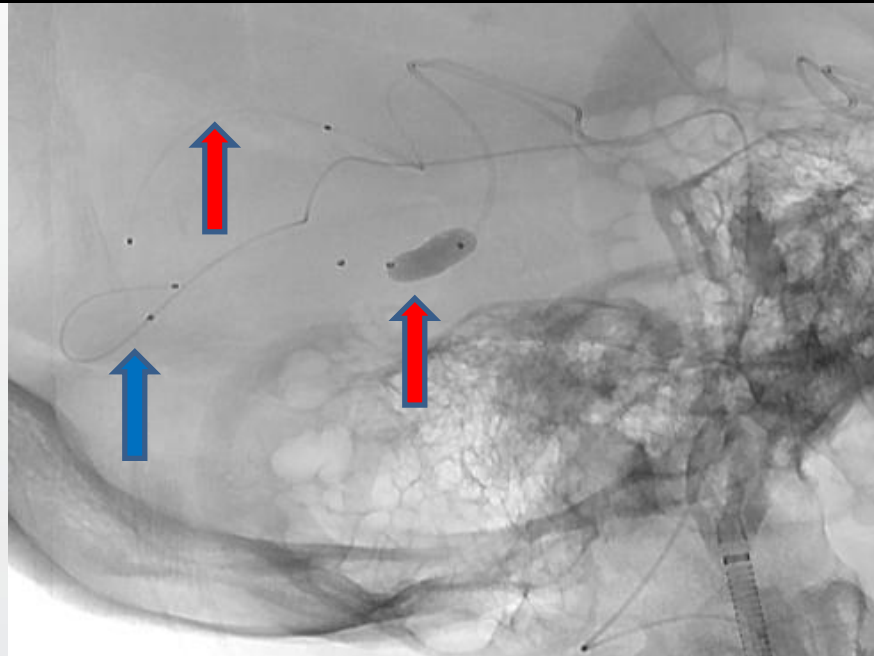


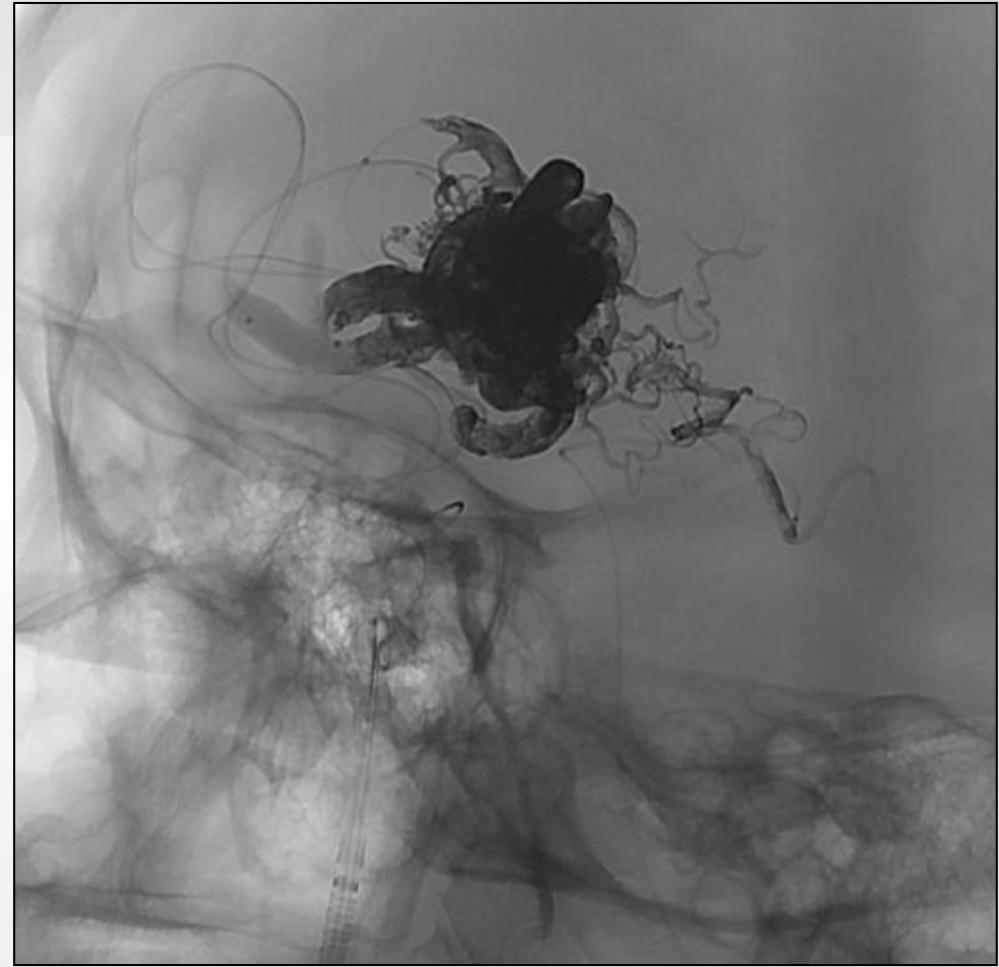
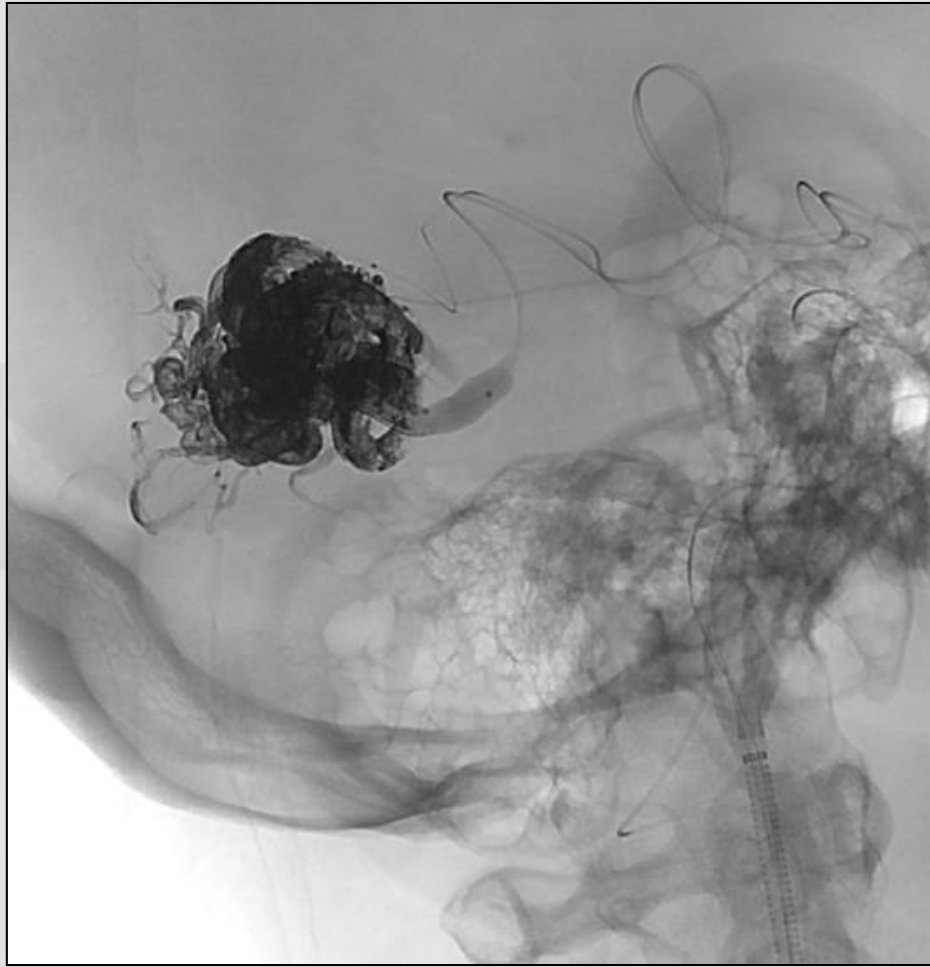


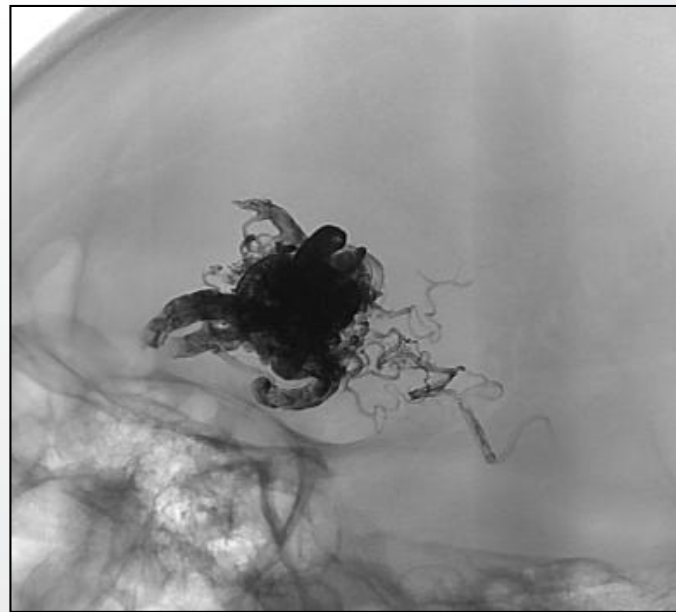
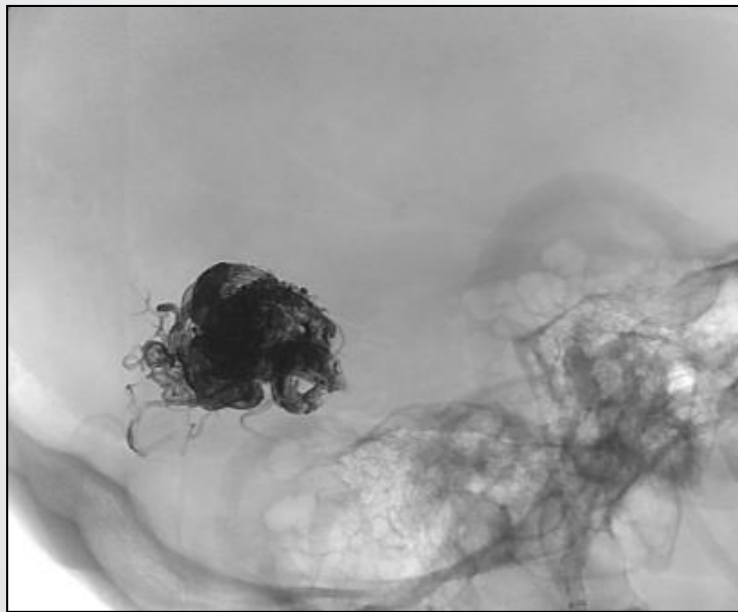
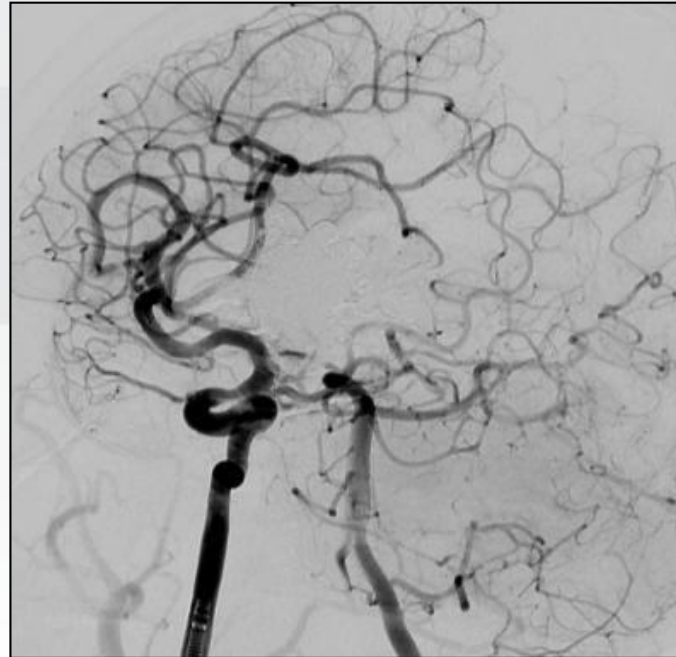
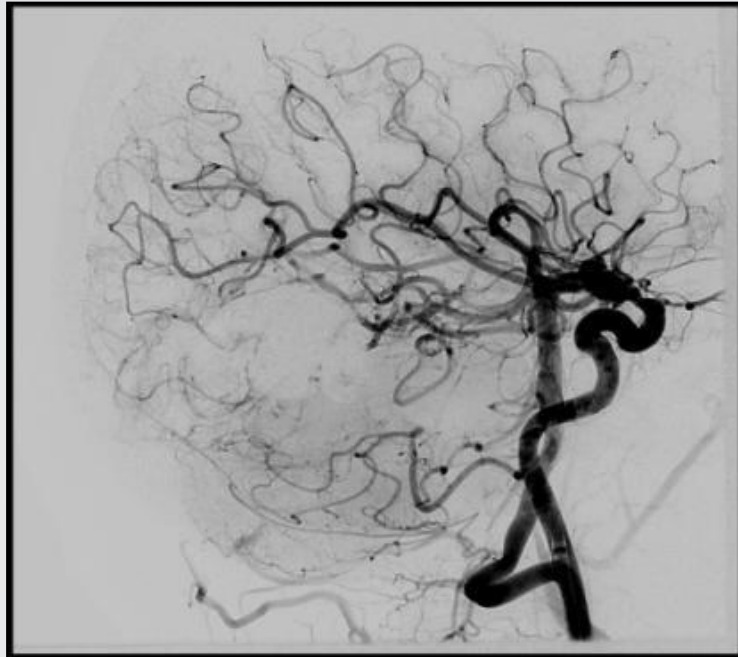
MULTIPLUG INTRANIDAL FLOW CONTROL TECH WAS USED; A SCEPTER XC AND AN APOLLO FROM TWO MCA FEEDERS AND ANOTHER APOLLO WAS PLACED FROM THE PCA-POST TEMP FEEDER TO THE NIDUS AND BALLOON AND ONYX REFLUX PLUGS , ULTIMATE INTRANIDAL FLOW CONT WAS OBTAINED AND AVM WAS CLOSED...

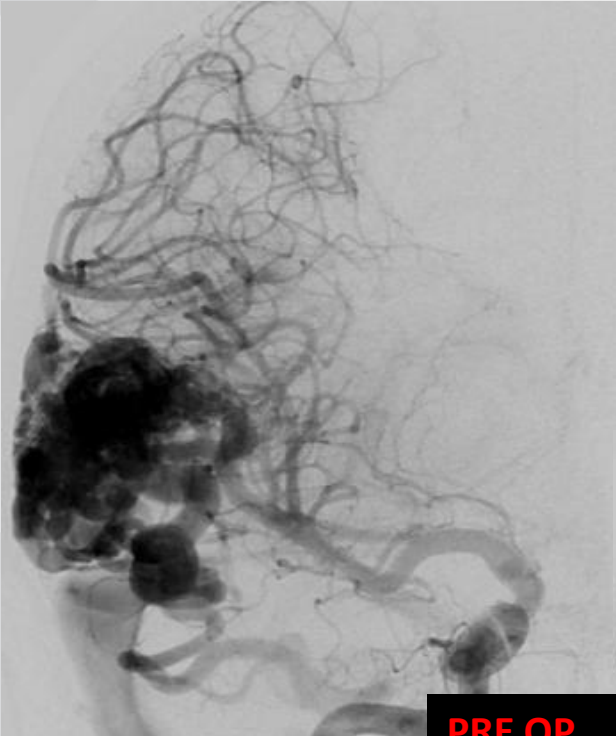
RED ARROWS SHOWS THE SCEPTER AND APOLLO IN THE INF AND SUP R MCA FEEDERS

BLUE ARROW SHOWS THE APOLLO IN THE PCA-POST TEMP FEEDER

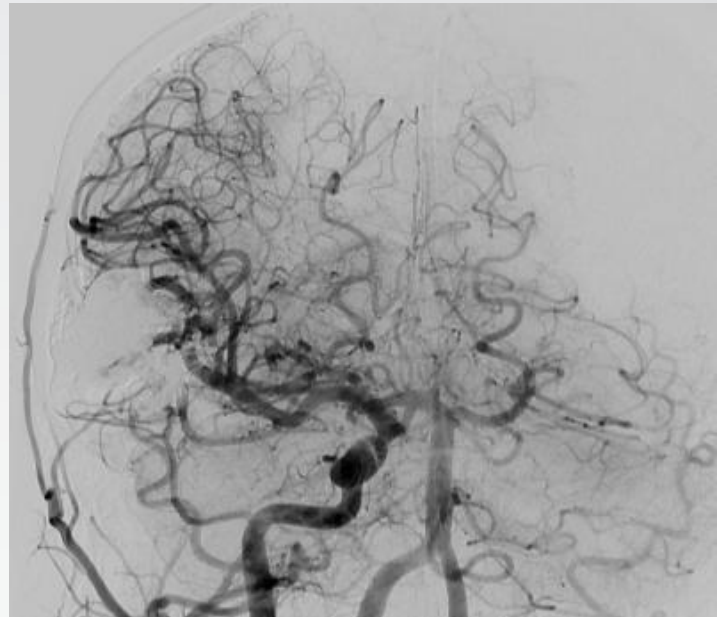
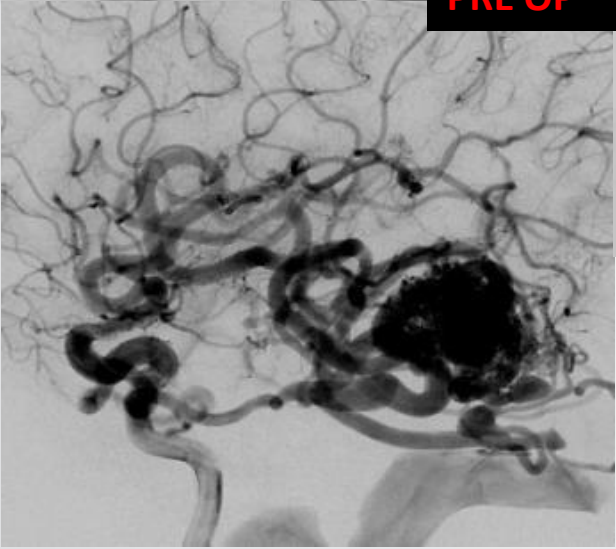
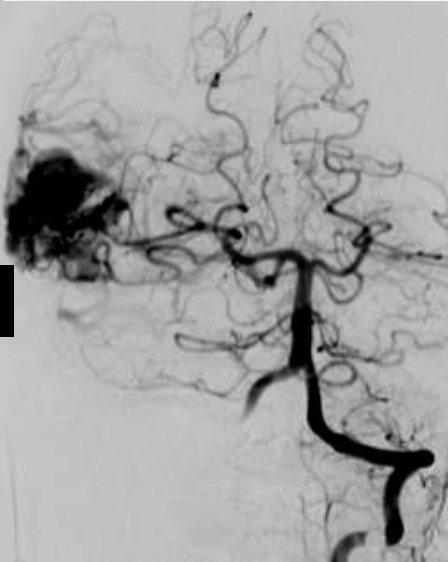




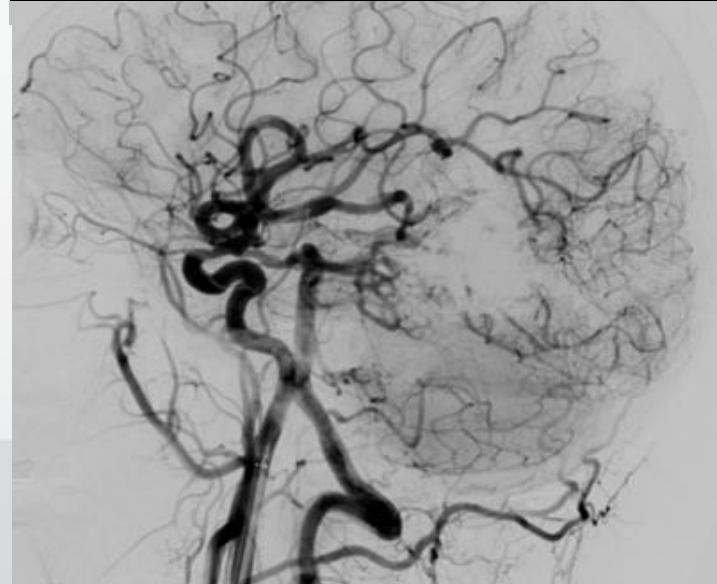




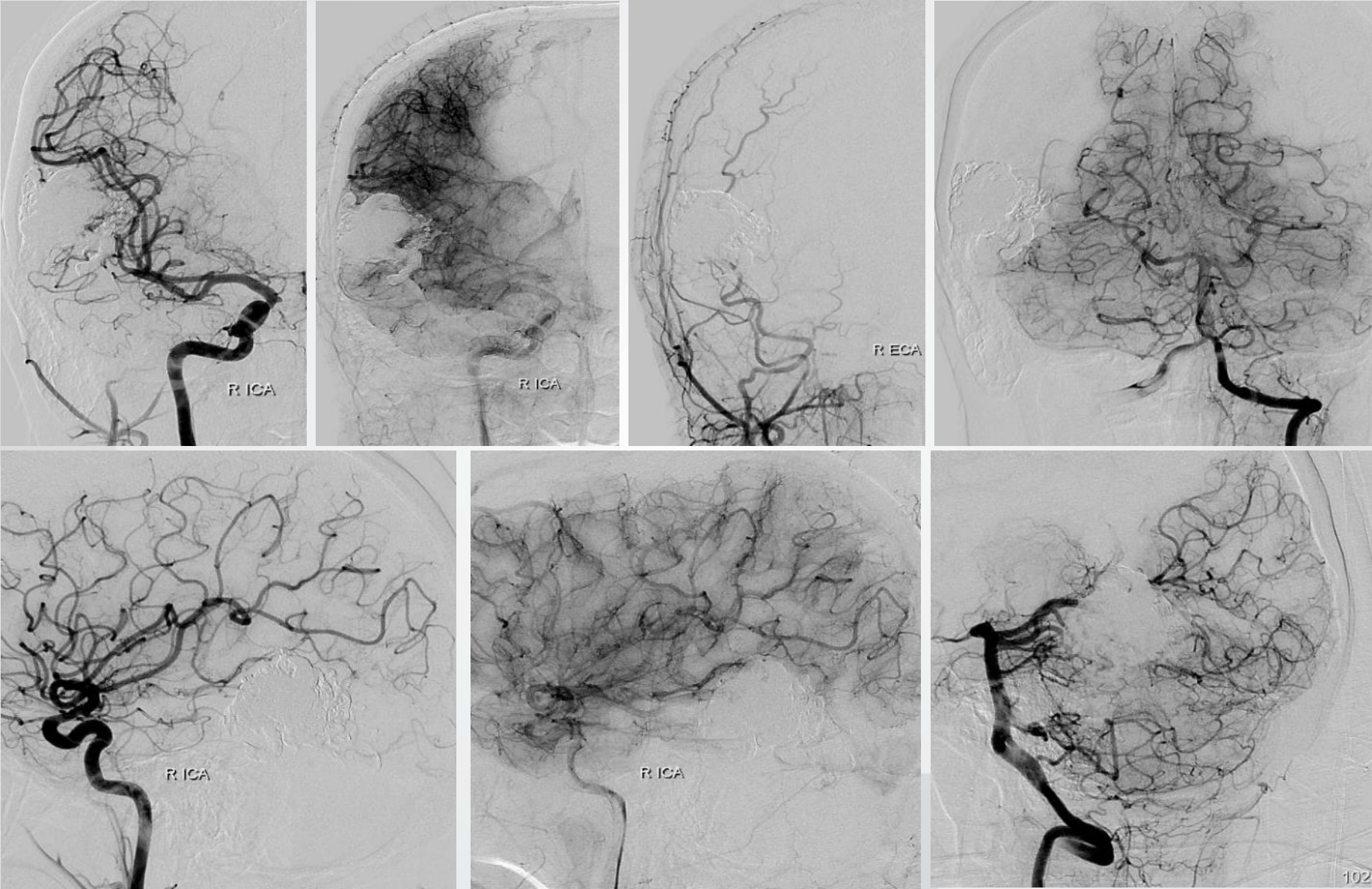
PRE OP



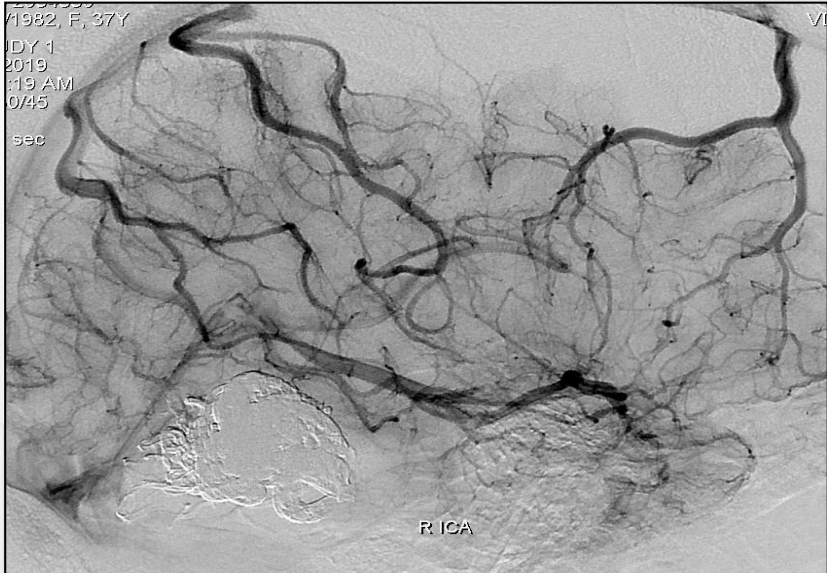
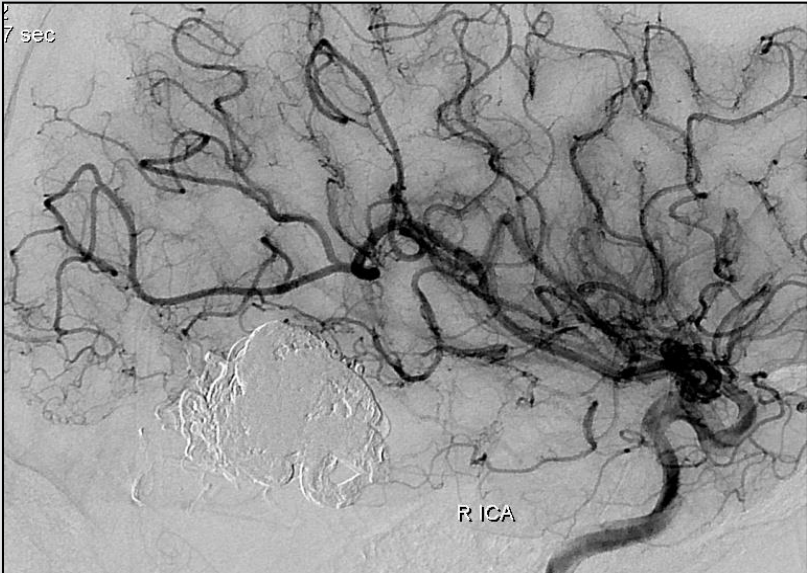
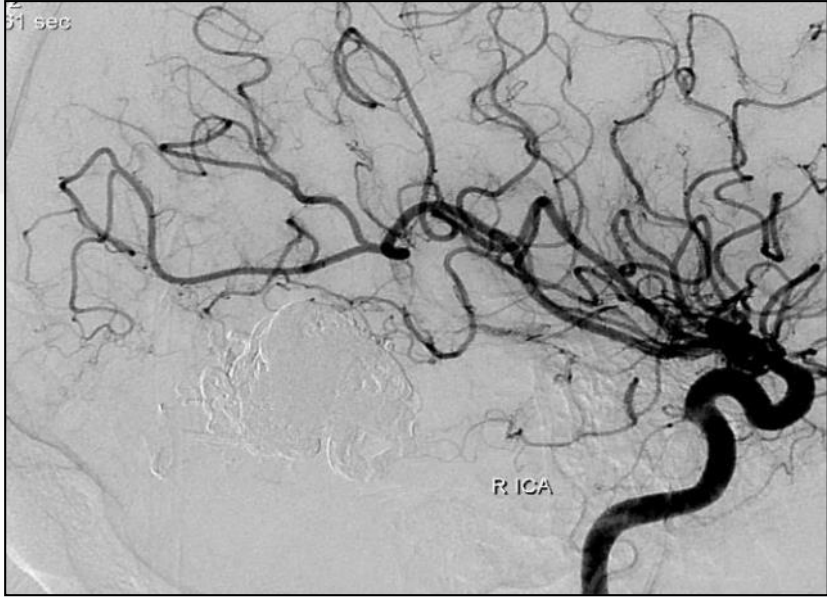
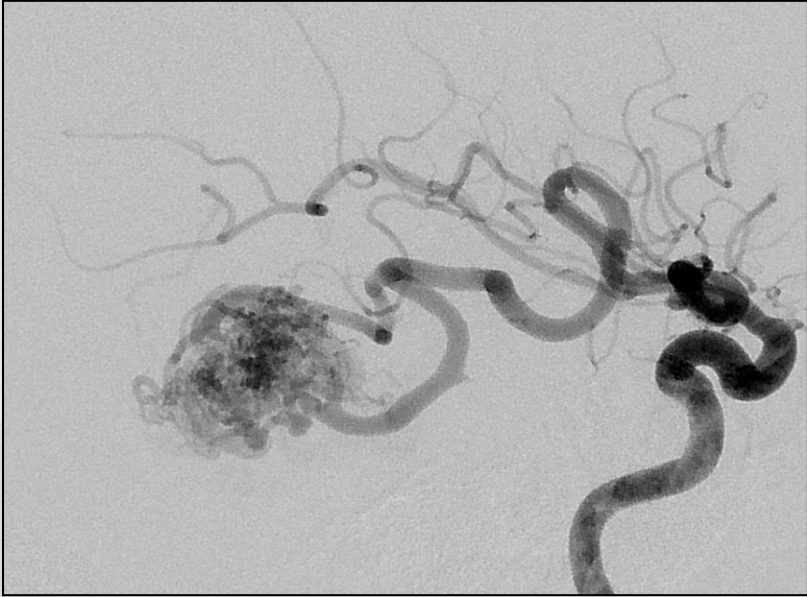
POST OP SIMULTANEOUS R CCA AND LEFT VA



1 YEAR CONTROL



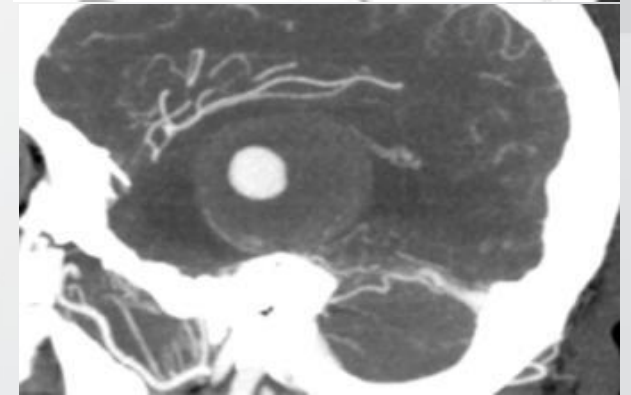
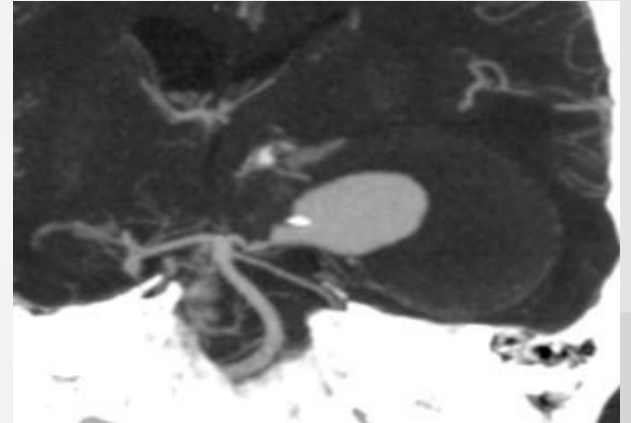
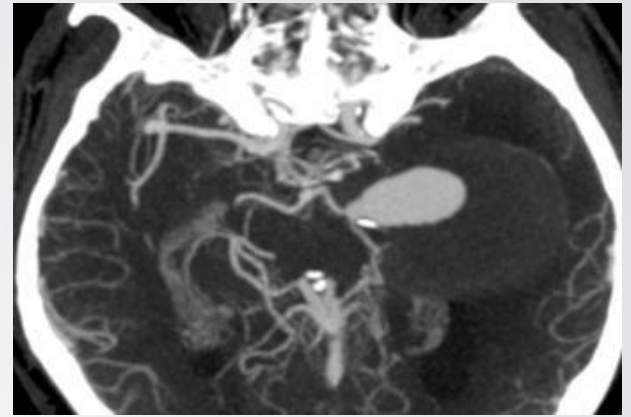
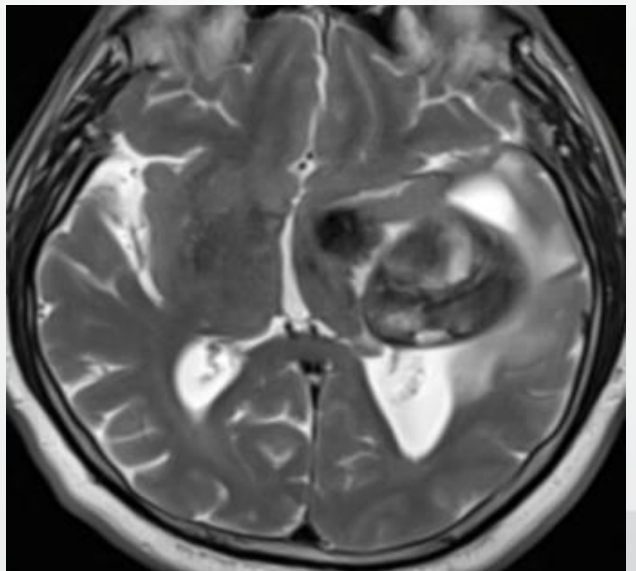
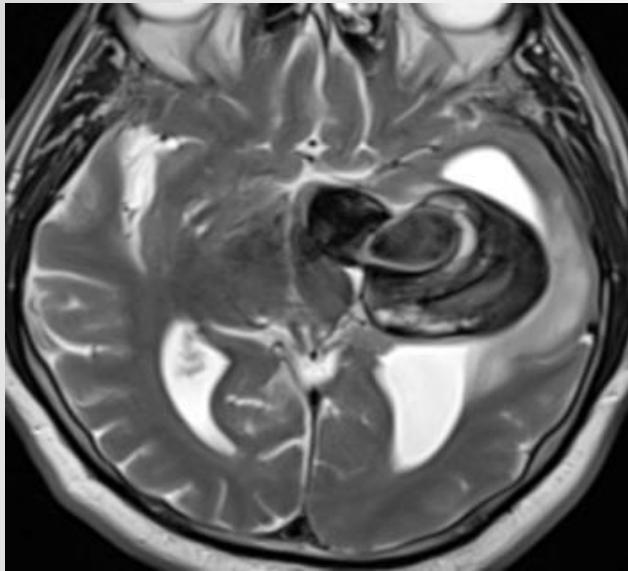
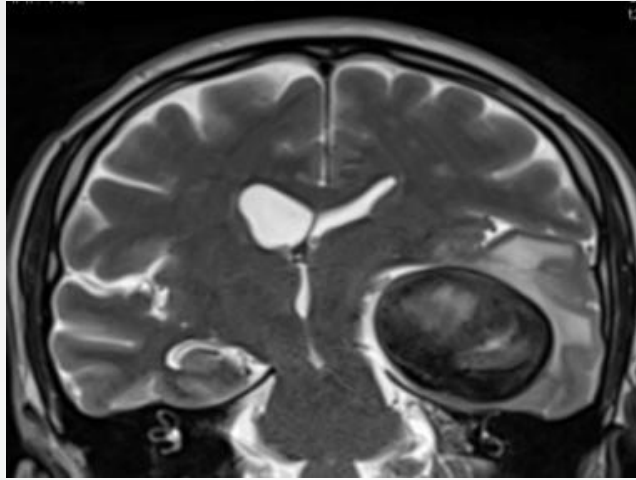
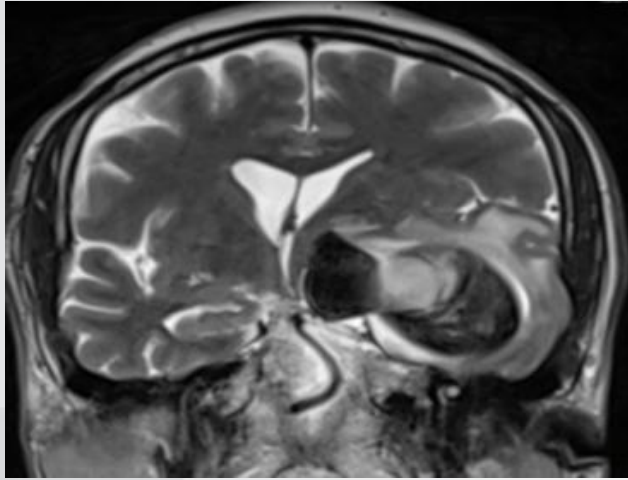
1 YEAR CONTROL

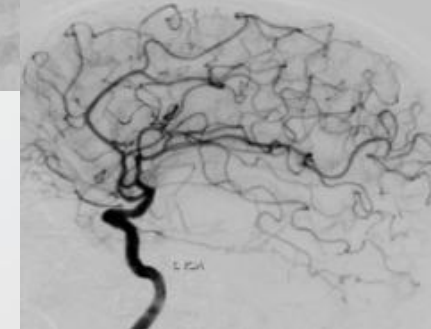
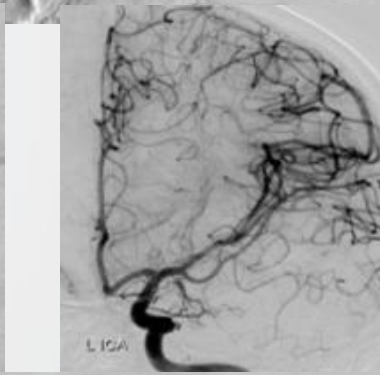
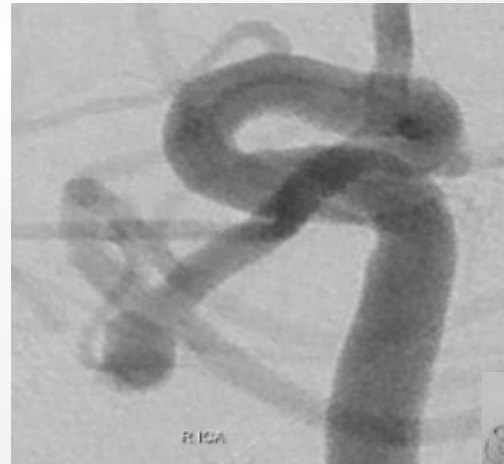
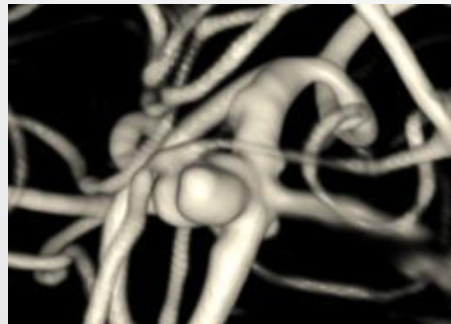
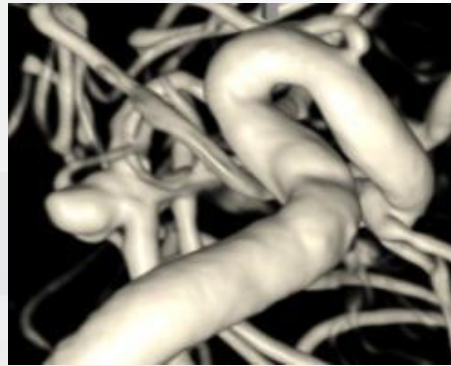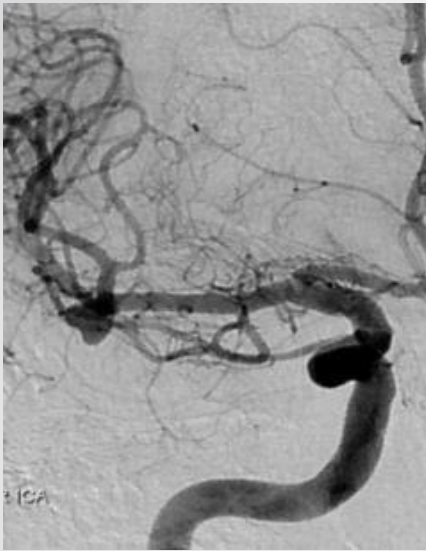
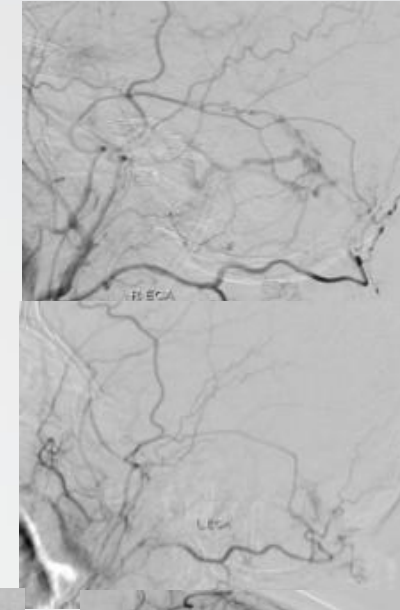
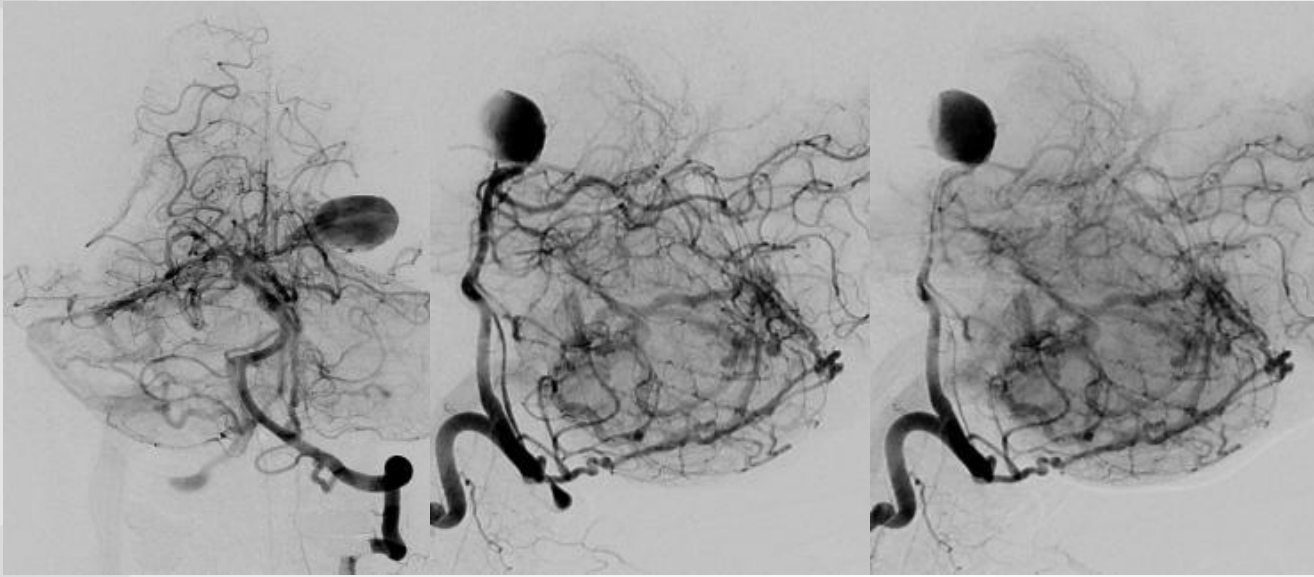


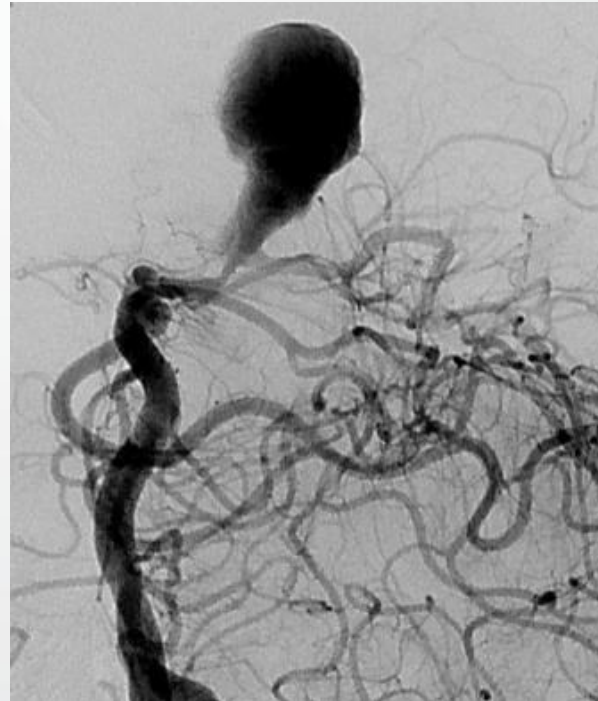
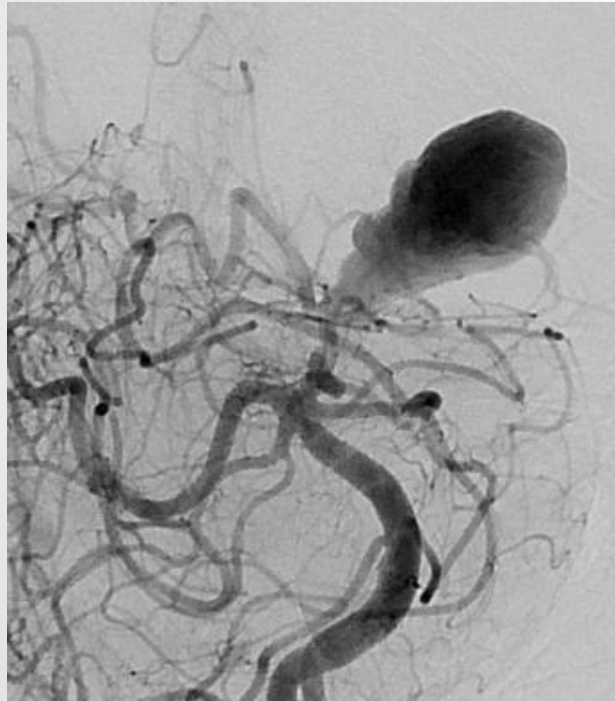
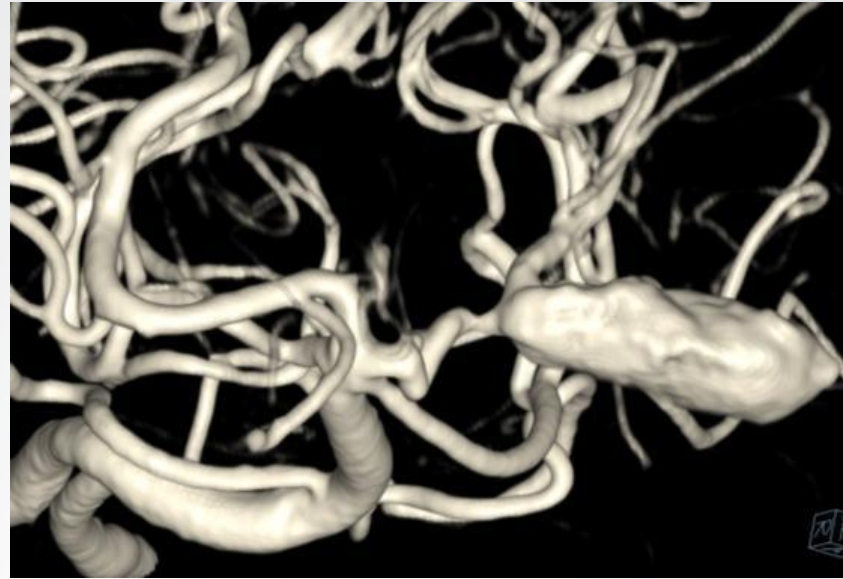
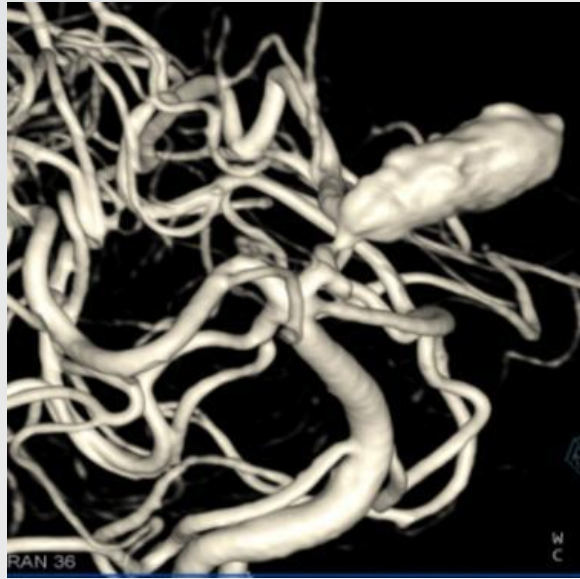
PATIENT 2

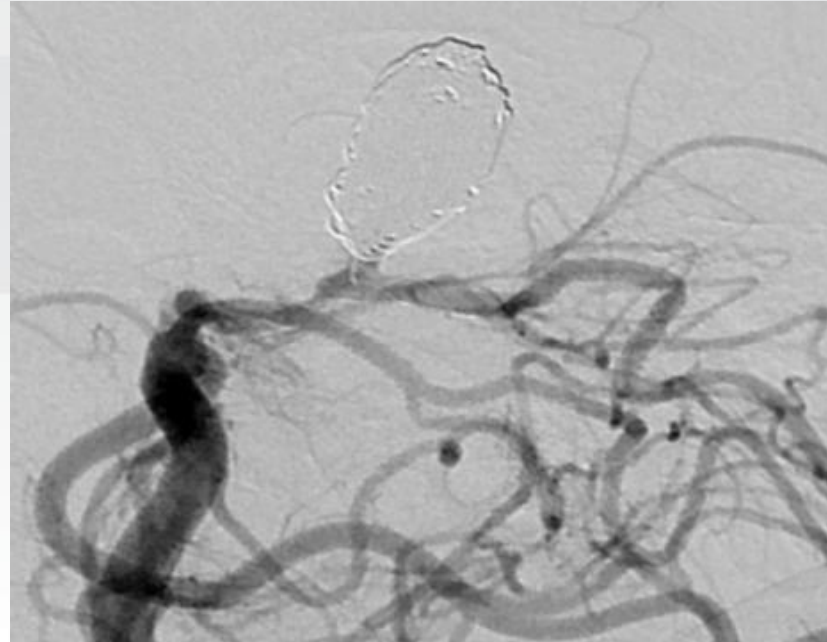
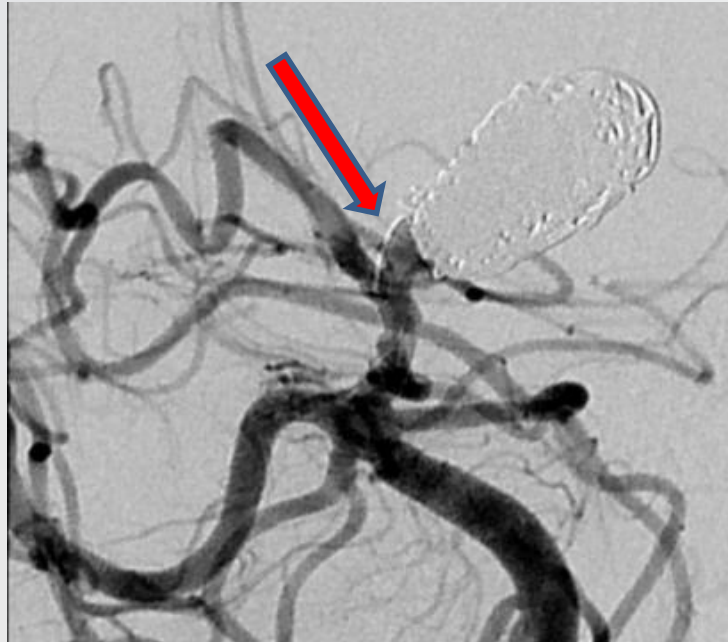
- **58 yo, male**
- Headache and recently increasing memory impairment
- Heavy smoker
- No history of trauma
- ***Giant partially clotted P1-P2 PCA aneurysm***
- ***R MCA saccular aneurysm***
- ***Dural AVF***



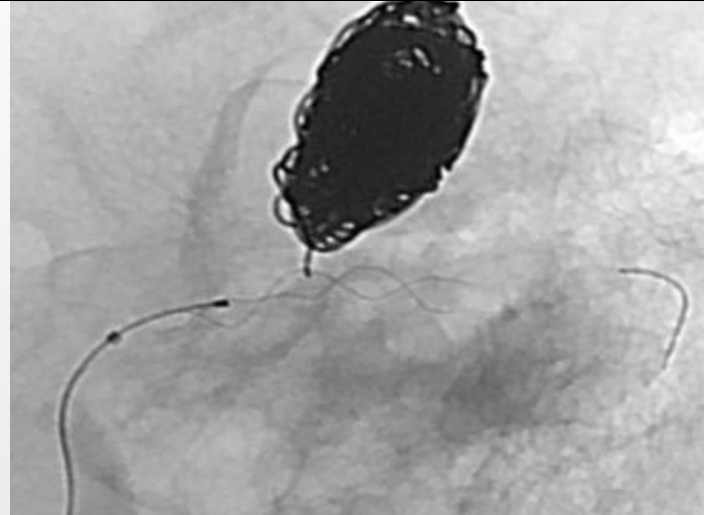
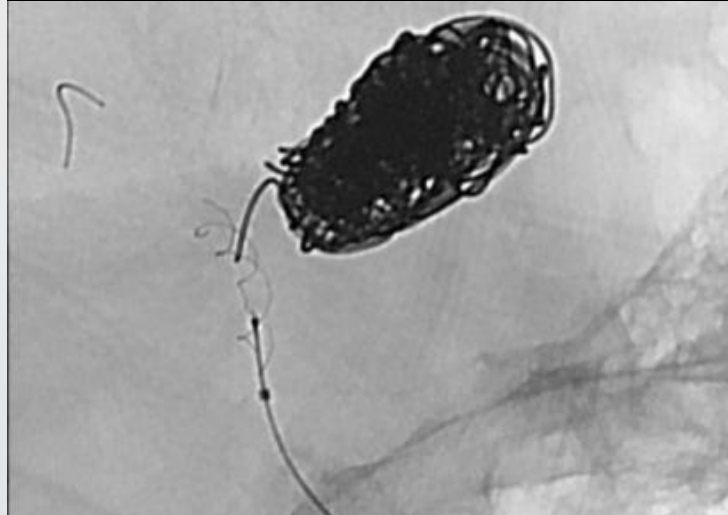


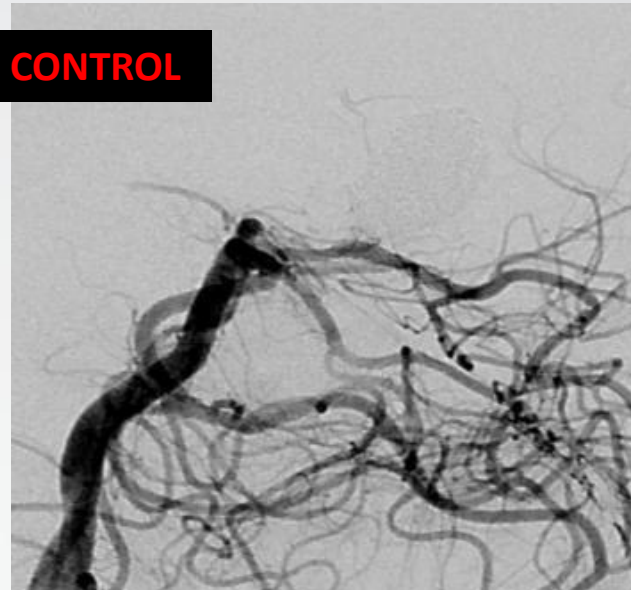
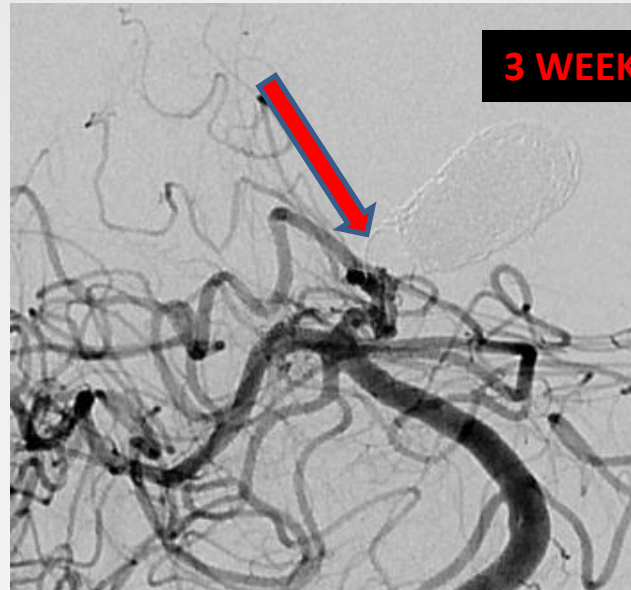
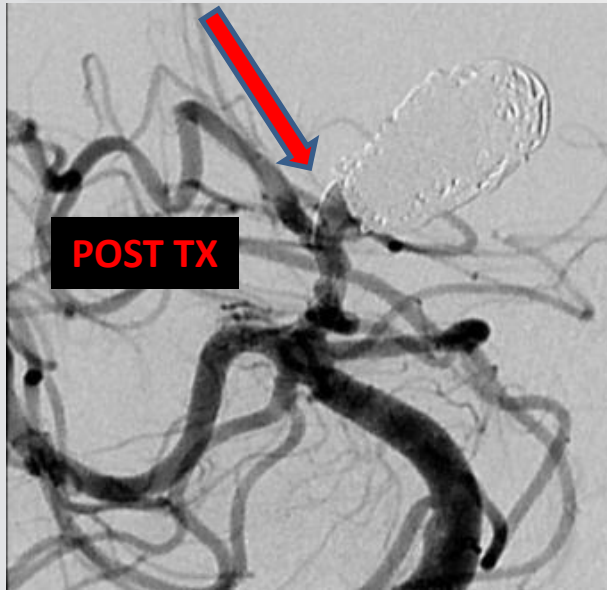




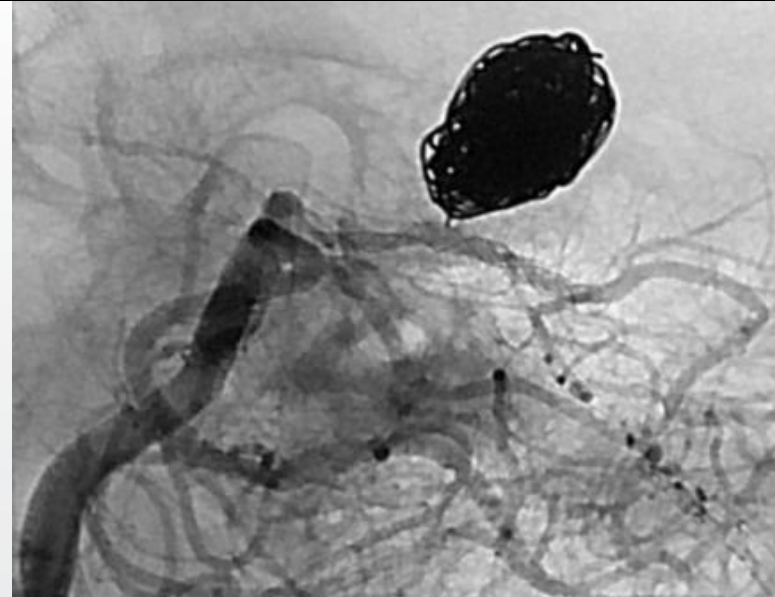
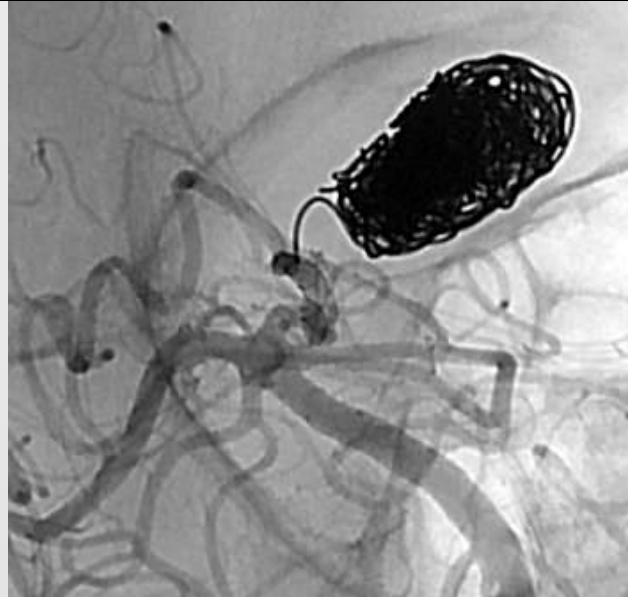


**POST TREATMENT AFTER COILING AND LEO BABY PLACEMENT ACCROSS THE NECK:
PLEASE NOTE THAT A NECK REMNANT WAS LEFT (ARROW)**

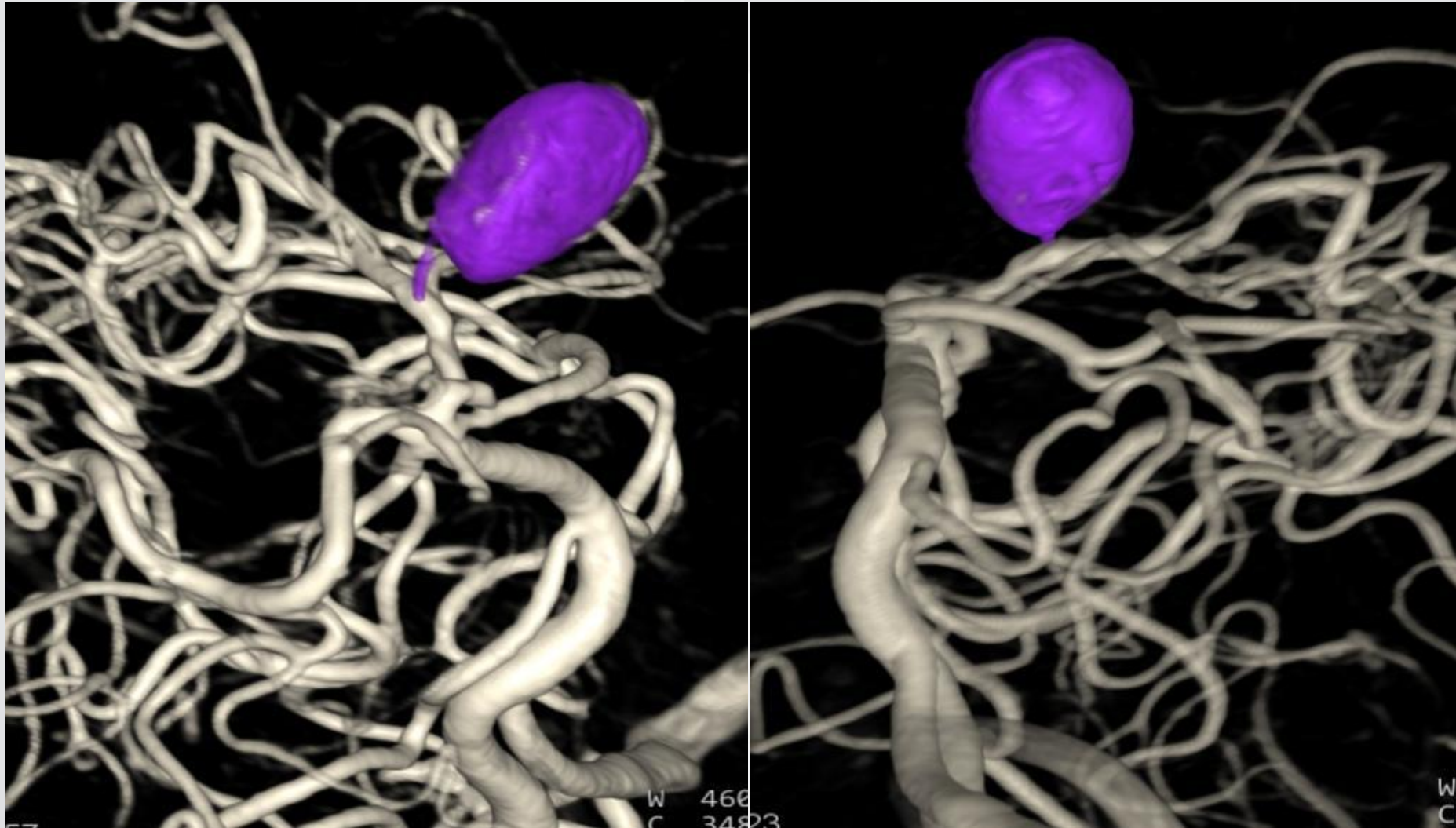


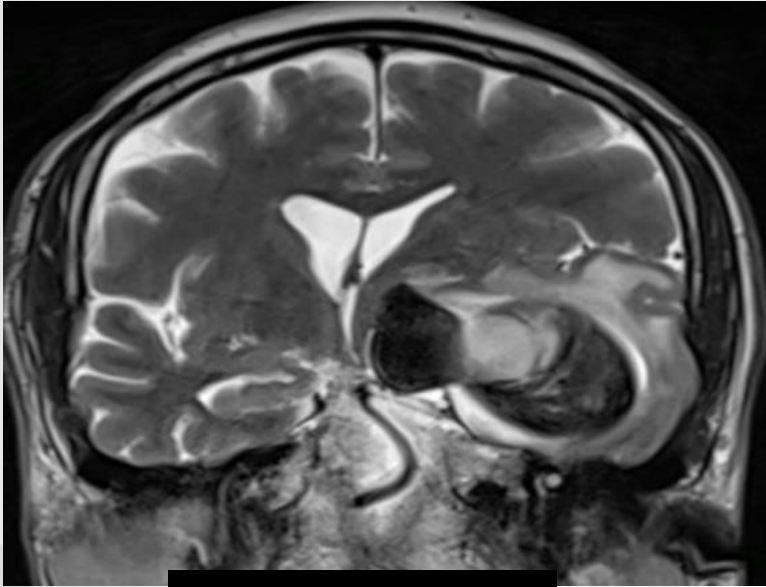


3 WEEKS CONTROL TAKEN DURING THE R MCA ANEURYSM : NOTE THAT A NECK REMNANT WAS NOT FILLING ANYMORE WITH COMPLETE ANGIOGRAPHIC OCCLUSION (ARROW)

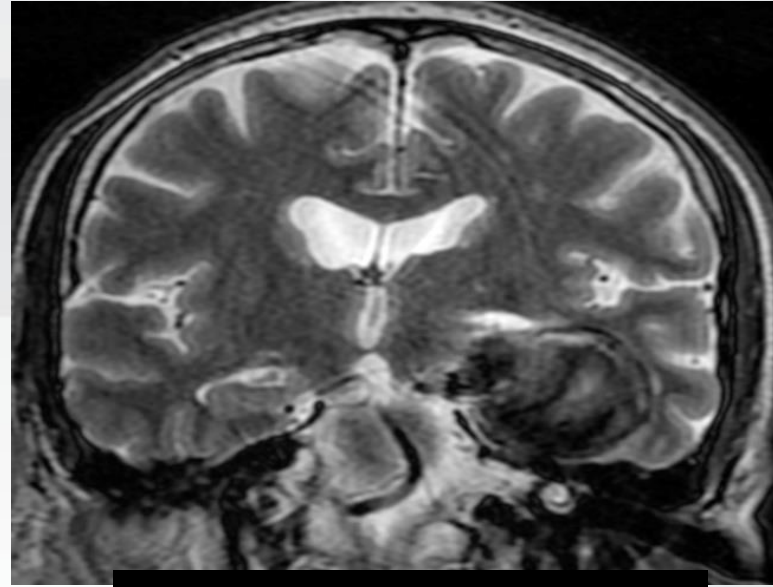


3 WEEKS CONTROL; 3D DUAL VOLUME RECONSTRUCTION

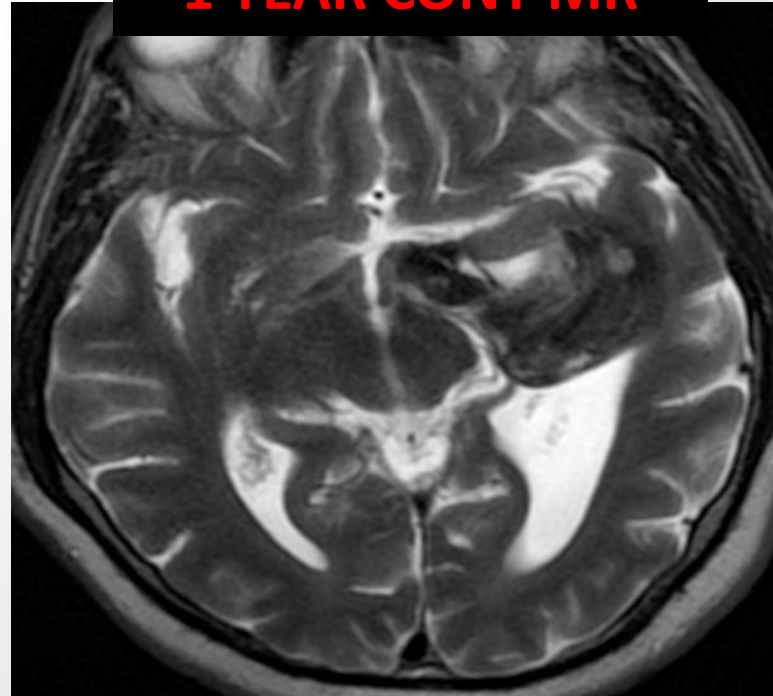
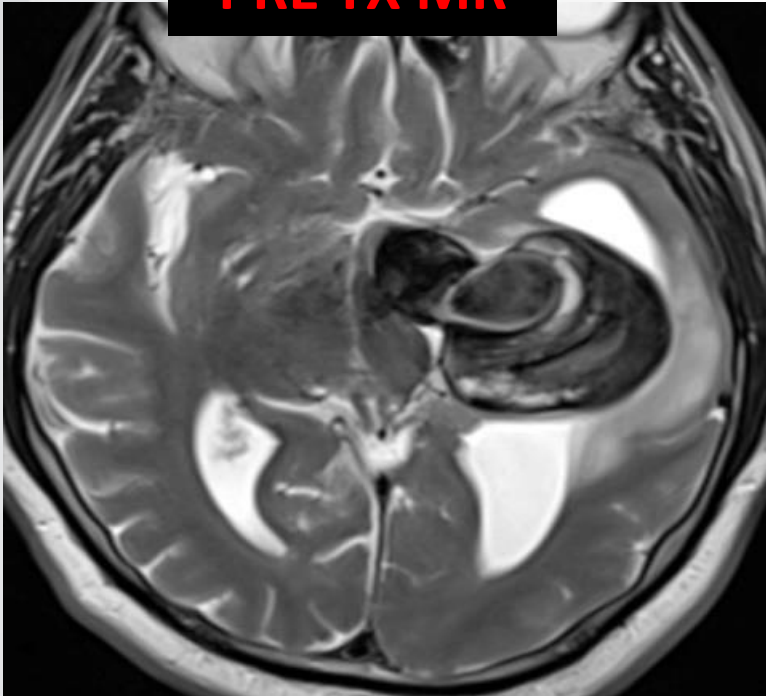




PRE TX MR



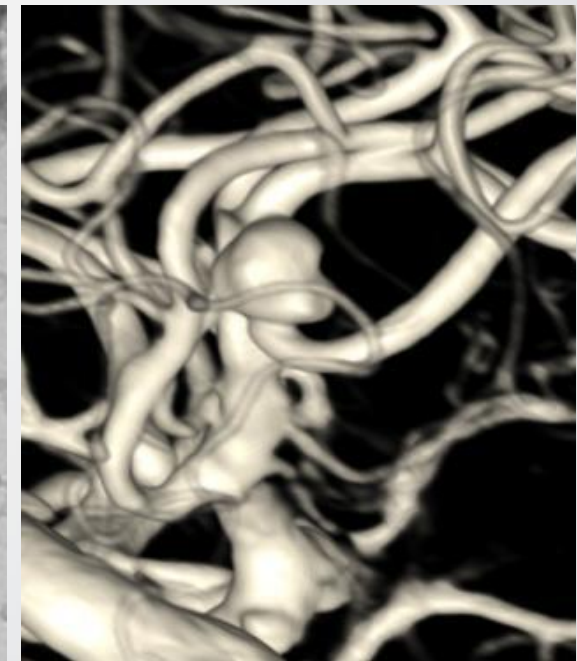
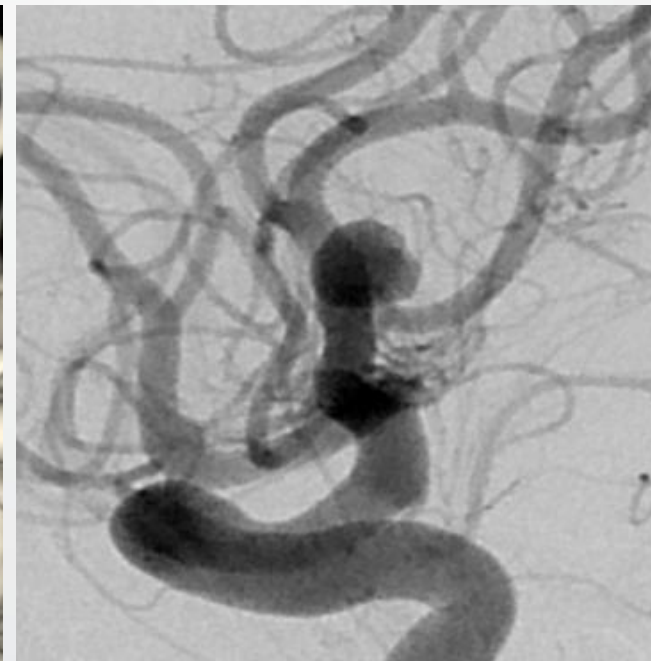
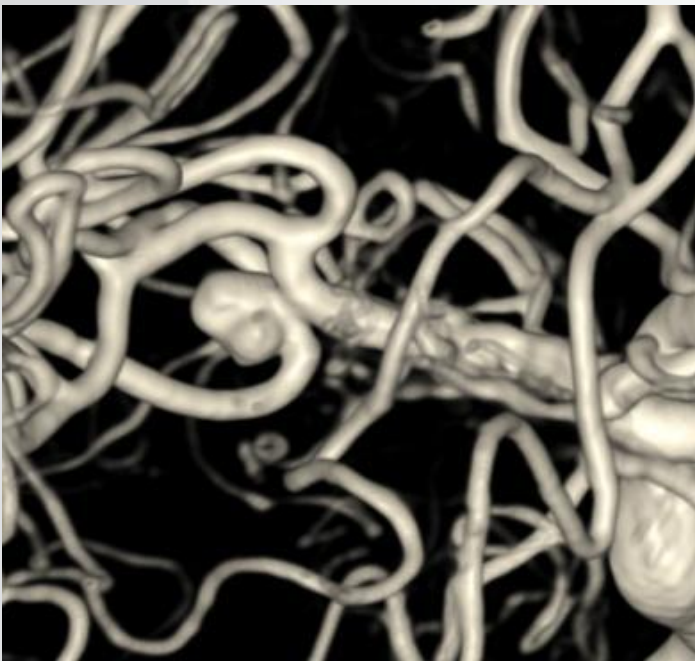
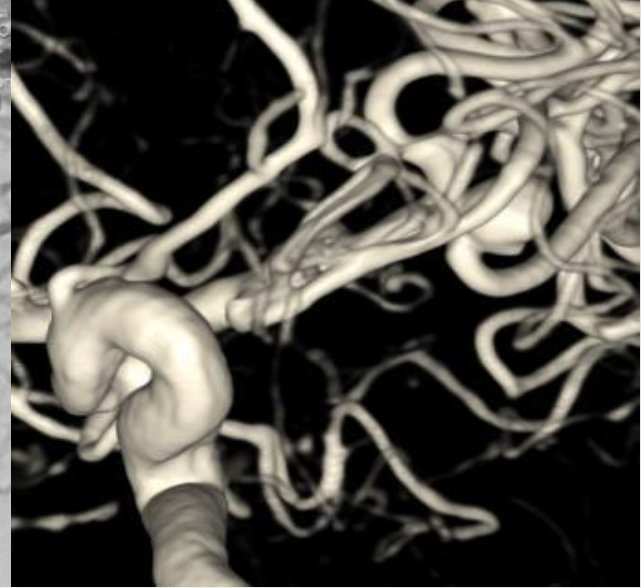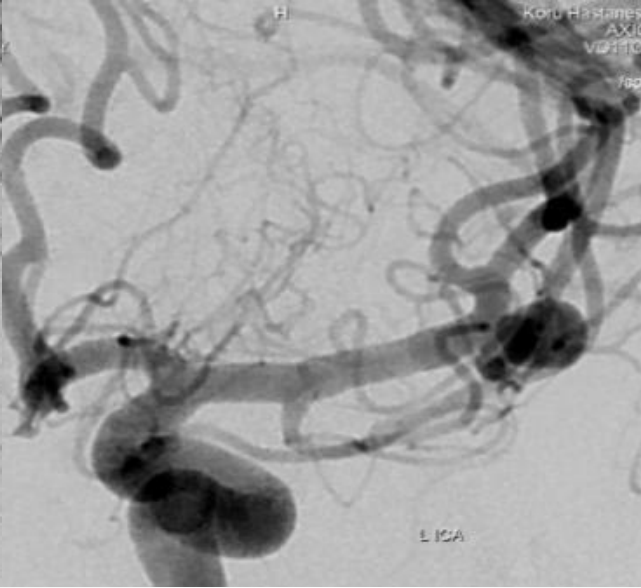
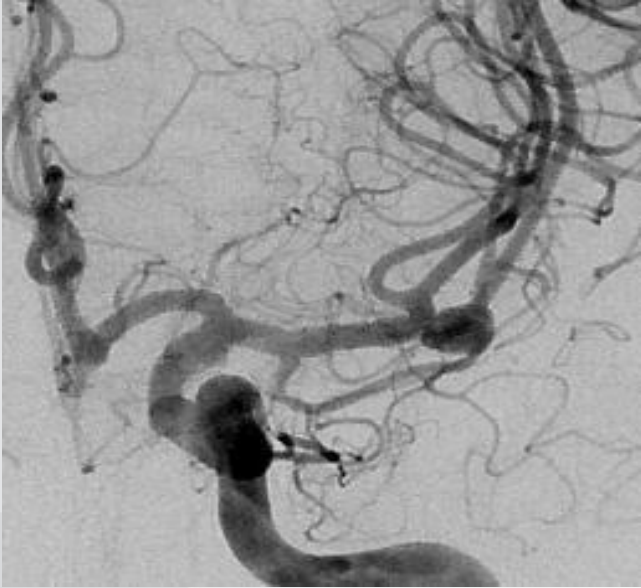
1 YEAR CONT MR

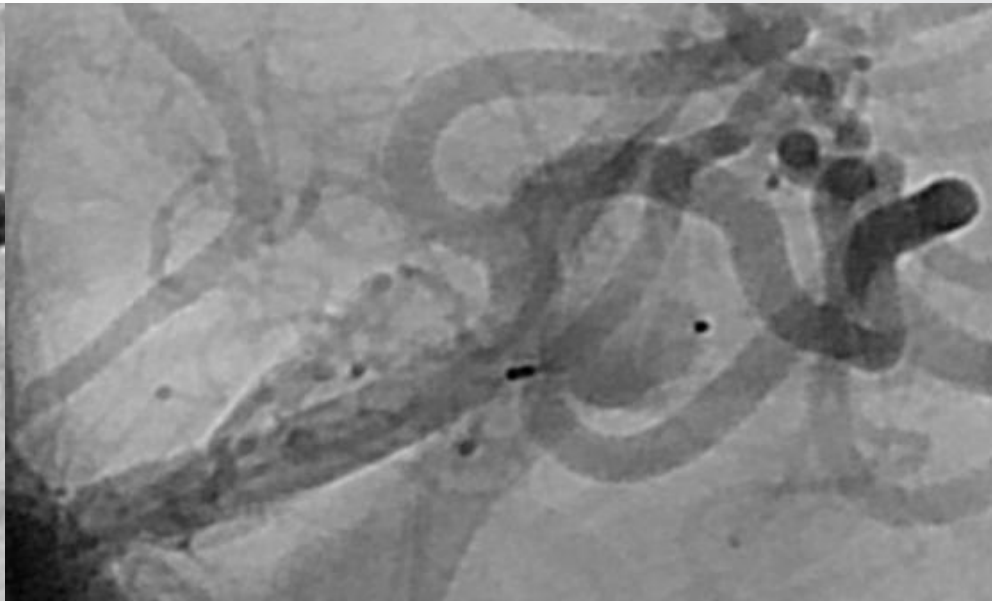
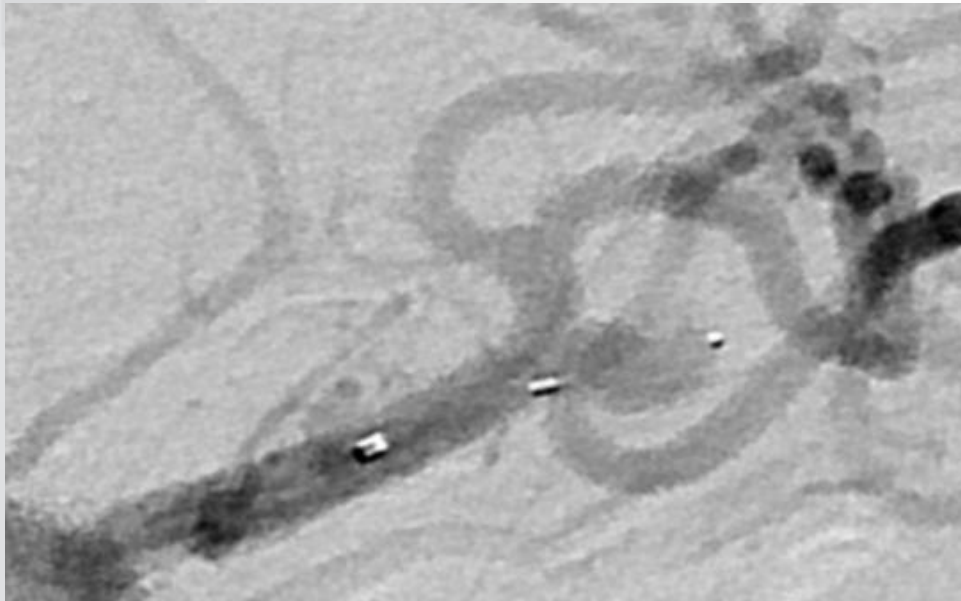
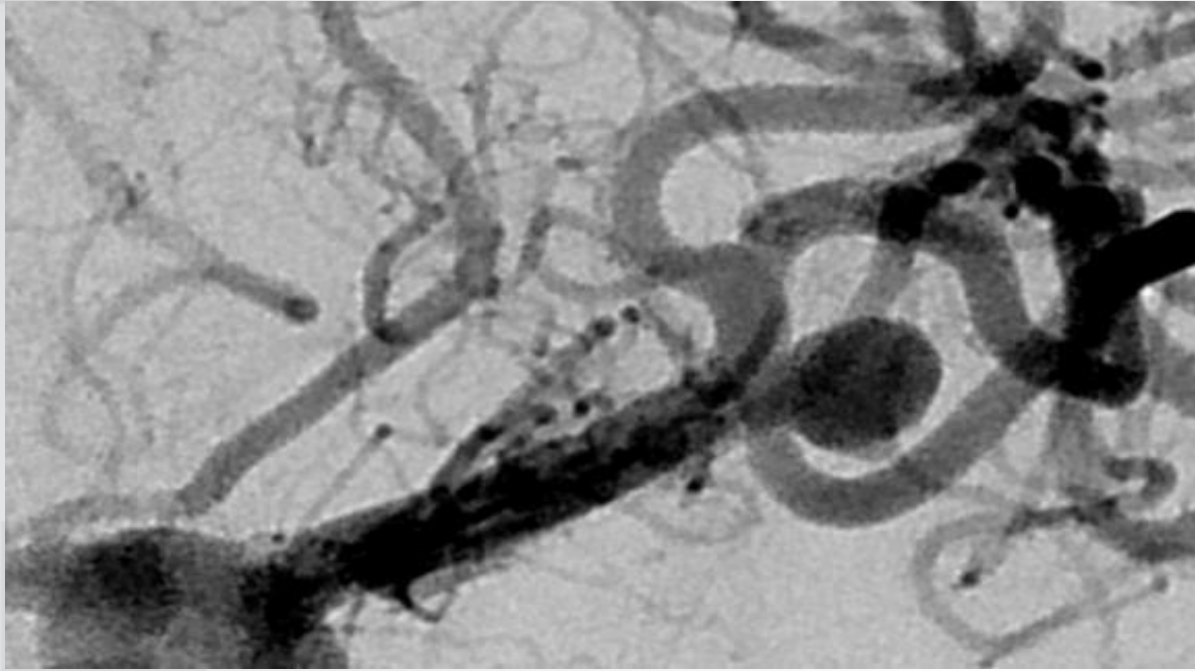


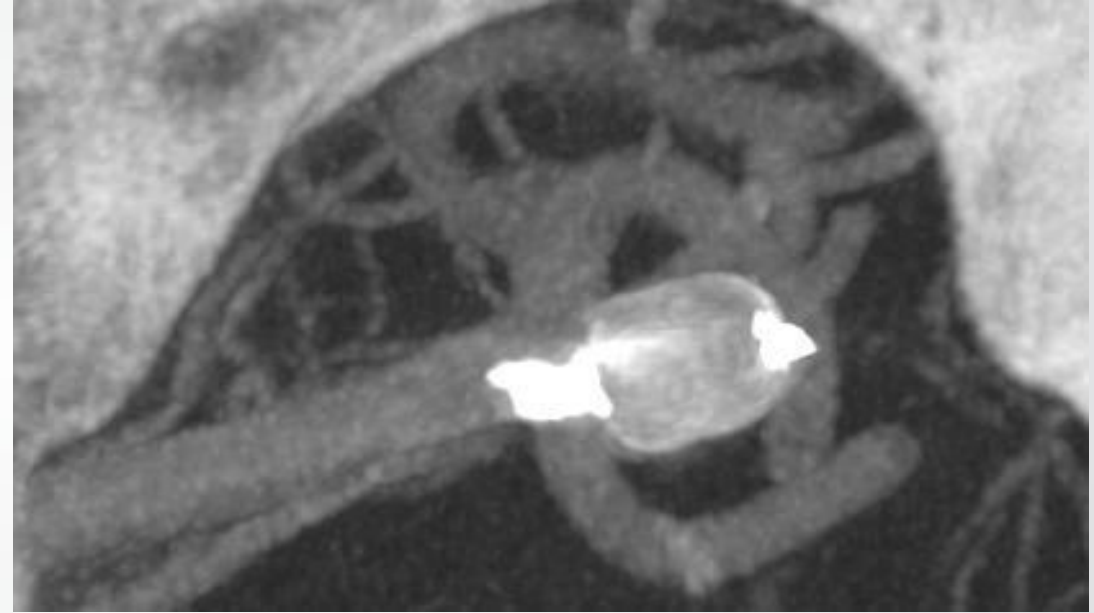
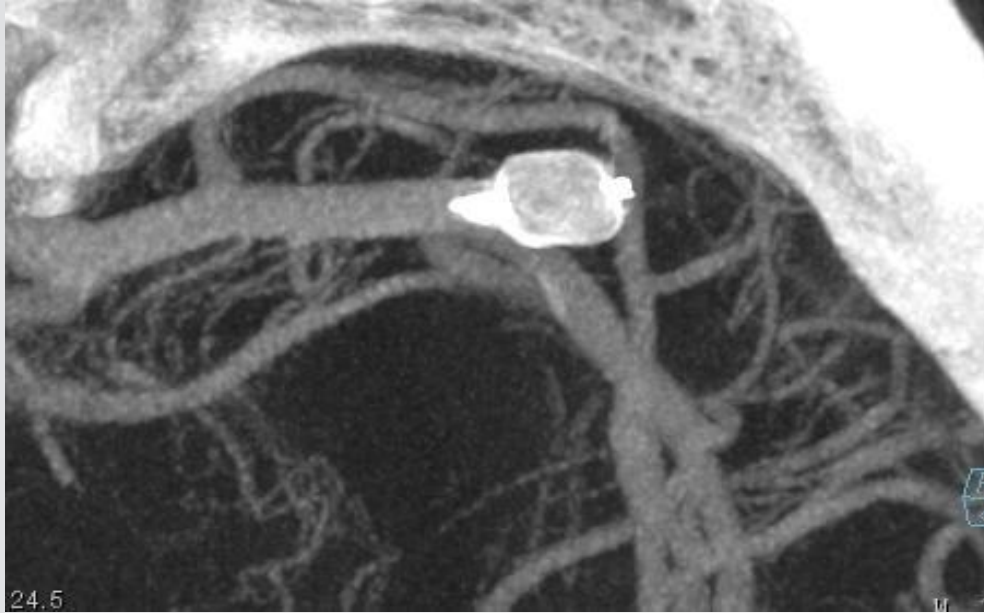
PATIENT 3

- **49 yo, male**
- Very intense headache 4 weeks ago.
- R MCA aneurysms with bleb
- Treated with WEB device...

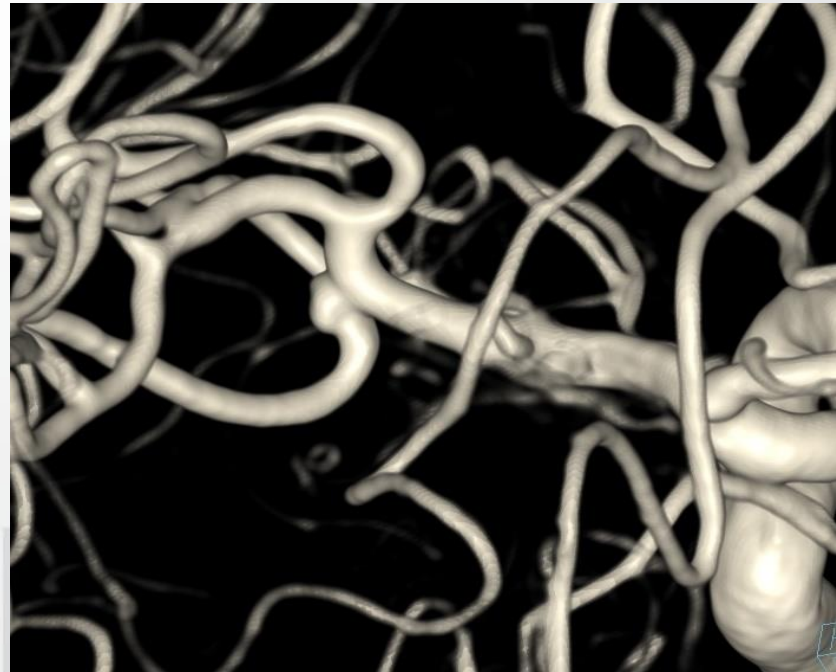
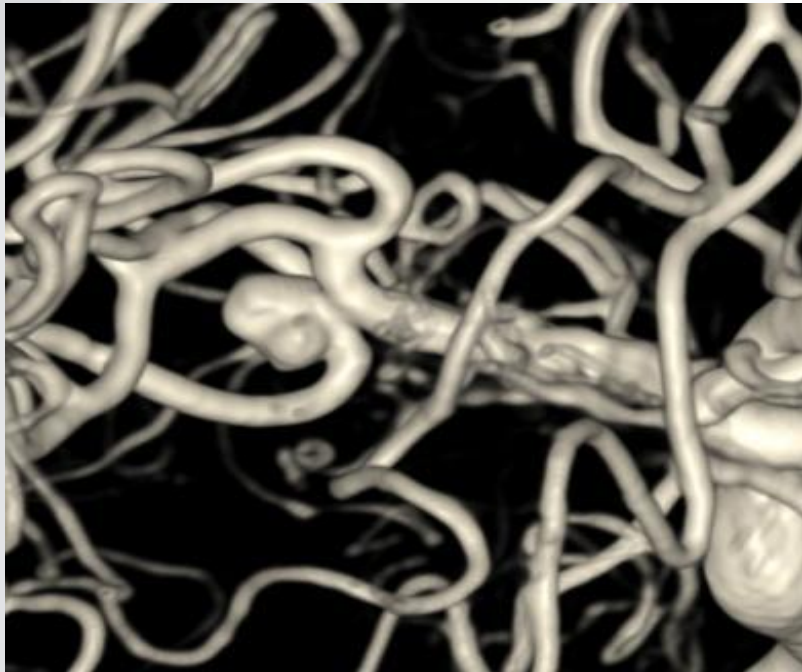
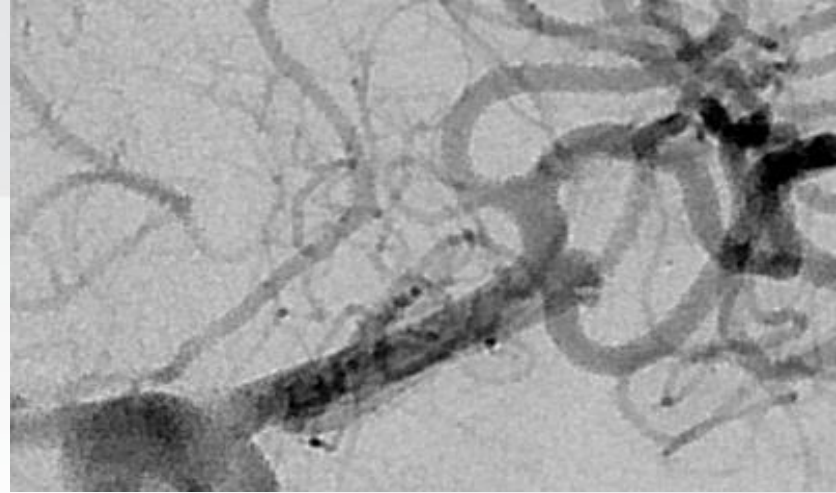
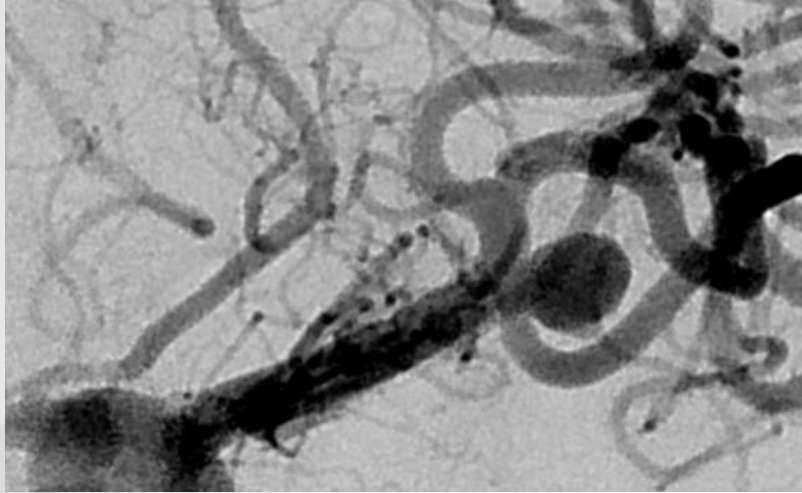








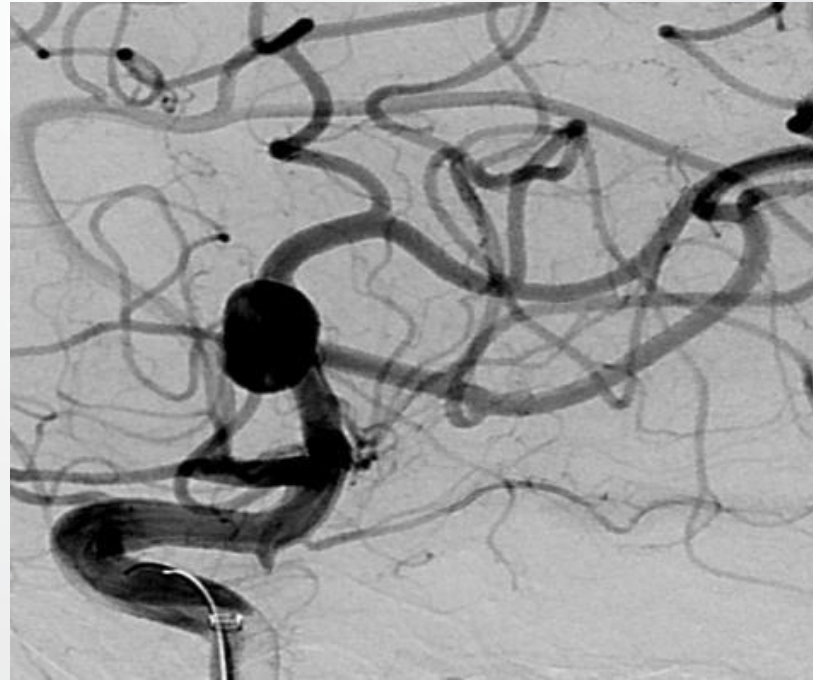
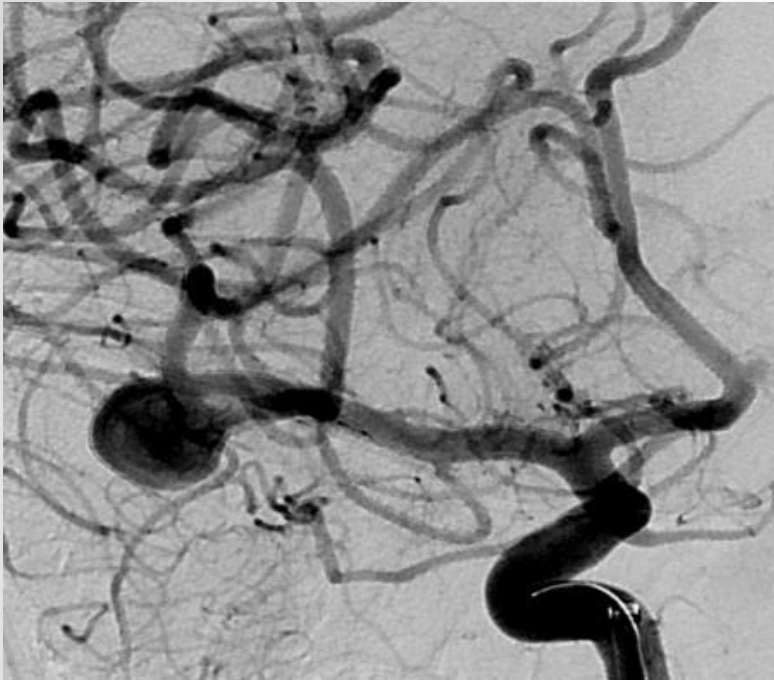
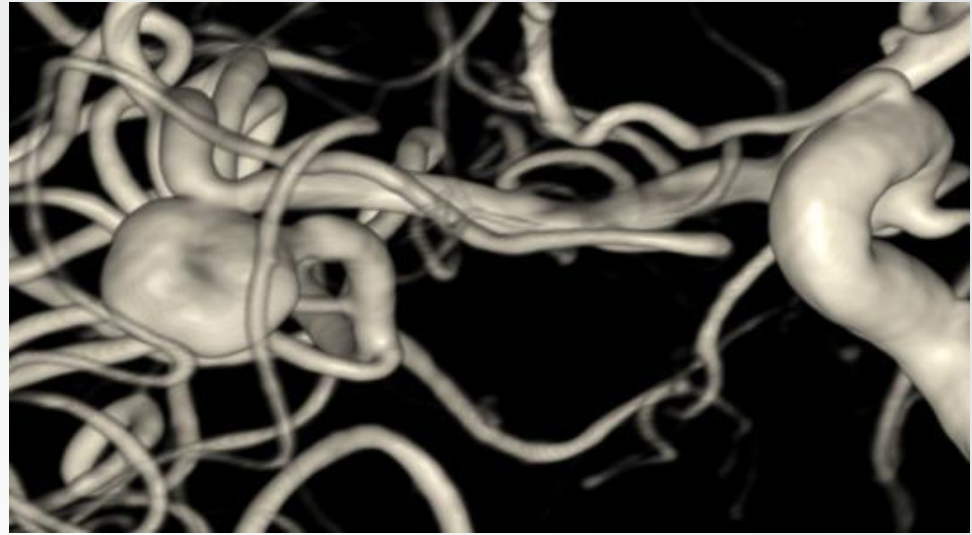
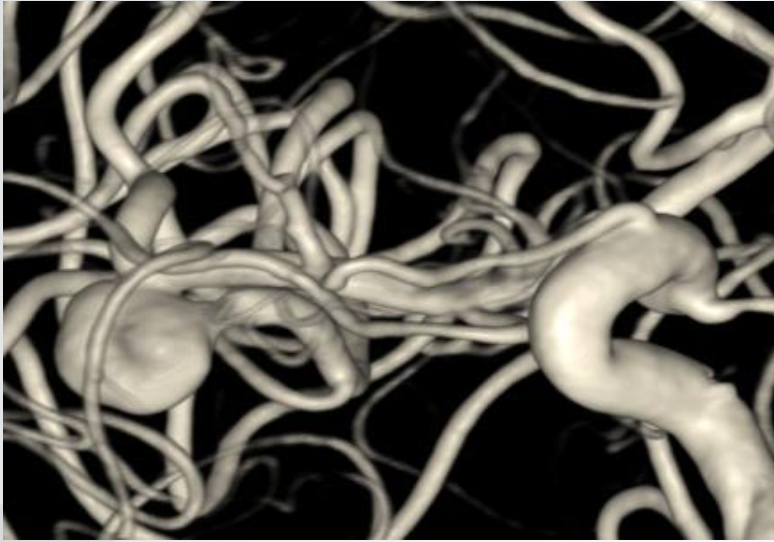
6 MONTHS CONTROL

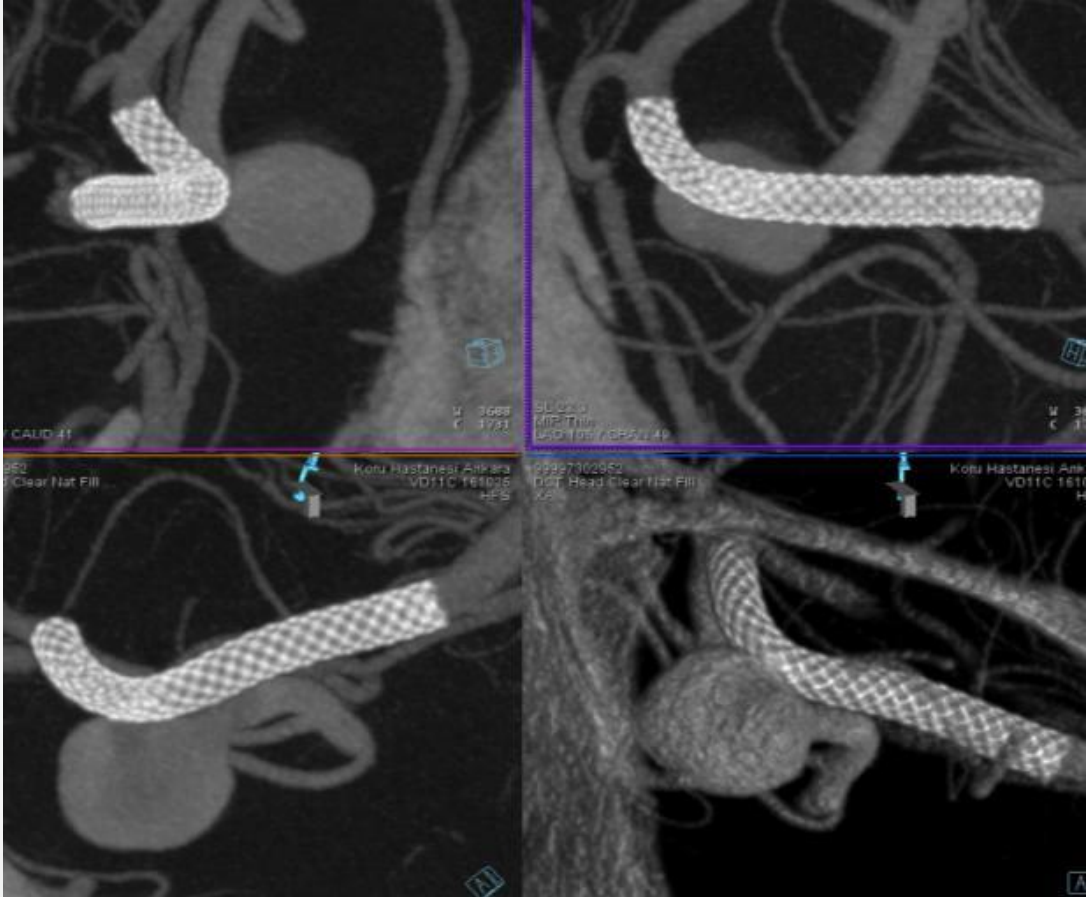
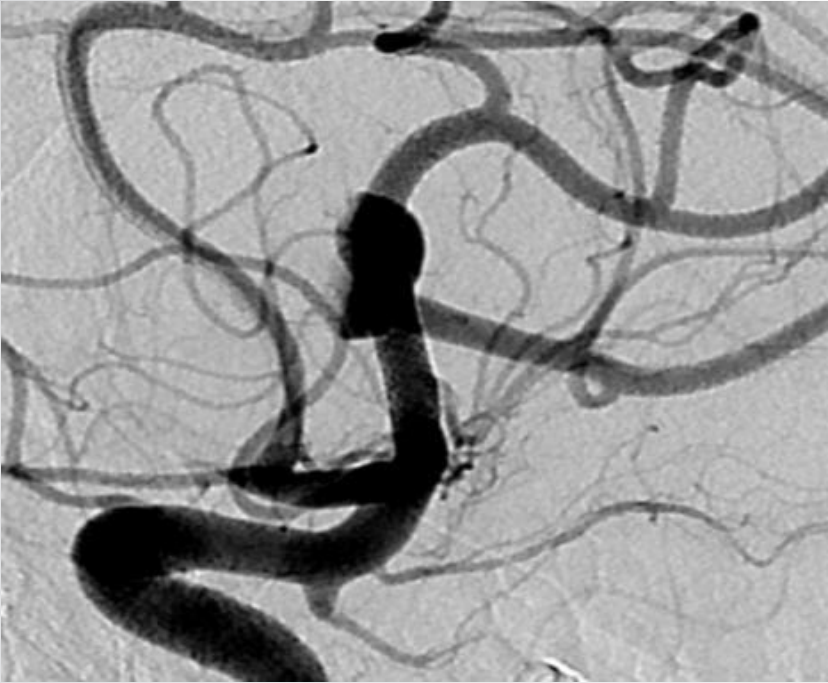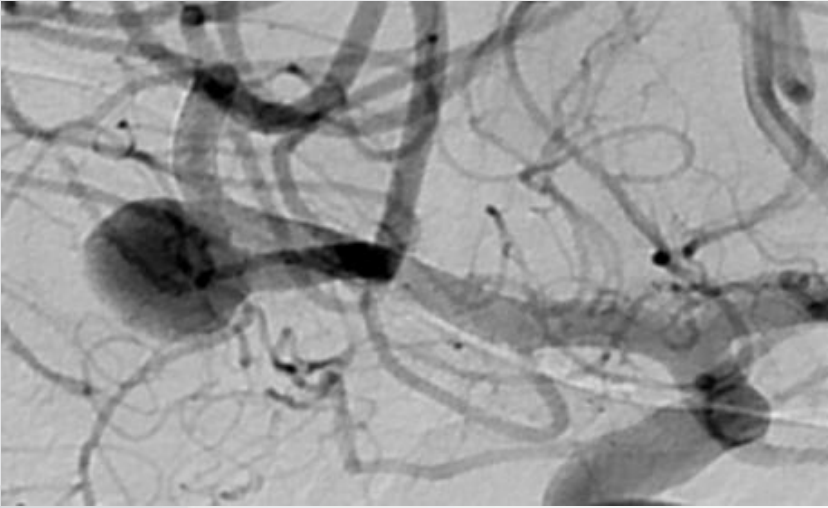


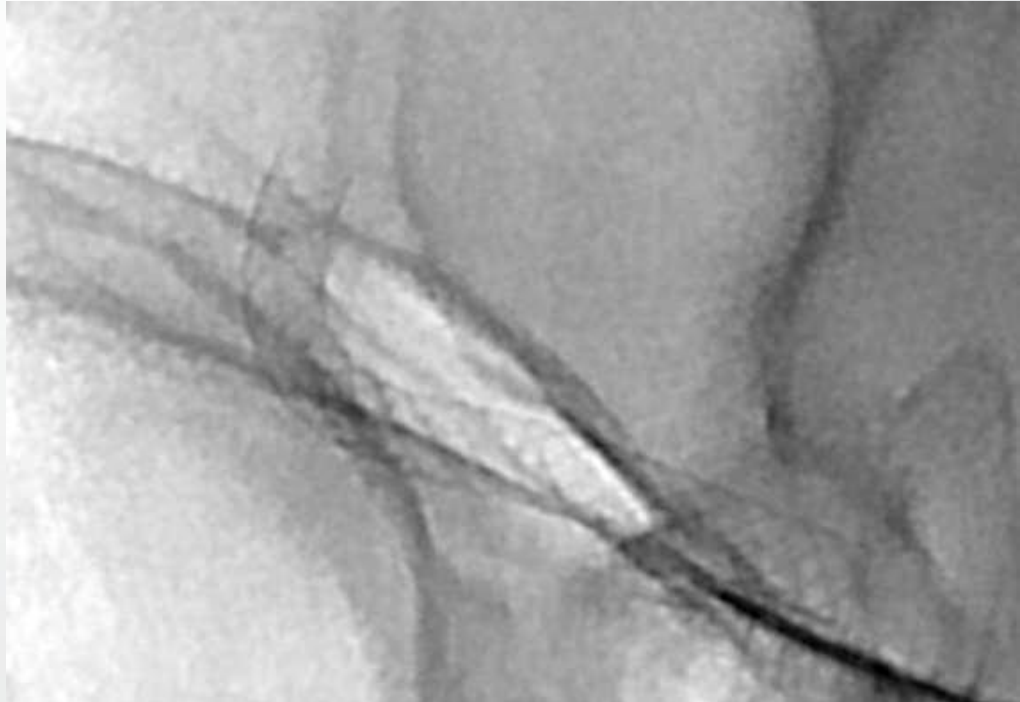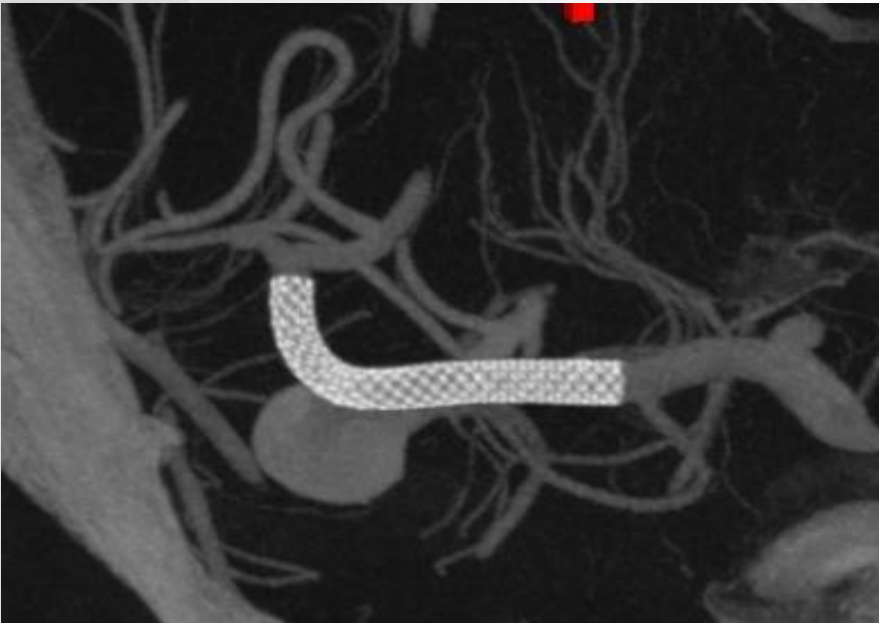
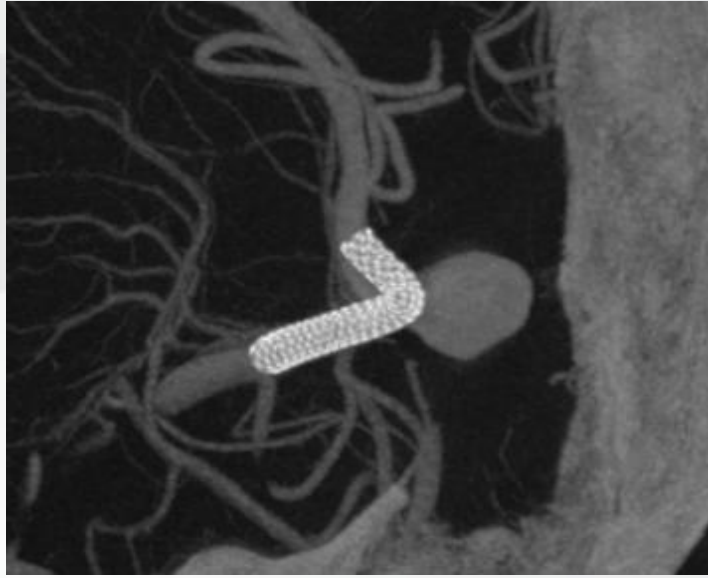
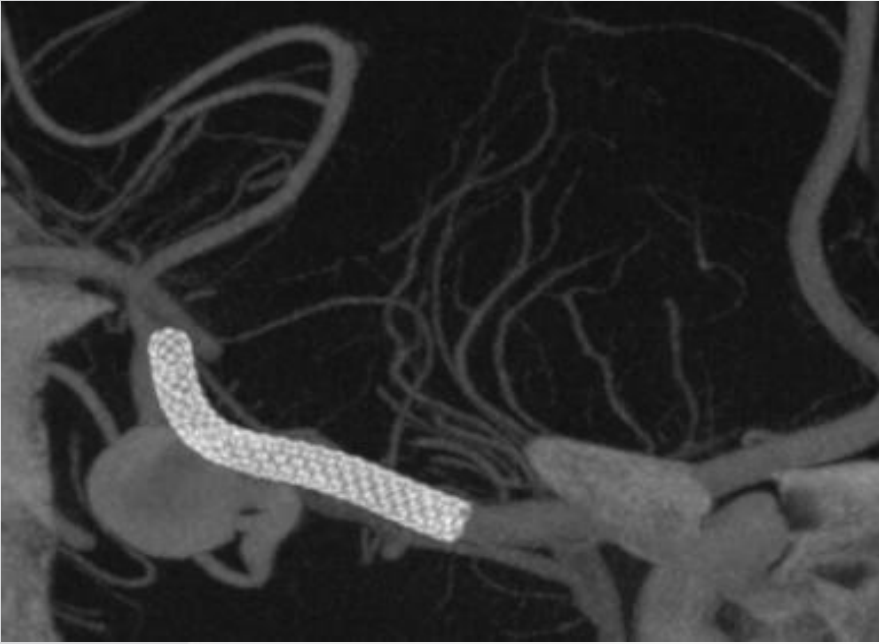
PATIENT 4

- **72 yo, female**
- Severe headache , recently worsened
- ***R MCA saccular aneurysm treated with PIPELINE***

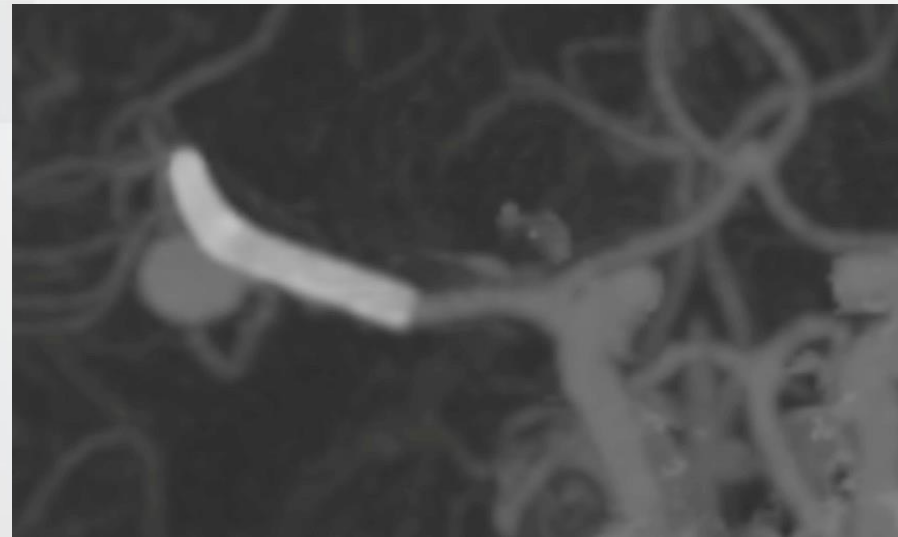
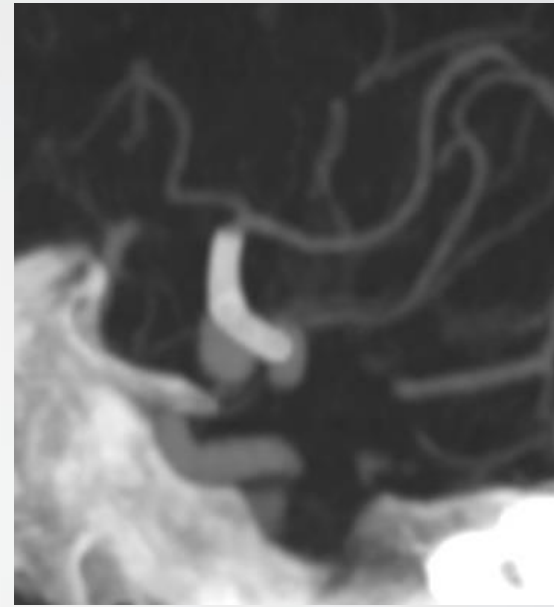
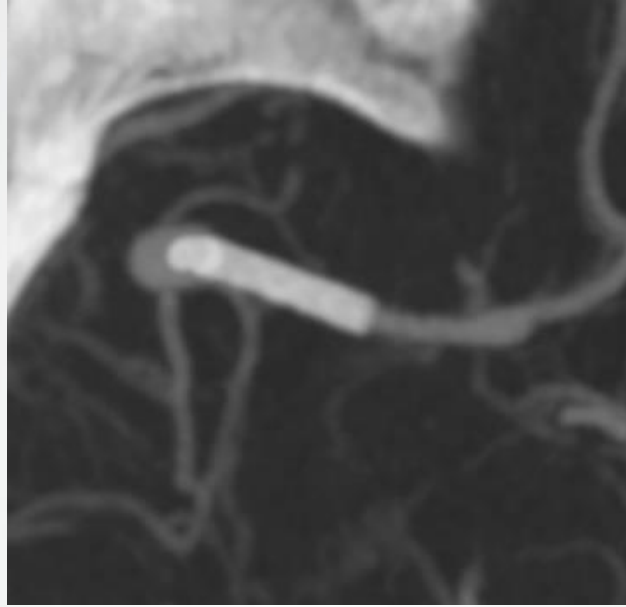
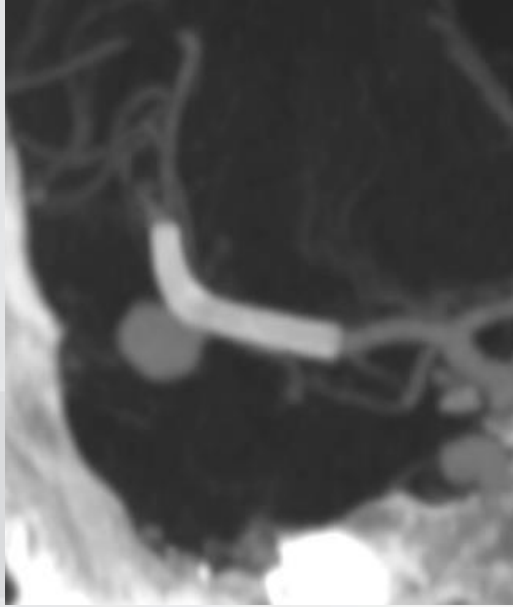


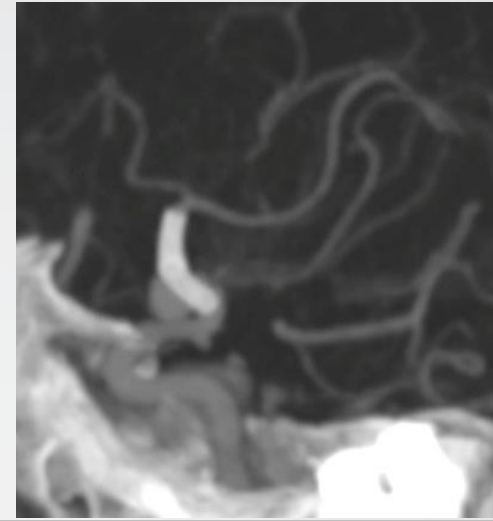
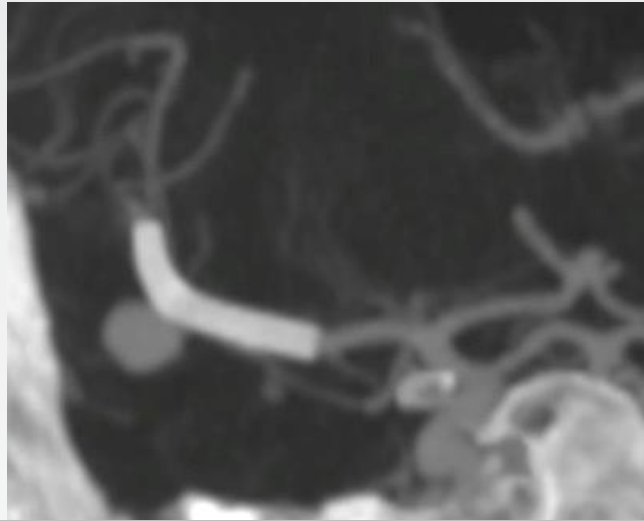
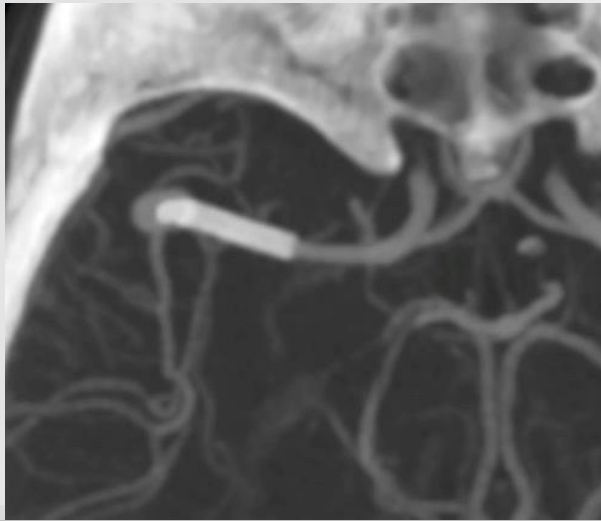




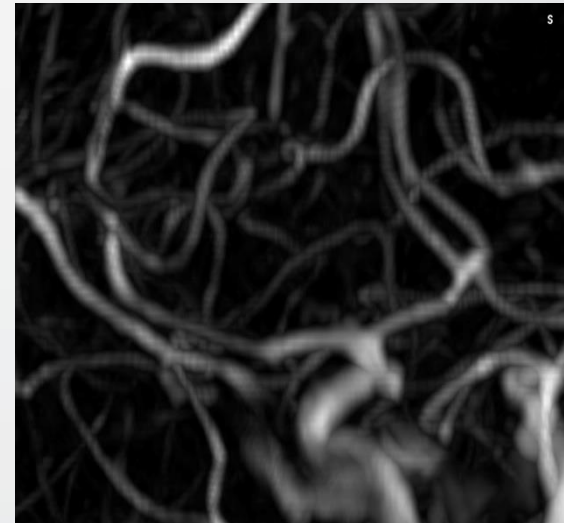
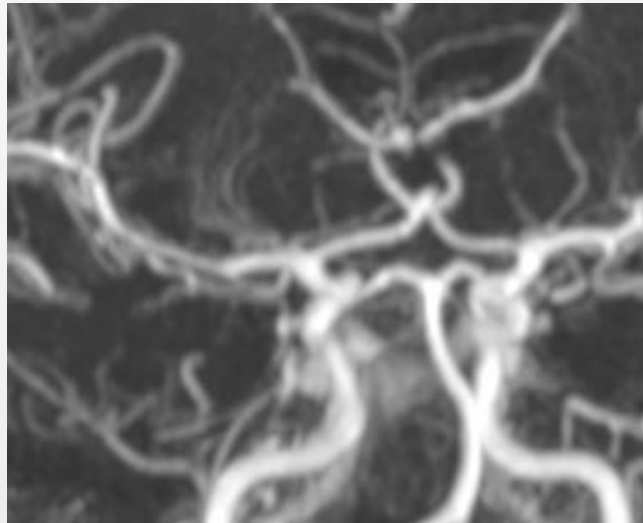
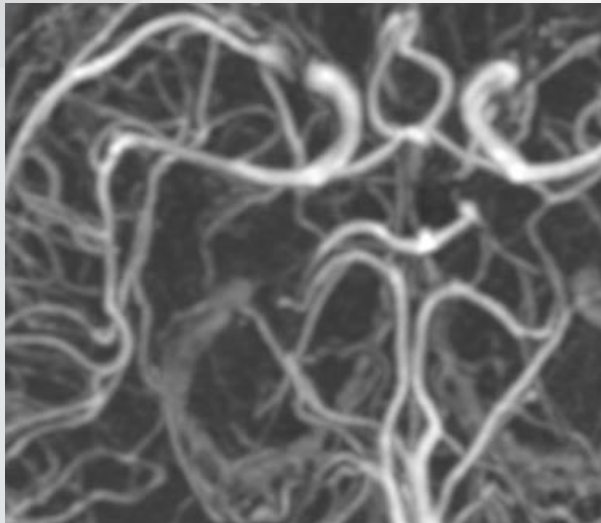


6 MONTHS CONTROL, PRASUGREL STOPPED



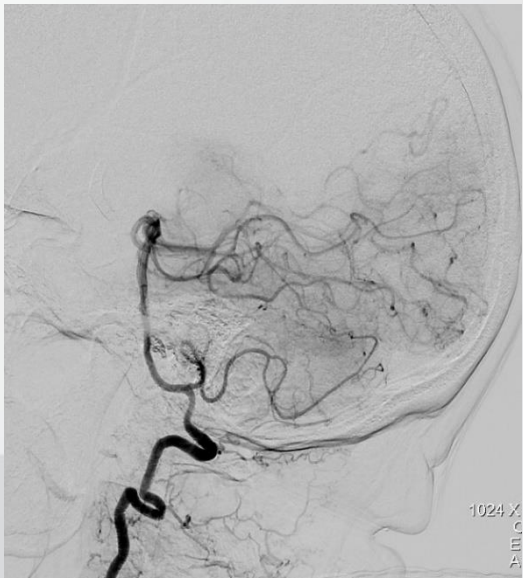
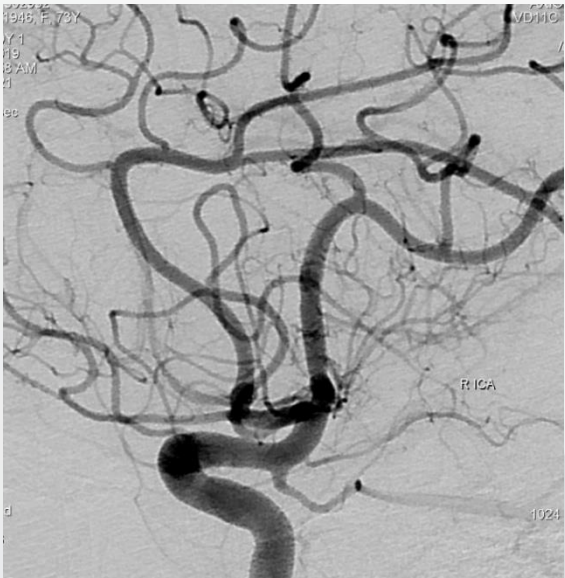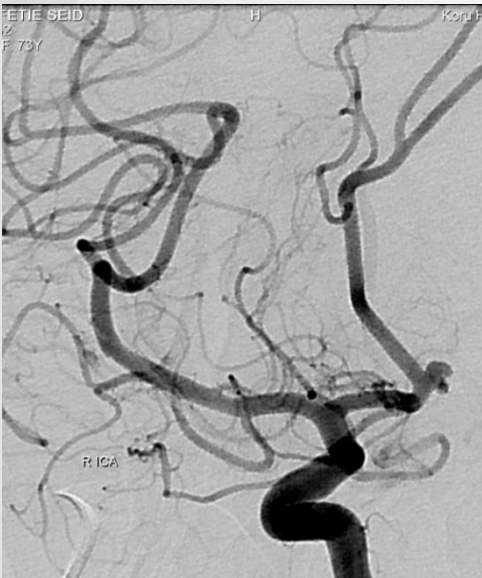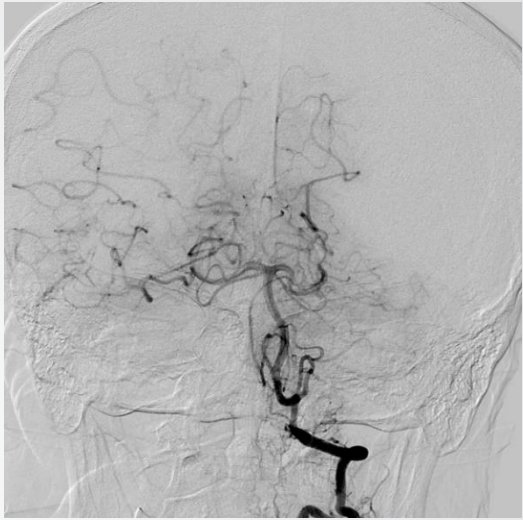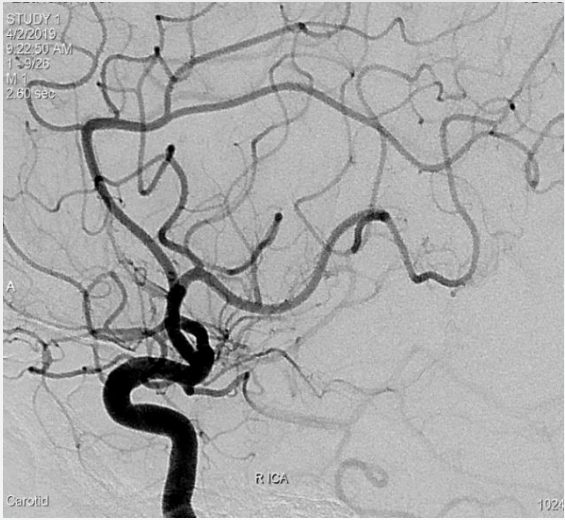


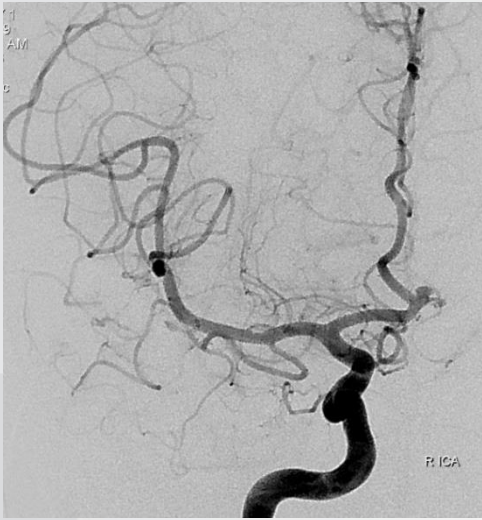9 MONTHS CONTROL, 3 MONTHS AFTER PRASUGREL STOPPED

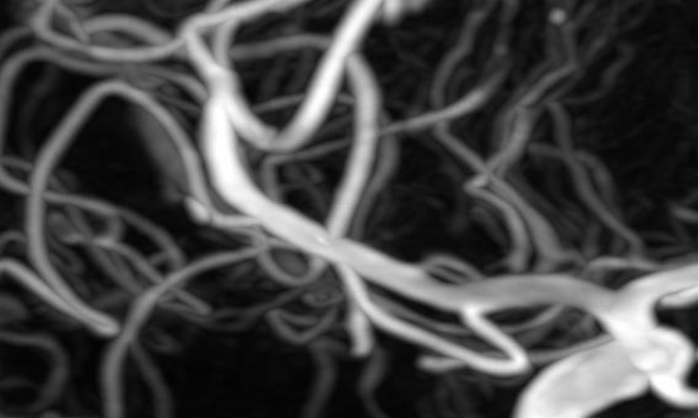
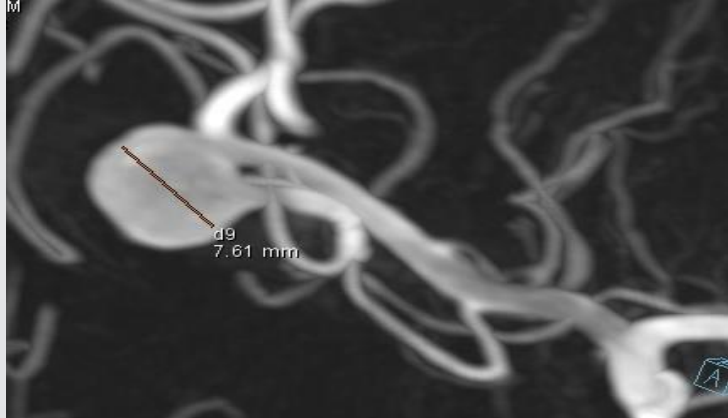
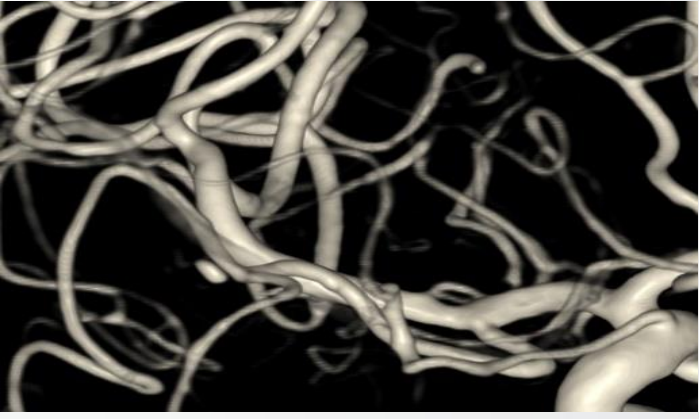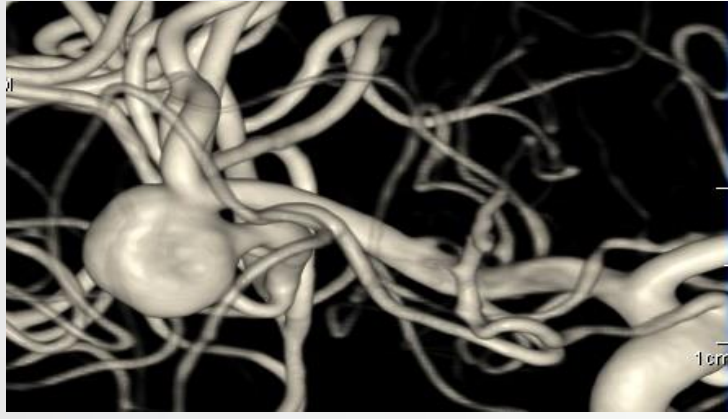

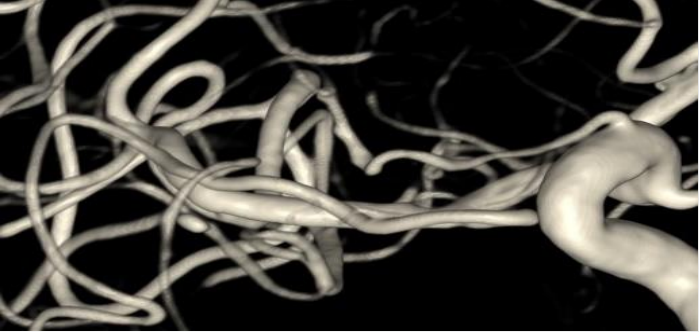
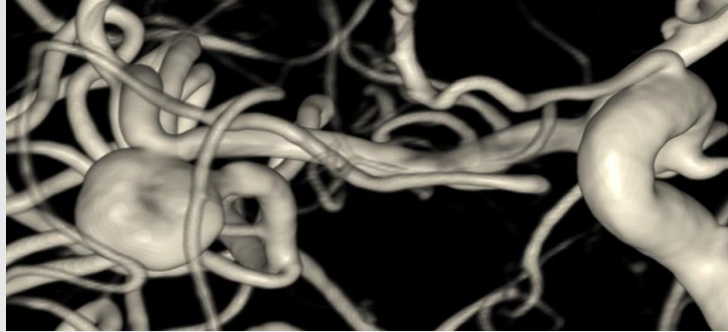12 MONTHS CONTROL MRA, 6 MONTHS AFTER PRASUGREL STOPPED

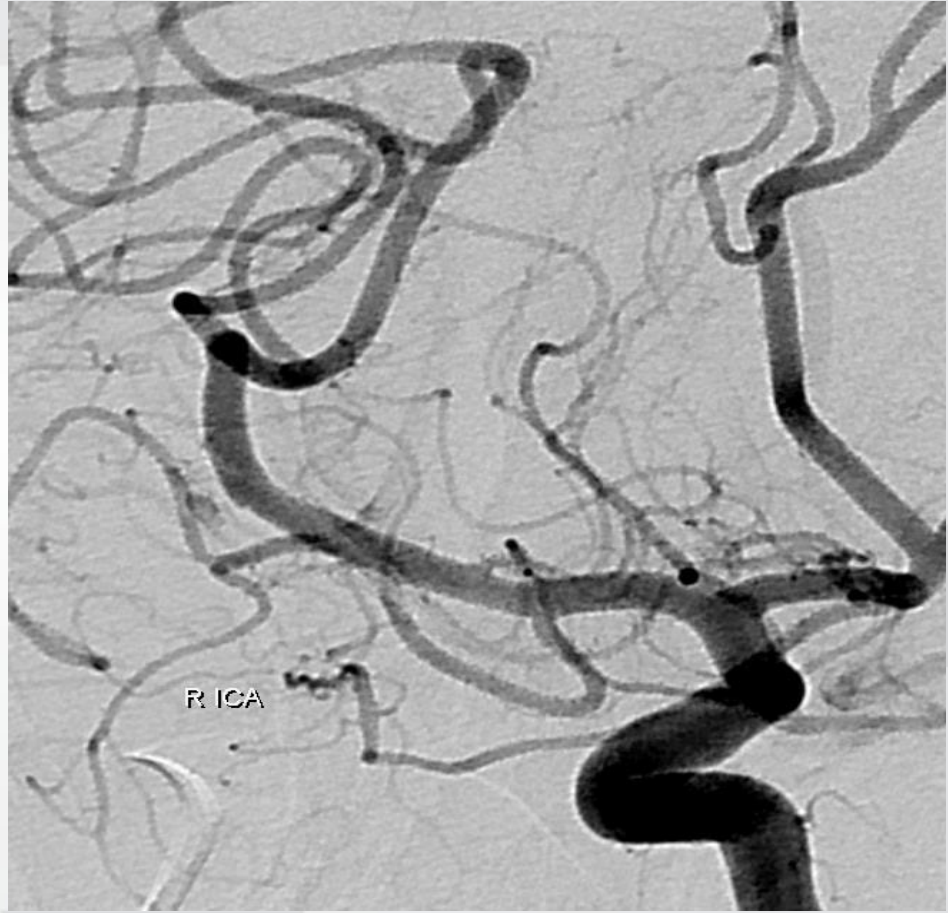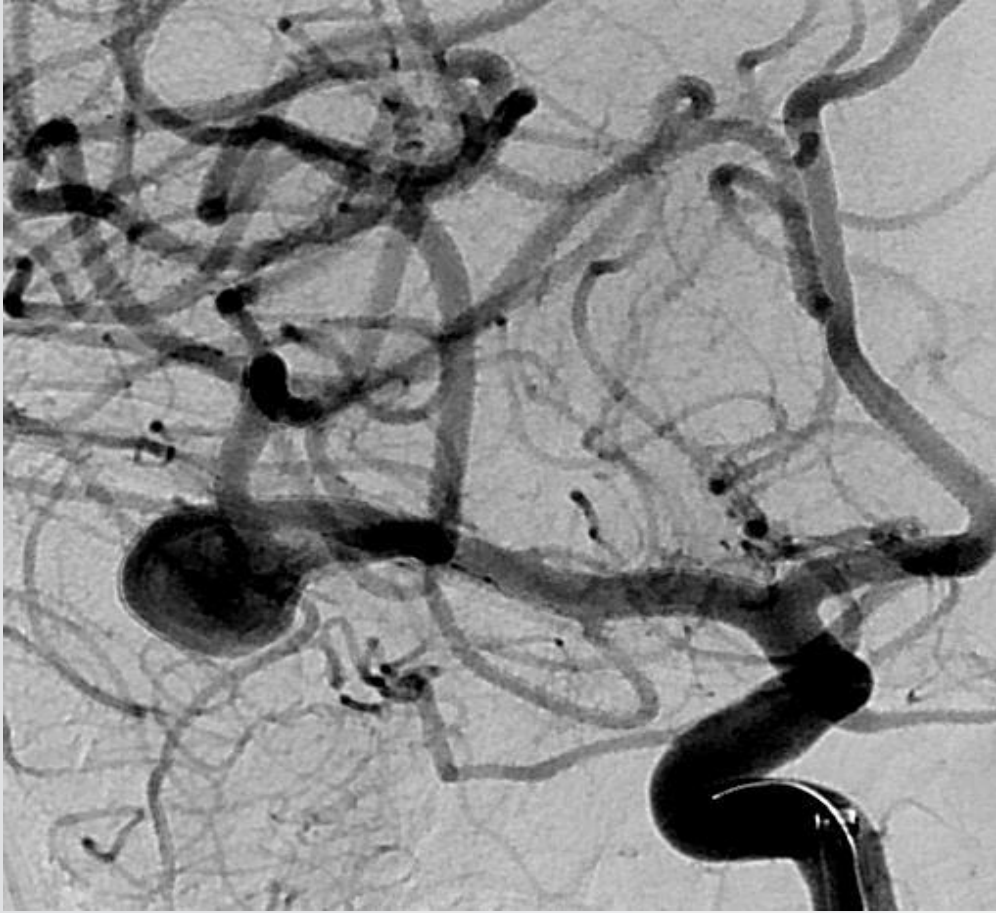
1 YEAR CONTROL



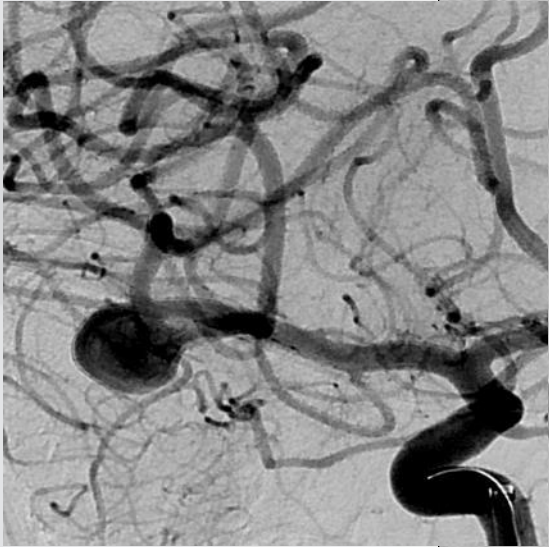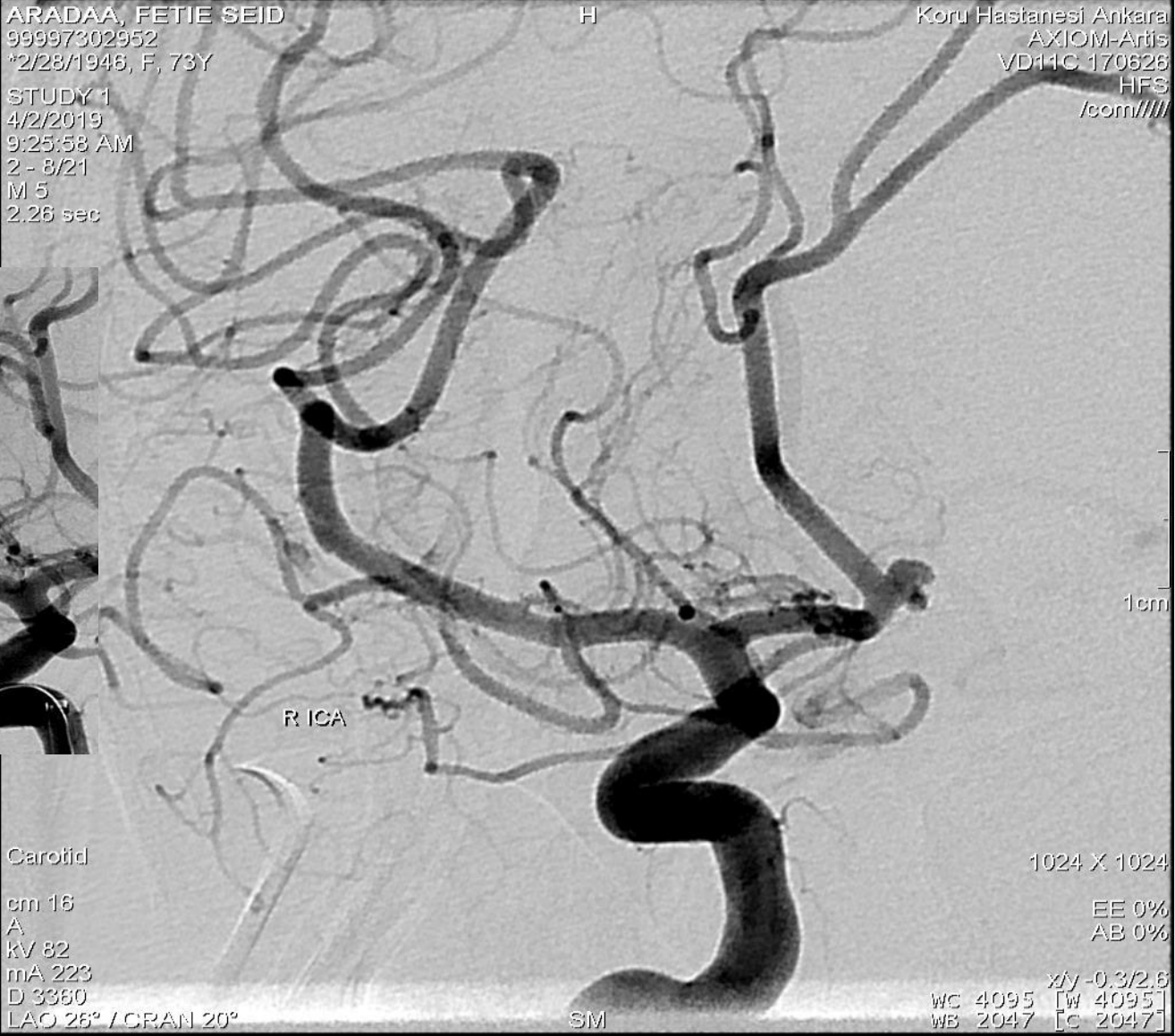1 YEAR CONTROL



1 YEAR CONT CLASS 1C OCC



1 YEAR CONTROL



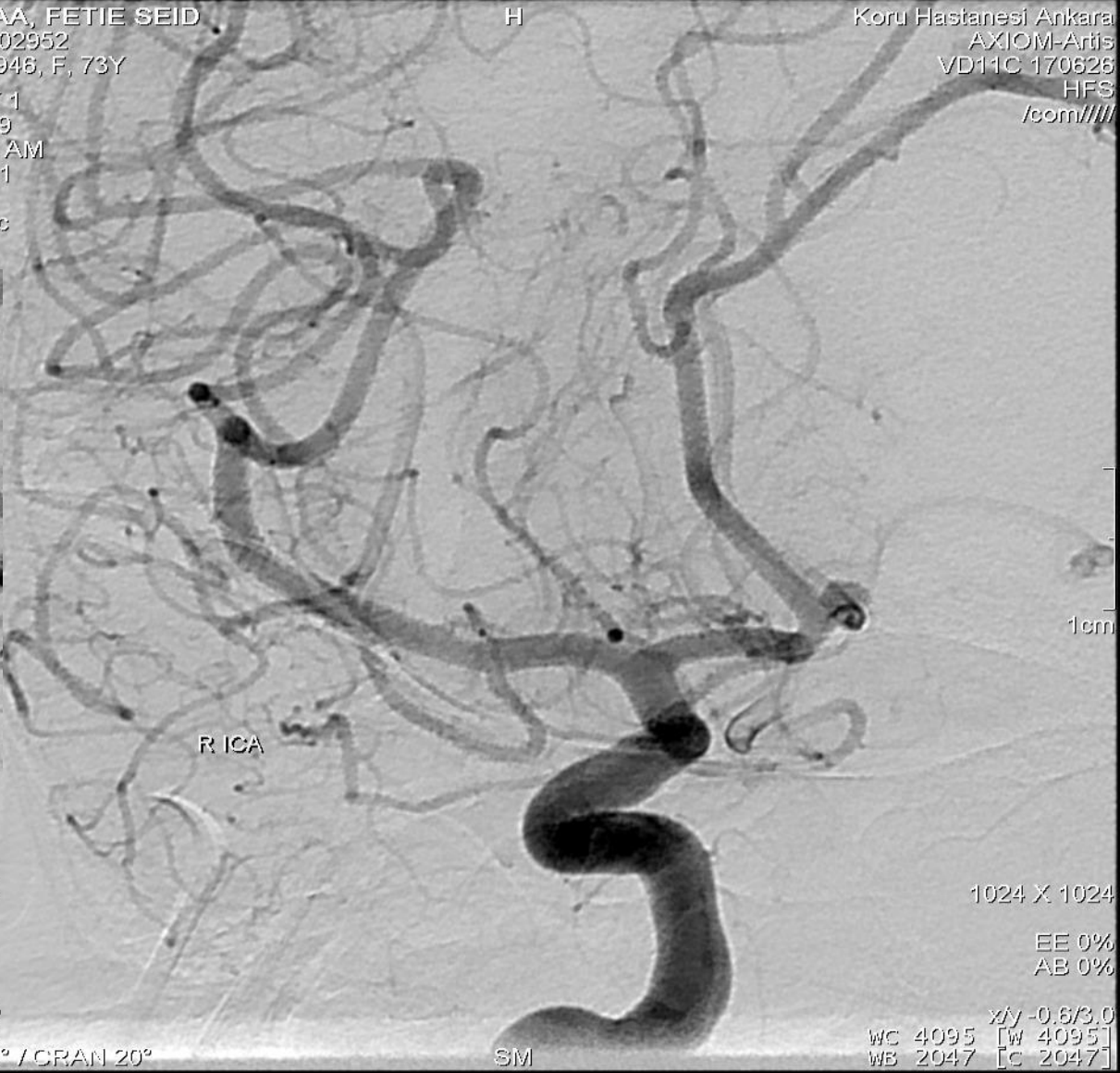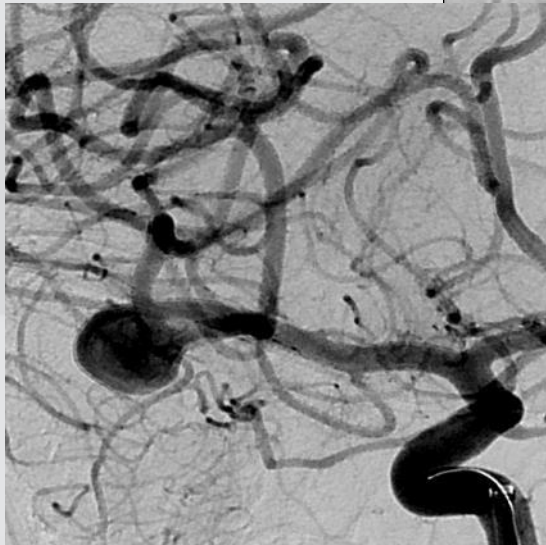
1 YEAR CONTROL

ARADAA, FETIE SEID
99997302952
*2/28/1946, F, 73Y

STUDY 1
4/2/2019
9:25:58 AM
2 - 10/21
M 5
2.91 sec

H

Koru Hastanesi Ankara
AXIOM-Artis
VD11C 170626
HFS
/com////



R ICA

1cm

Carotid

1024 X 1024

cm 18

EE 0%

A

AB 0%

KV 82

mA 223

D 3360

x/y -0.5/3.0

LAO 26° / CRAN 20°

SM

WC 4095 [W 4095]
WB 2047 [C 2047]

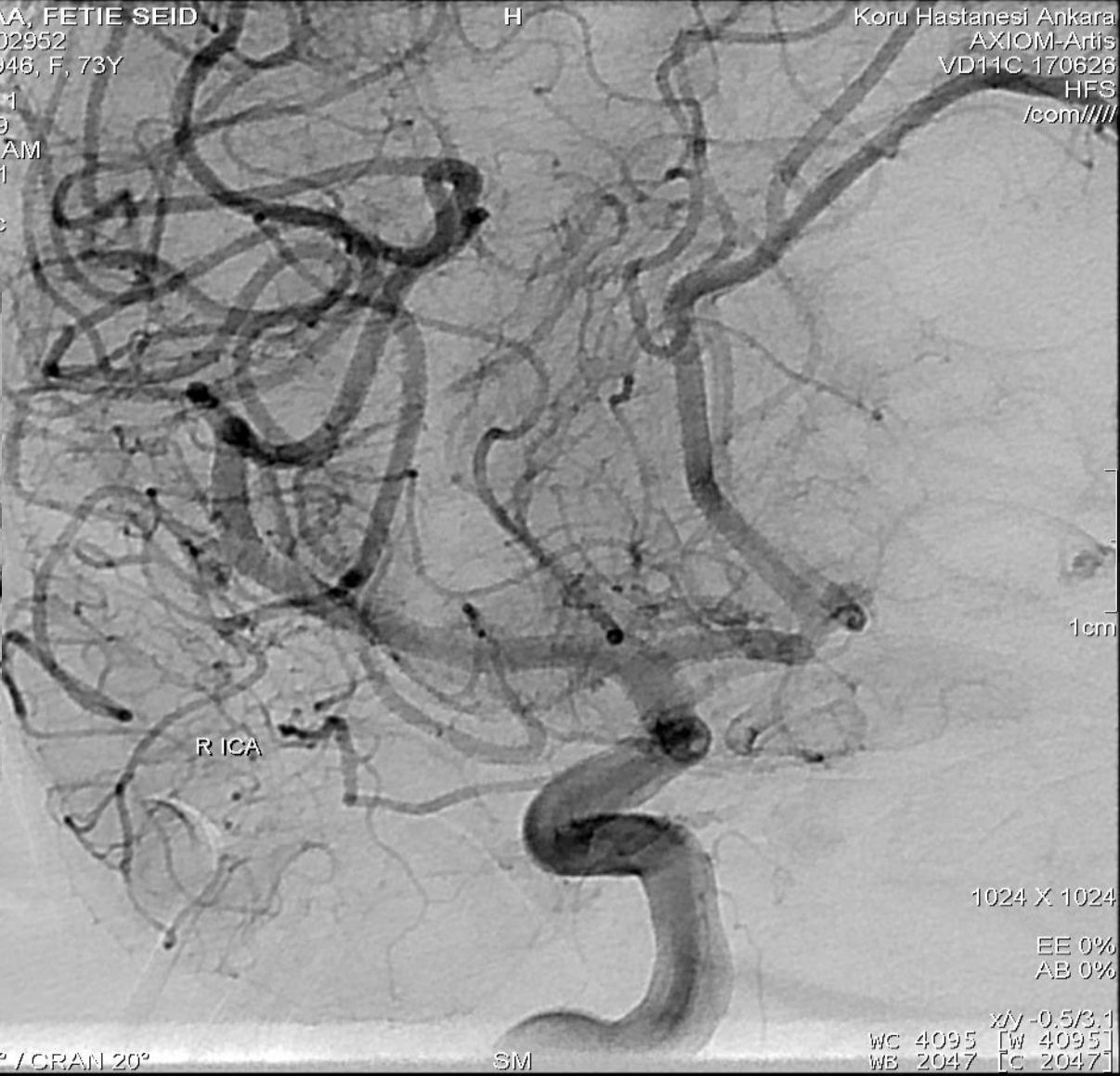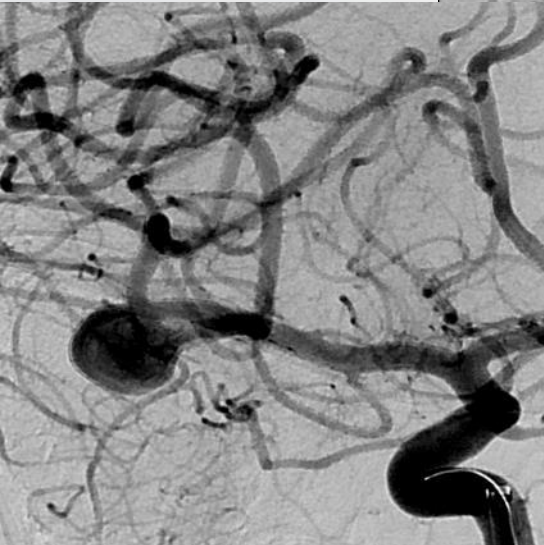
1 YEAR CONTROL

ARADAA, FETIE SEID
99997302952
*2/28/1946, F, 73Y

STUDY 1
4/2/2019
9:25:58 AM
2 - 16/21
M 5
4.85 sec

H

Koru Hastanesi Ankara
AXIOM-Artis
VD11C 170628
HFS
/com/////



R ICA

1cm

Carotid

1024 X 1024


cm 16
A
kV 82
mA 223
D 3360
LAO 26° / CRAN 20°

EE 0%
AB 0%

x/y -0.5/3.1

WC 4095 [W 4095]
WB 2047 [C 2047]

SM



WLNC 2018

SHANGHAI CASES

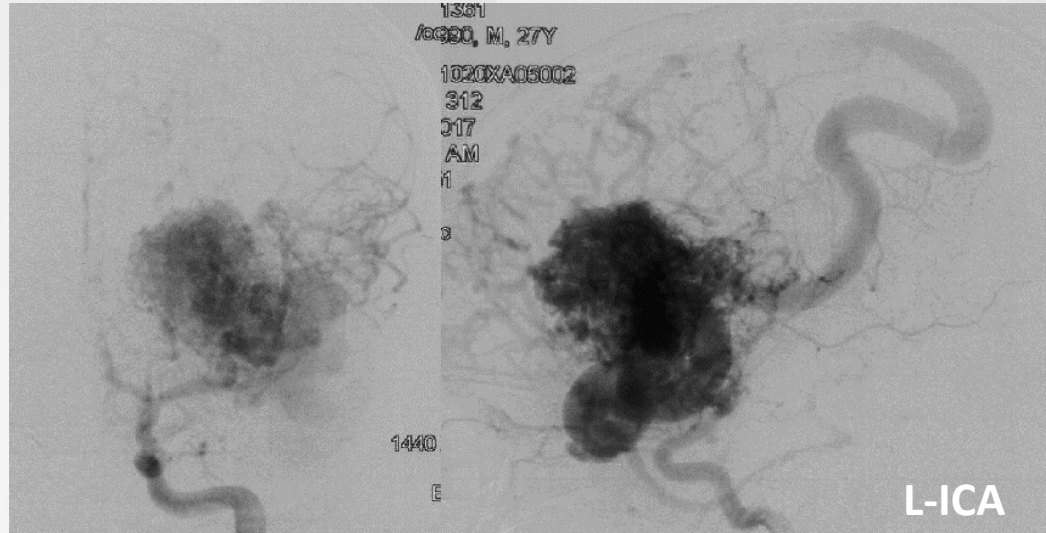
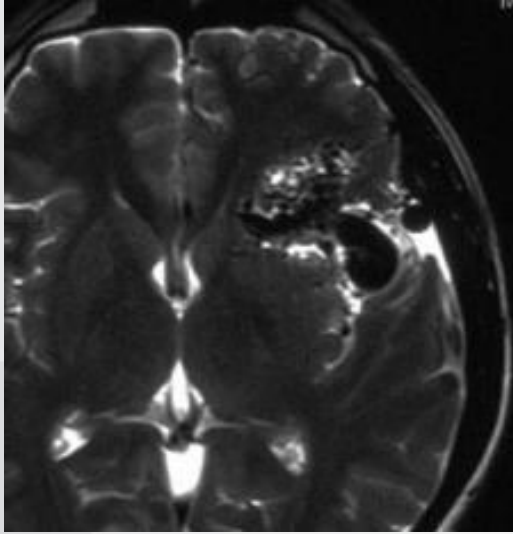
PATIENT 1

- **27 yo, Male**
- Recurrent gross seizure for 1 year
- MRI & DSA revealed left frontal lobe AVM
- Transarterially Embolized 3 times during the past 6 months

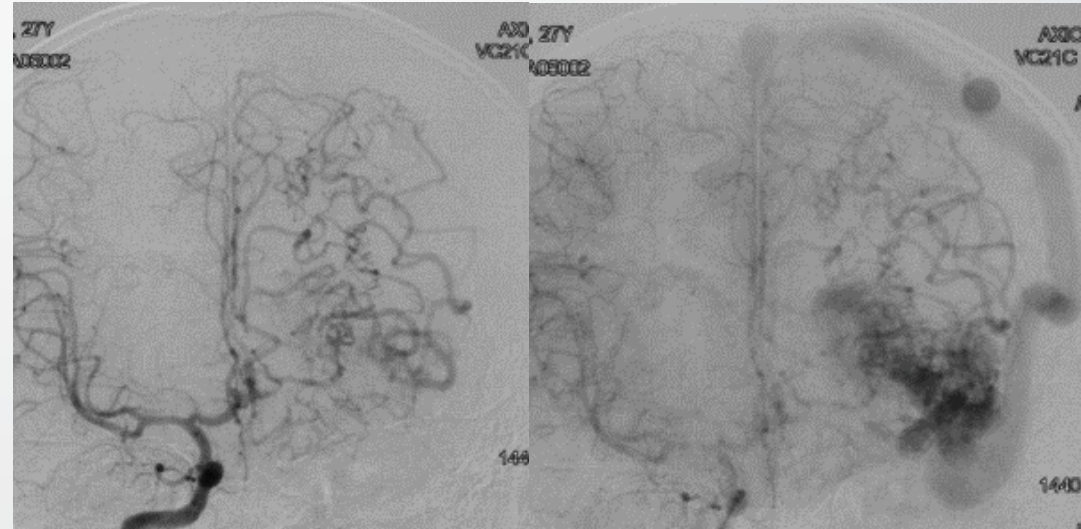
Transvenous Embolization of Frontal Lobe AVM



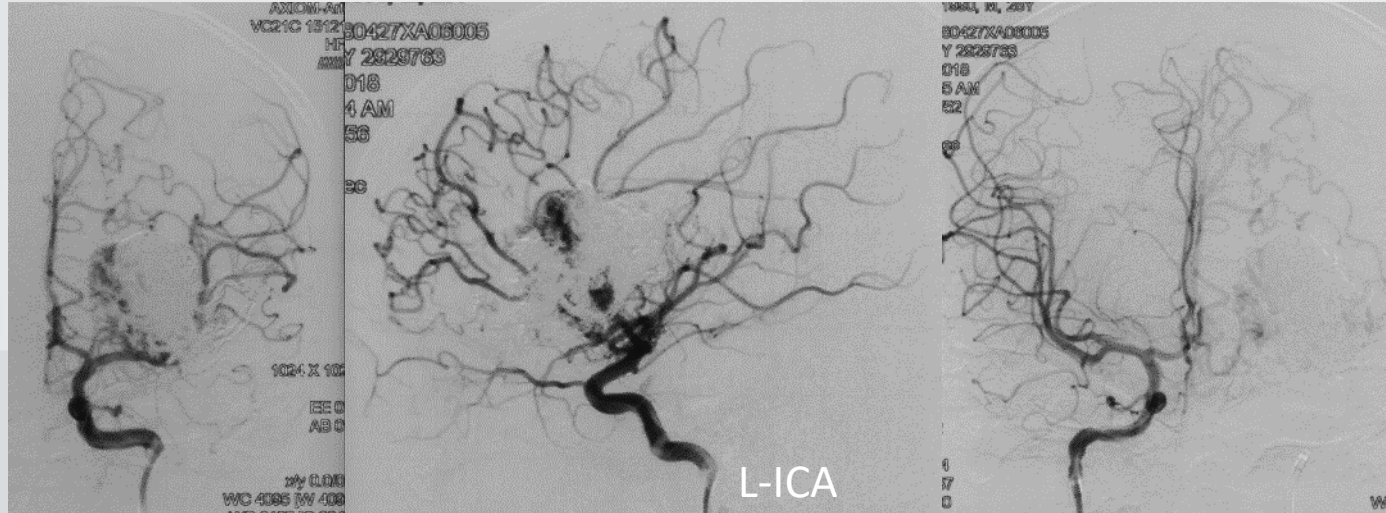
MRI & DSA



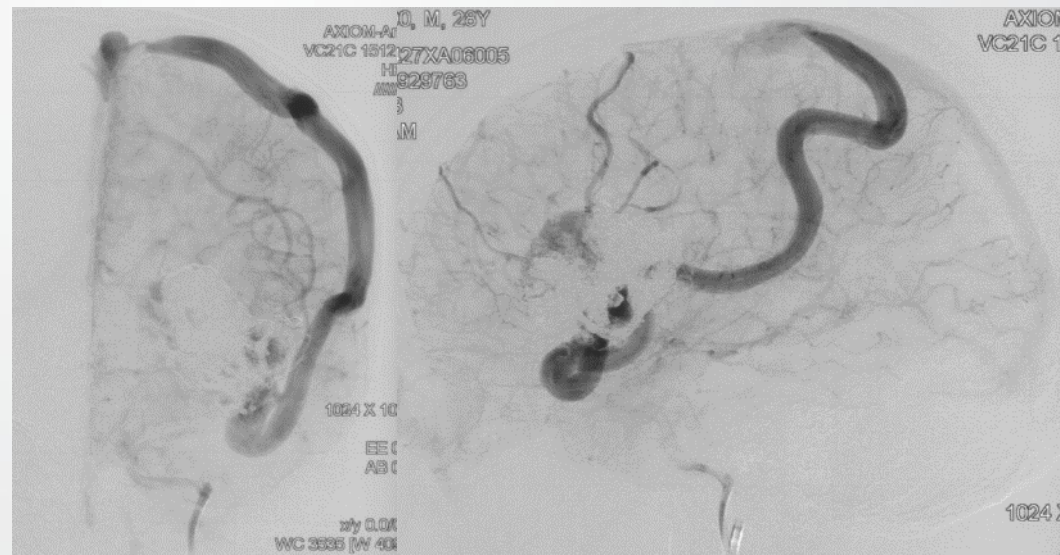
- AVM fed by branches of MCA, lenticulostriate arteries, branches of AchA, recurrent artery of Heubner and collateral arteries from ACA, and drained by Trolard Vein.



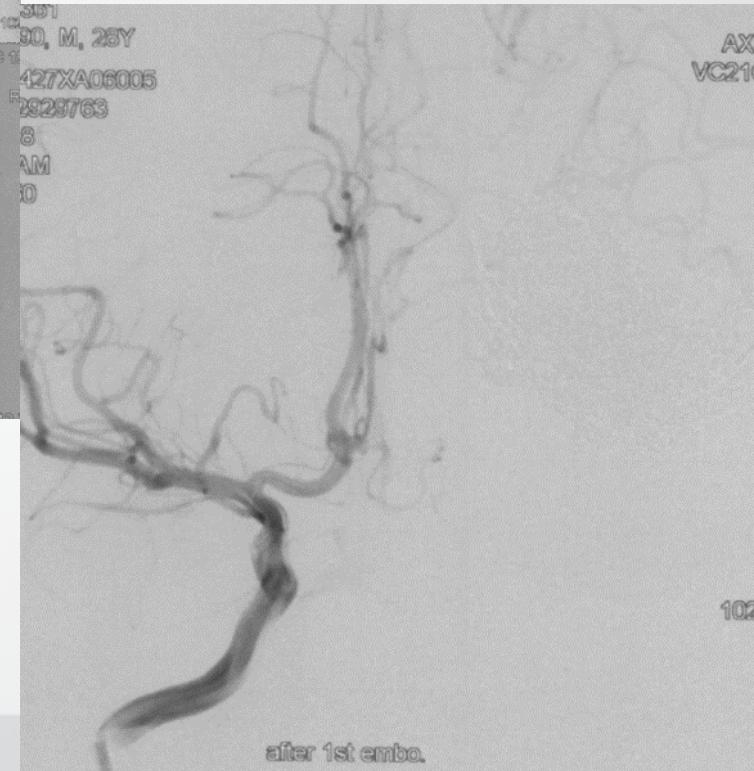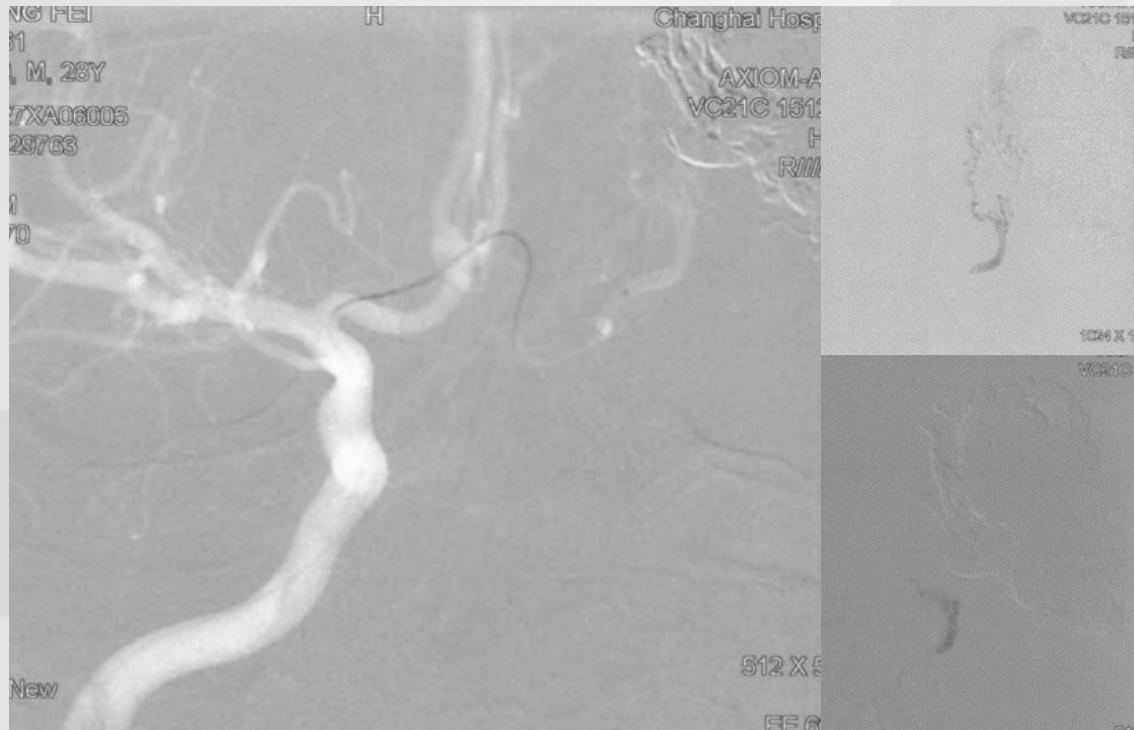After 3rd Session of Transarterial Embo.



- Having been transarterially embolized 3 times, 40% of AVM left.
- The residual AVM was fed by leticulostriate arteries, branches of AchA, recurrent artery of Heubner and collateral arteries from ACA, and dominantly drained by Trolard Vein.

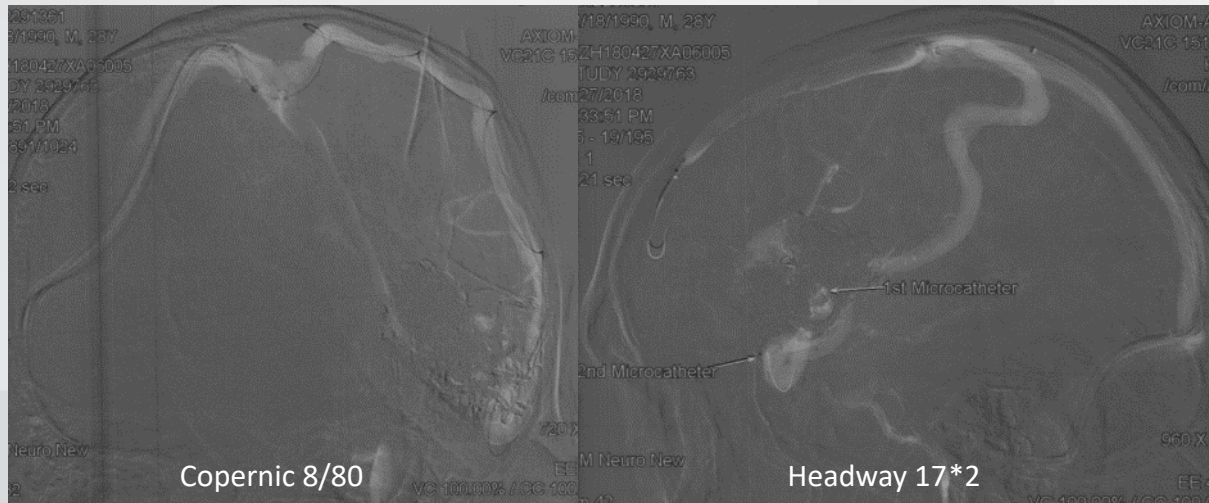


4th Session

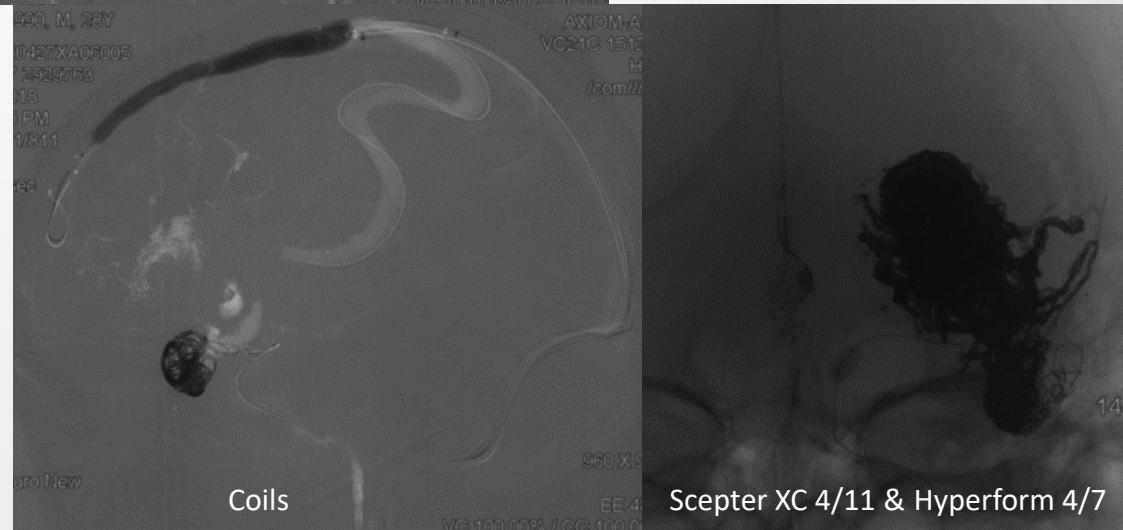

- A Marathon Catheter was navigated into the recurrent artery of Heubner and 20% Glubran was injected.

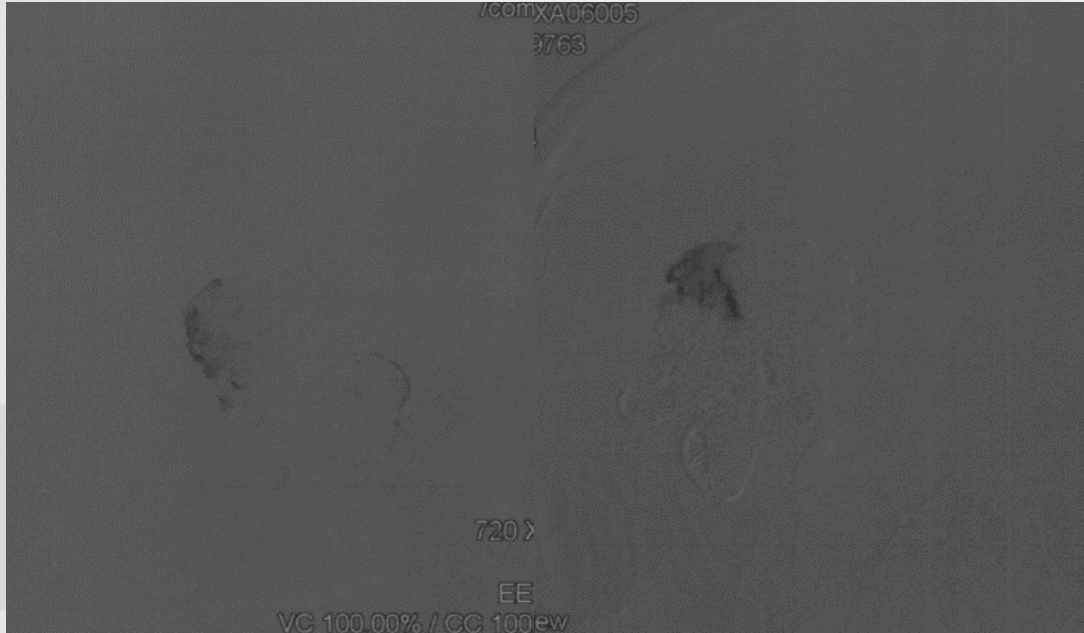
4th Session



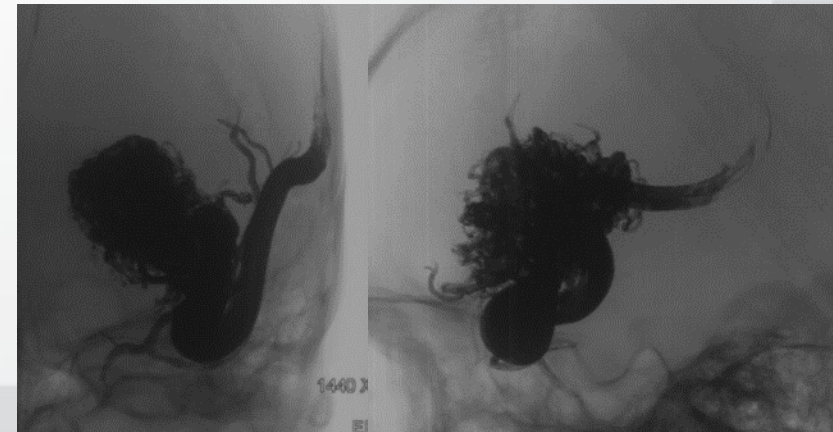
- A Copernic 8/80 balloon was inflated in the SSS to assist the navigation of 2 Headway-17 microcatheters into the drainage vein.
- Several coils were packed via a Headway-17 catheter to make a plug.
- A Scepter XC 4/11 and Hyperform 4/7 balloon were inflated in the right ACA and ICA terminal, respectively, to control the arterial blood flow.



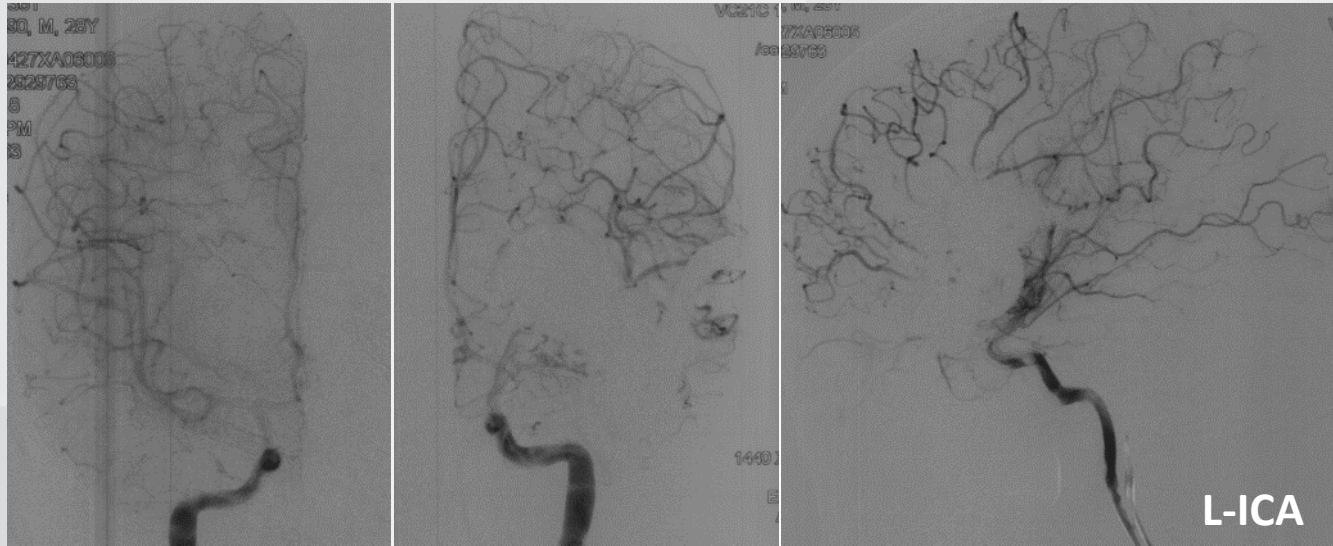
4th Session



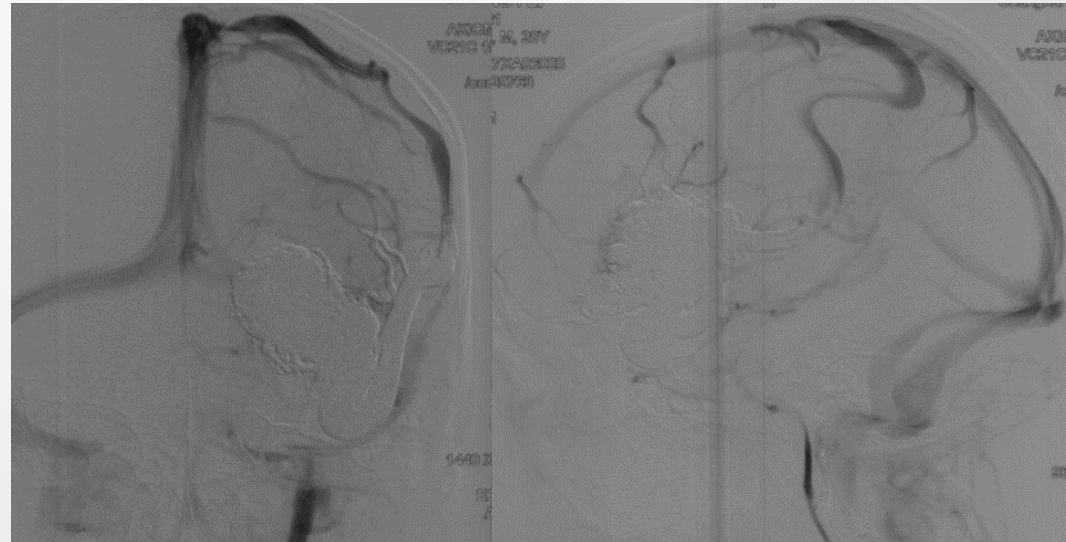
- Onyx-18 was injected into the drainage vein and then infiltrated in the the nidus.



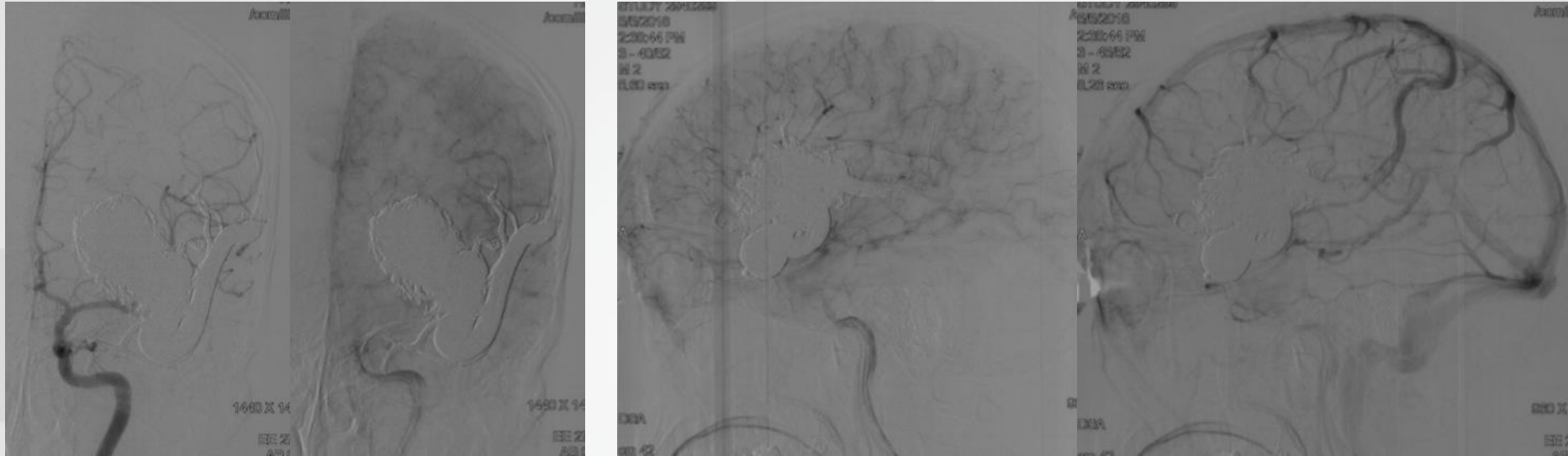
After 4th Session



- Final control showed the nidus was totally obliterated with a small part of contrast filling in front of the nidus, suspecting a small part residual AVM.
- The patient was treated by continuous sedation for 72hrs with systolic blood pressure below 100mmHg. No neurological defect was detected except for drowsiness.

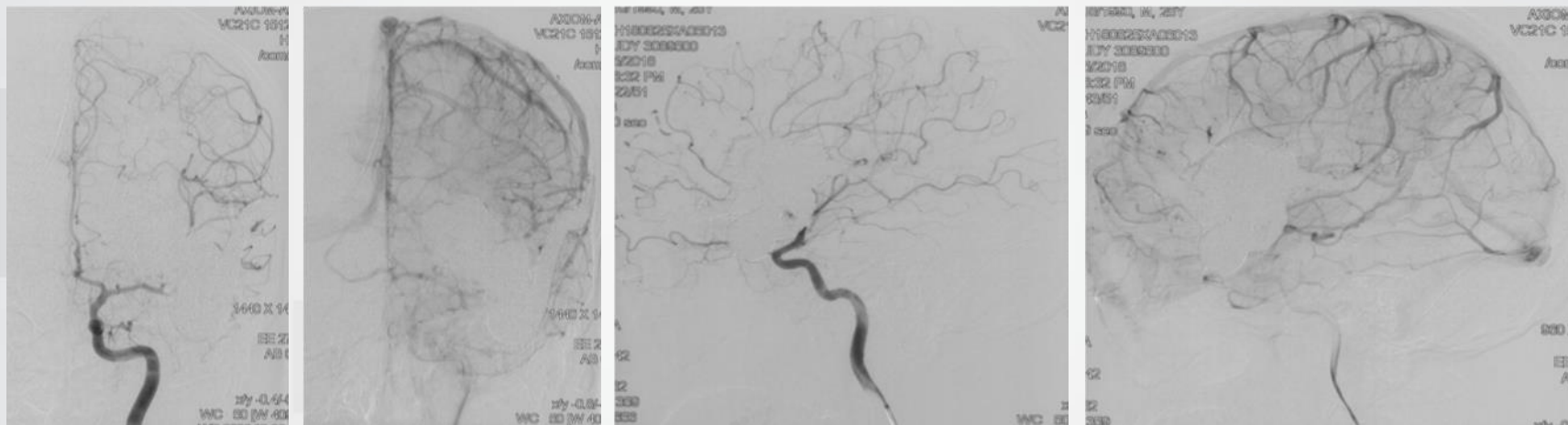


1 wk follow up



- Follow up DSA showed the nidus was totally obliterated one week after the 4th session.

3 months follow up



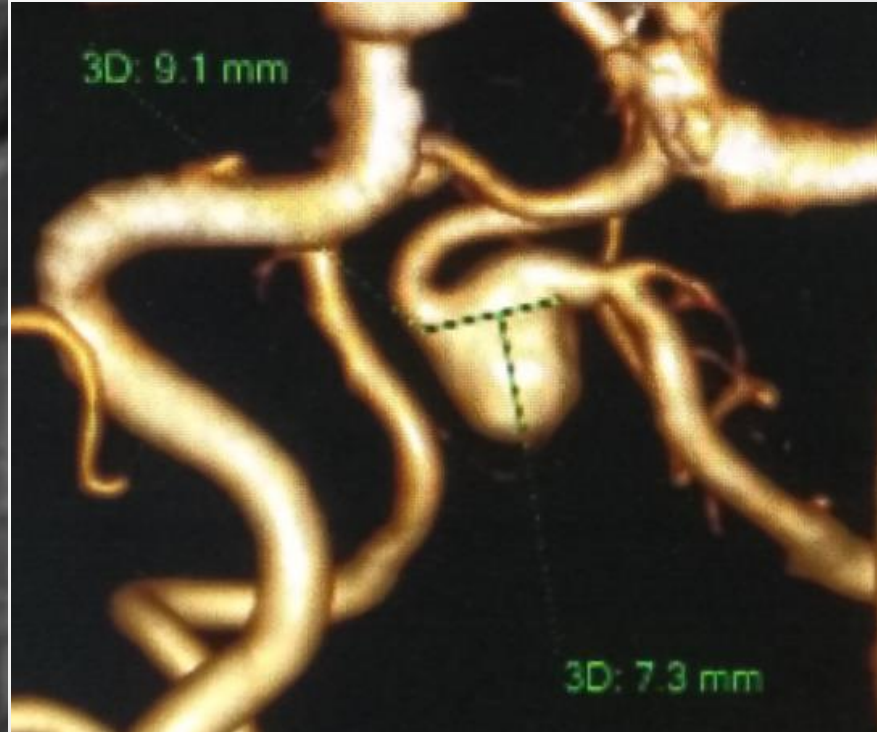
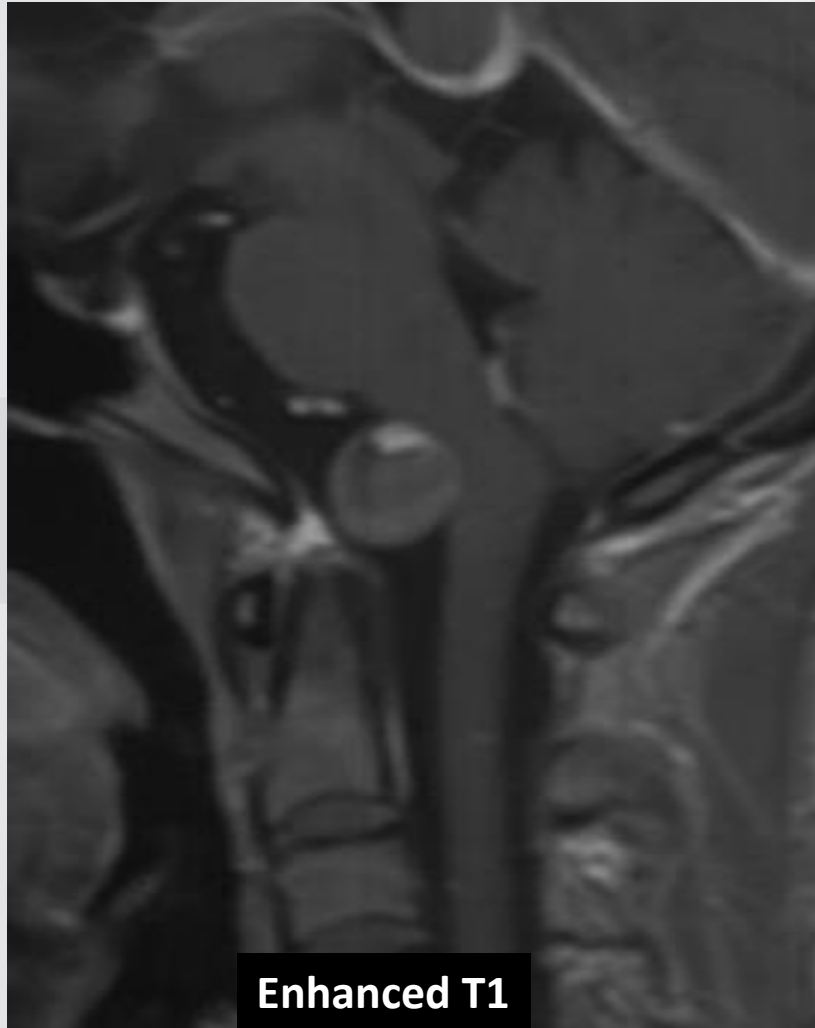
PATIENT 2

- **45 yo, Female**
- Recurrent dizziness and vomiting for 1 year
- Vertebral artery (V4) dissecting aneurysm

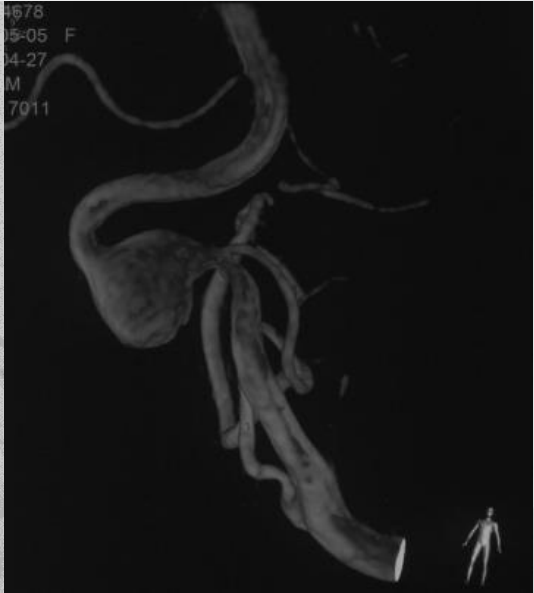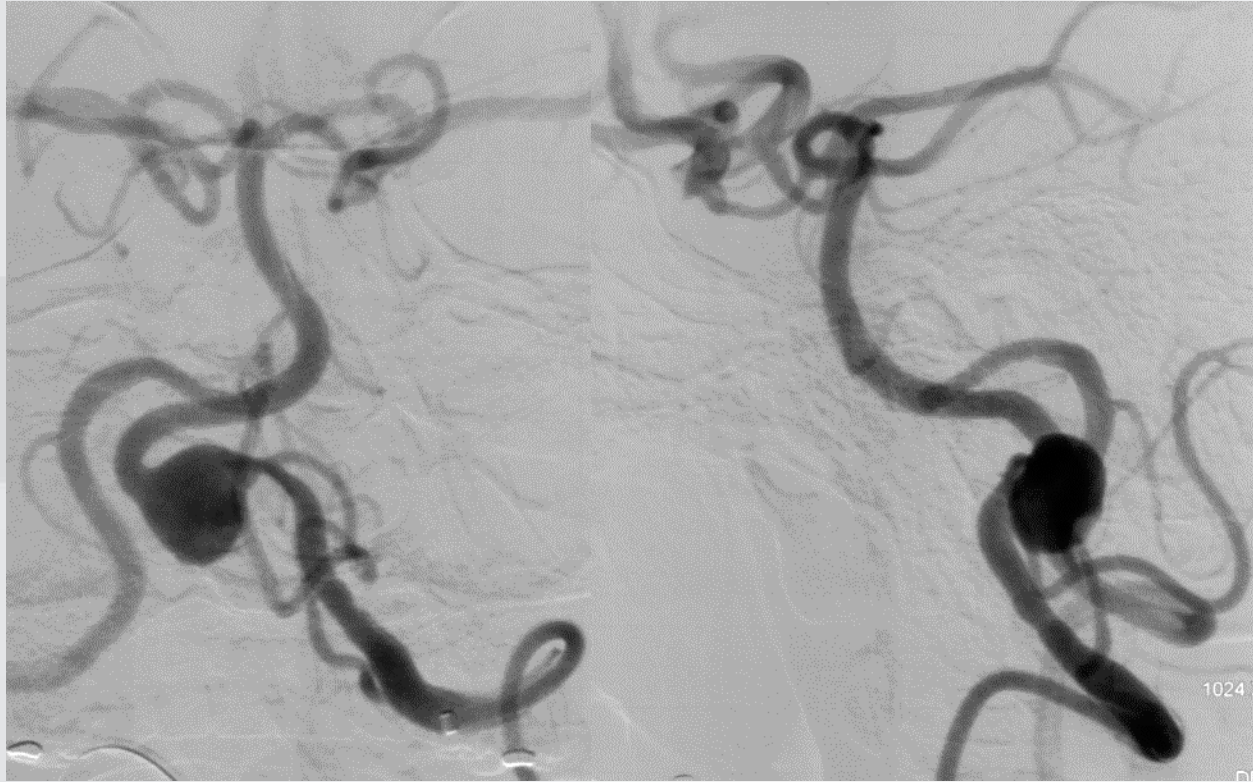
Tubridge Flow diverter for Vertebral Artery Dissecting Aneurysm



MRI & STA

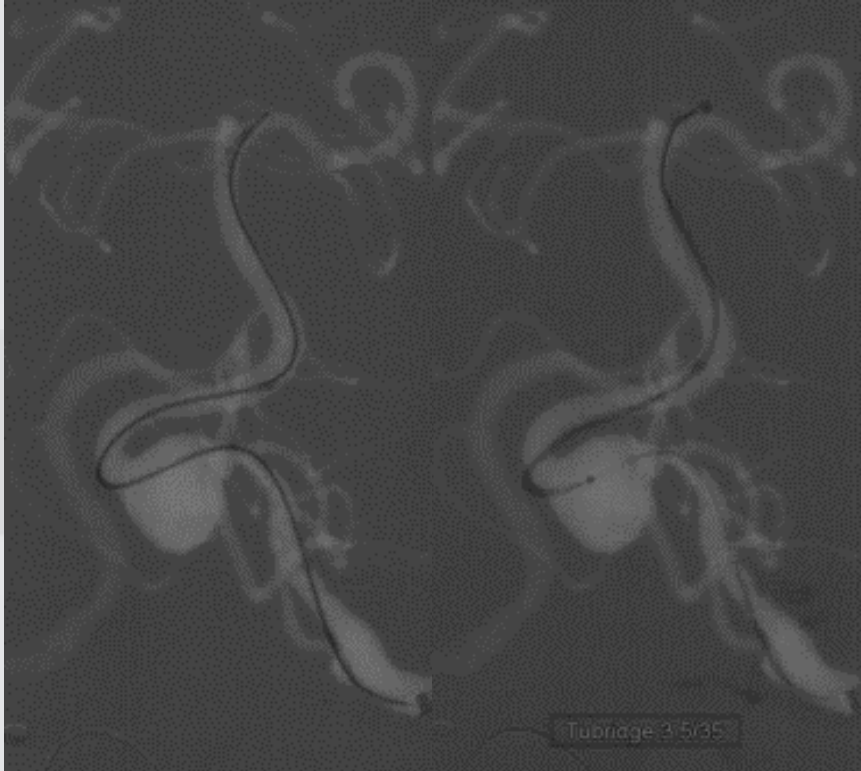


DSA

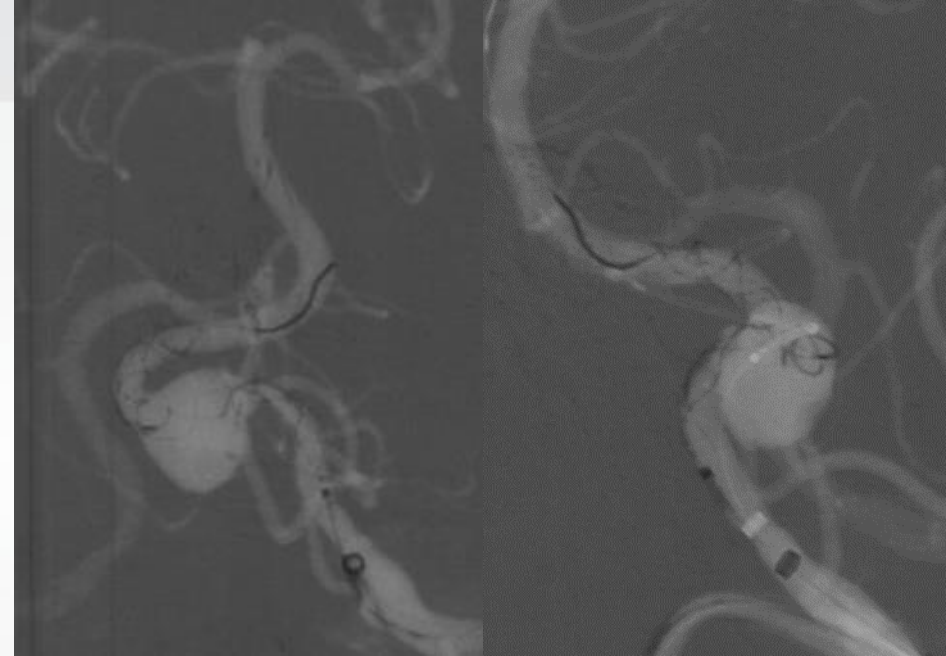


3D reconstruction

Procedure

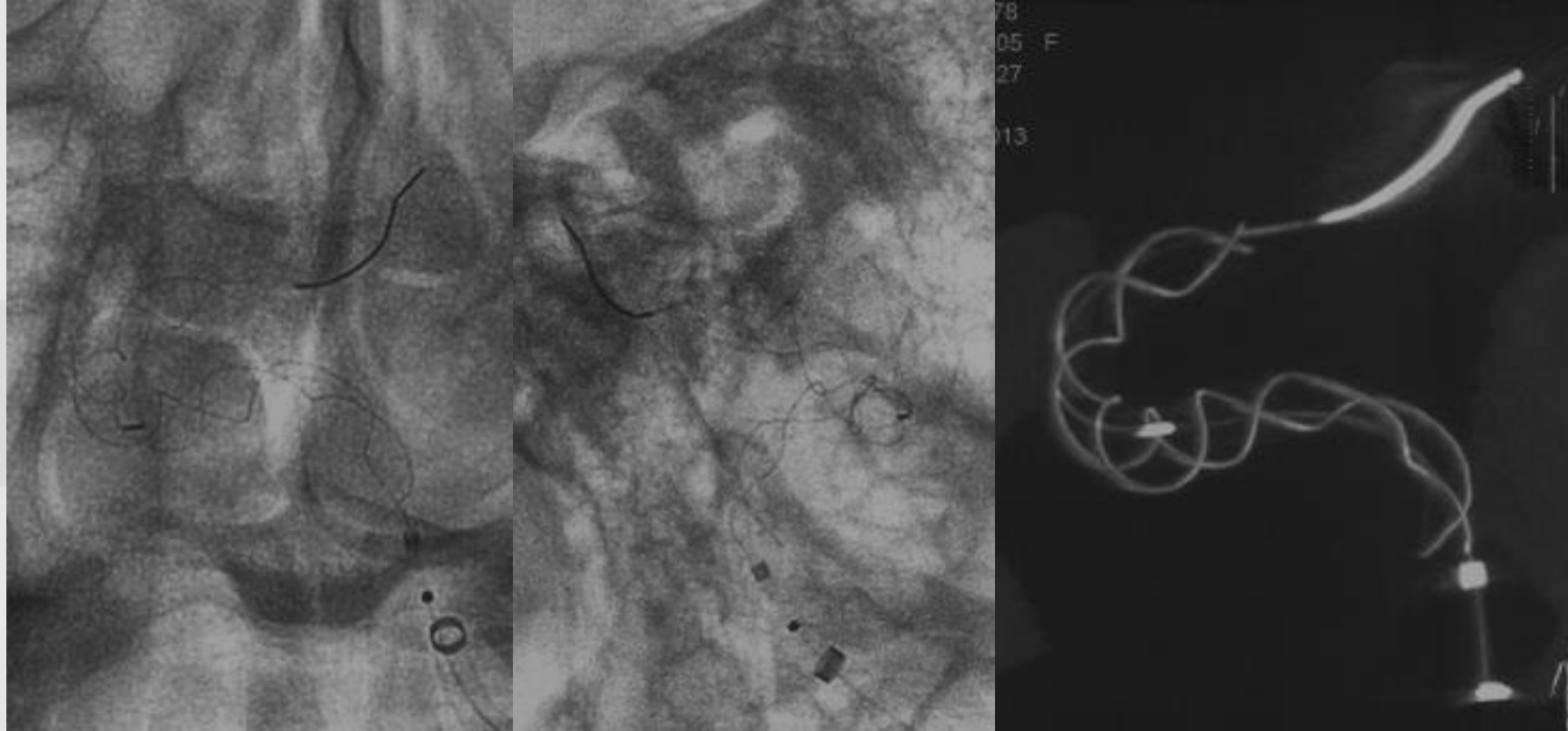


T-track & synchro 14



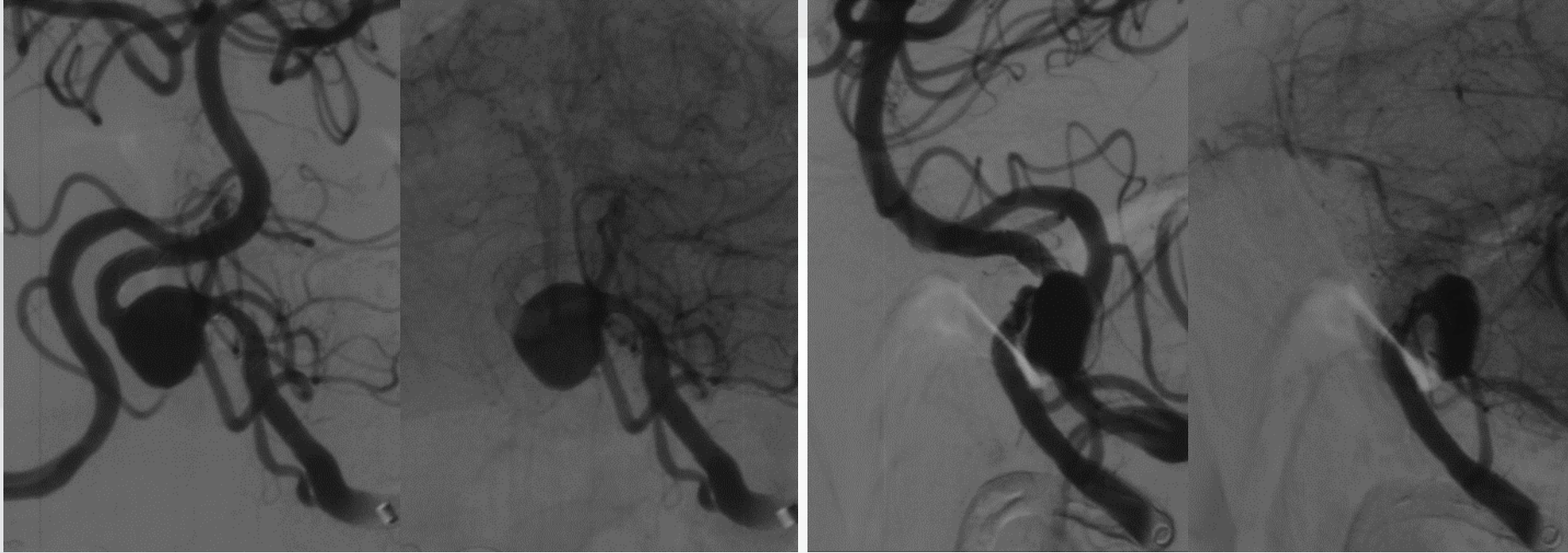Tubridge 3.5 mm/35mm

Procedure

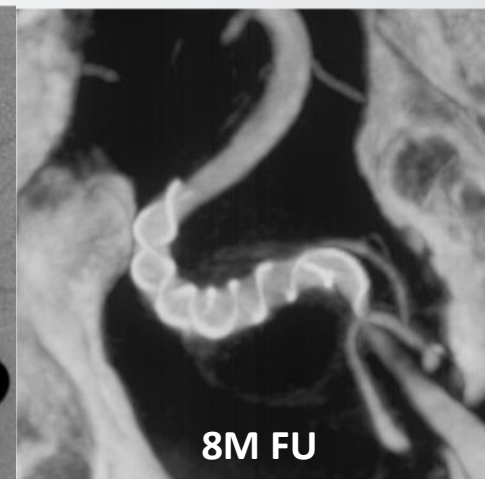
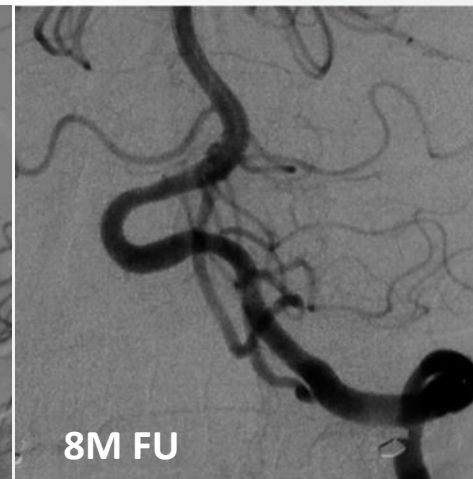
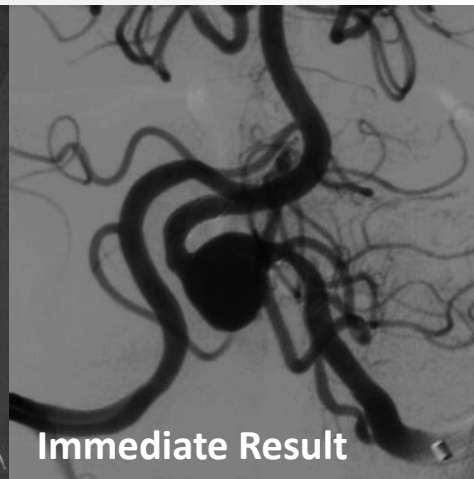
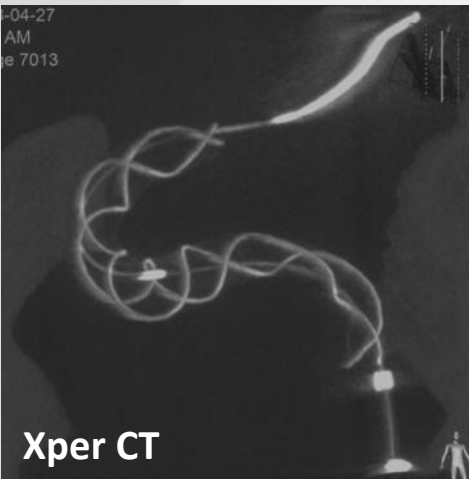
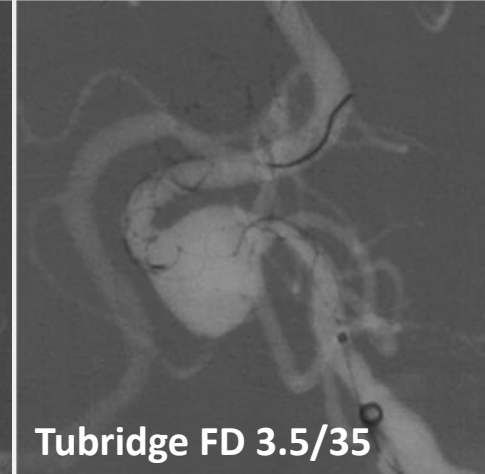
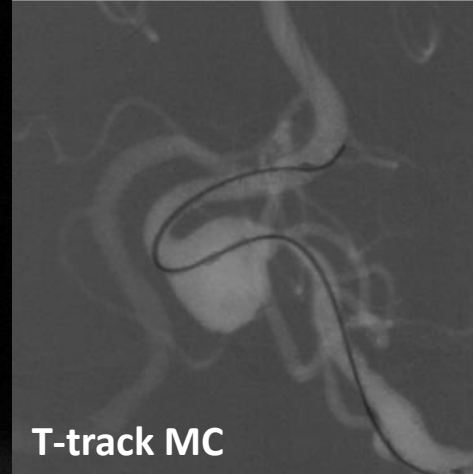
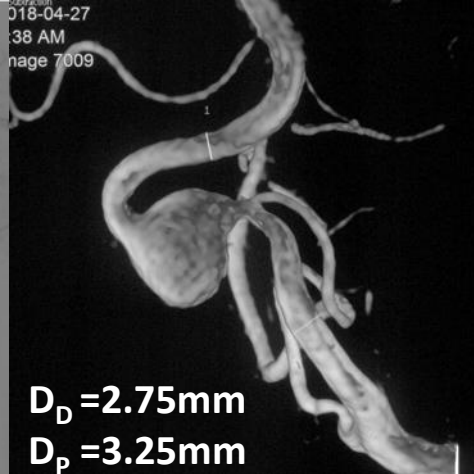
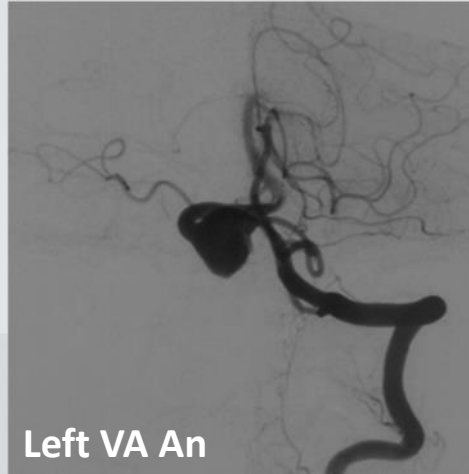
Xper CT

Procedure

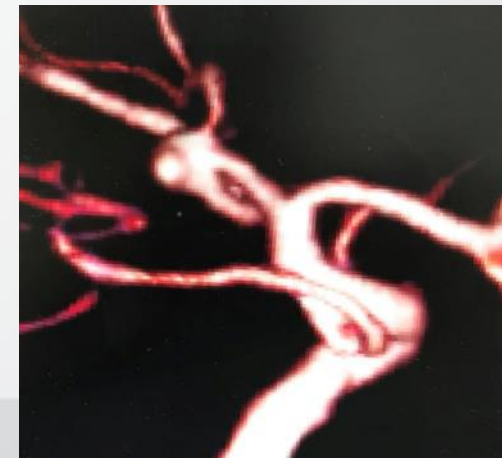
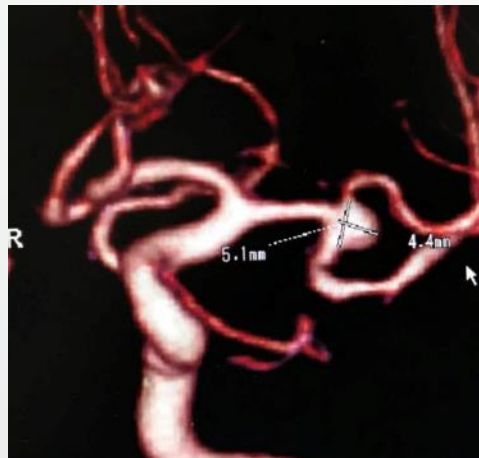
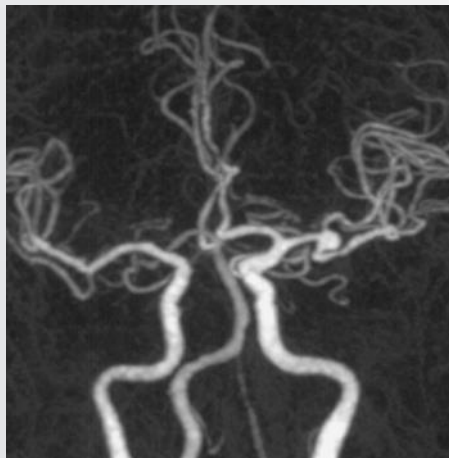


Follow Up

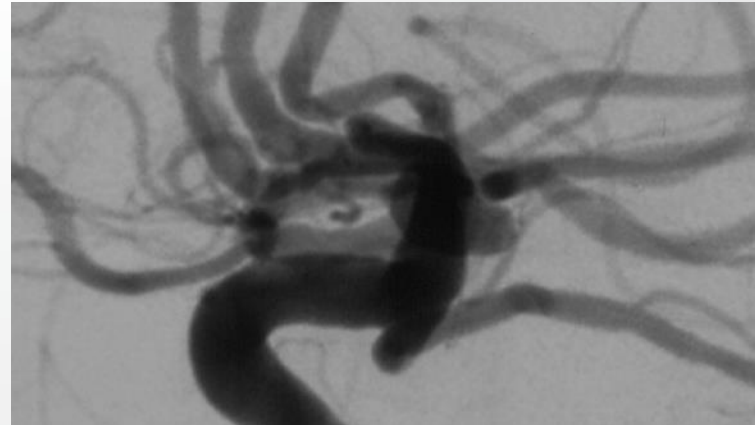
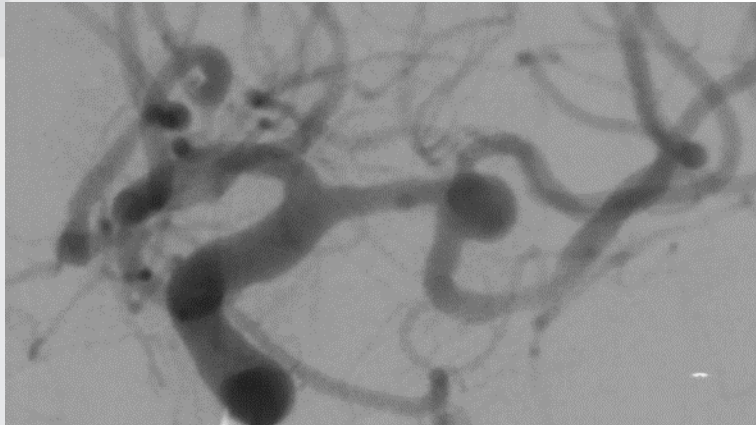
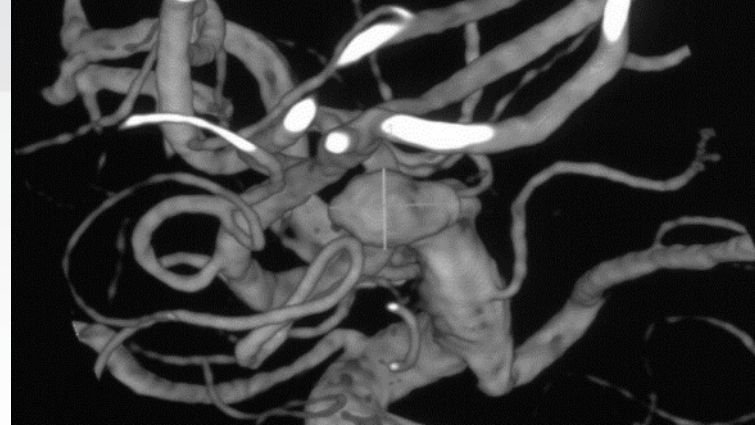
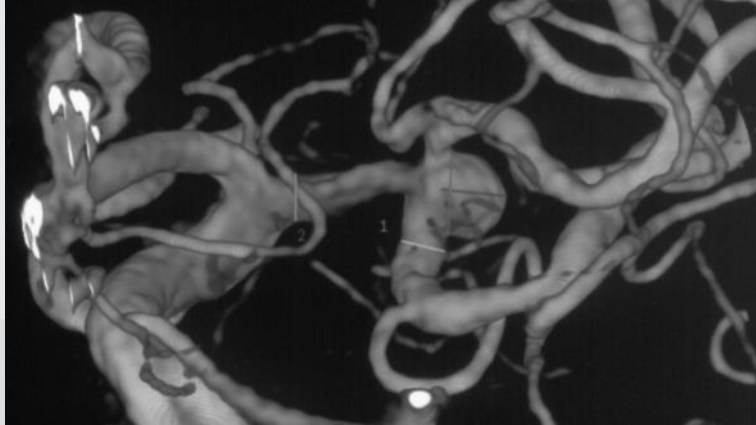


PATIENT 3

- 52 yo, Male
- Incidentally found intracranial aneurysm for 1 month
- Left MCA bifurcation aneurysm

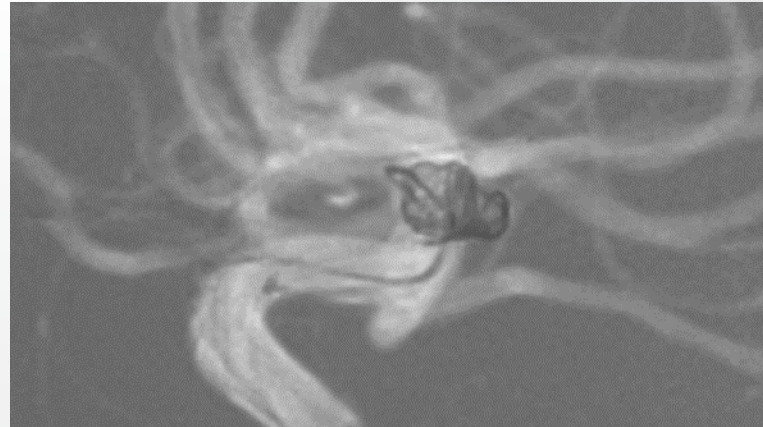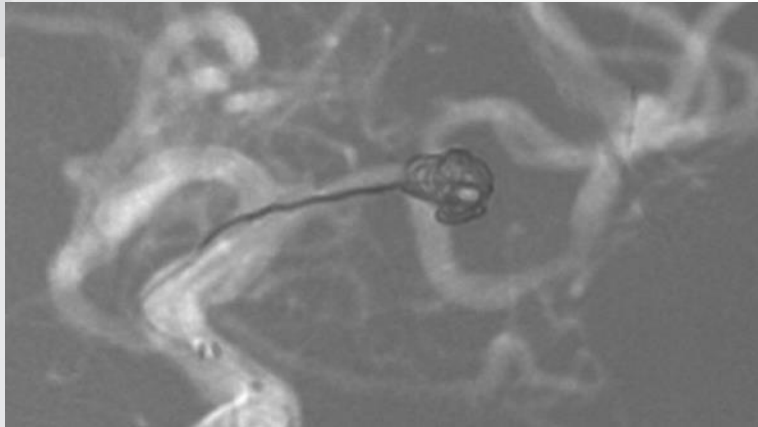

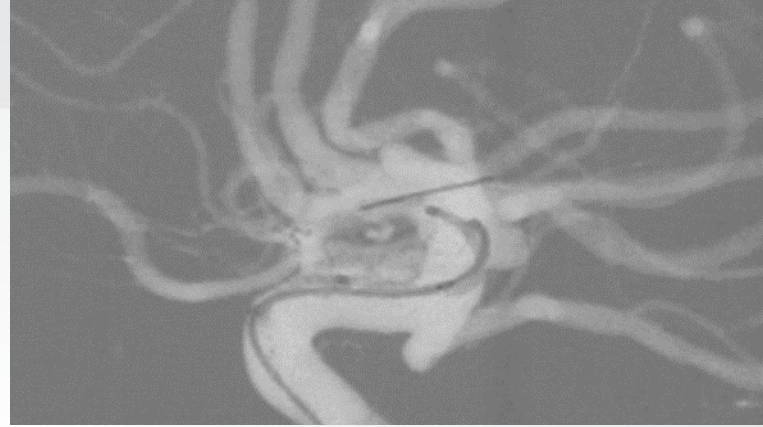
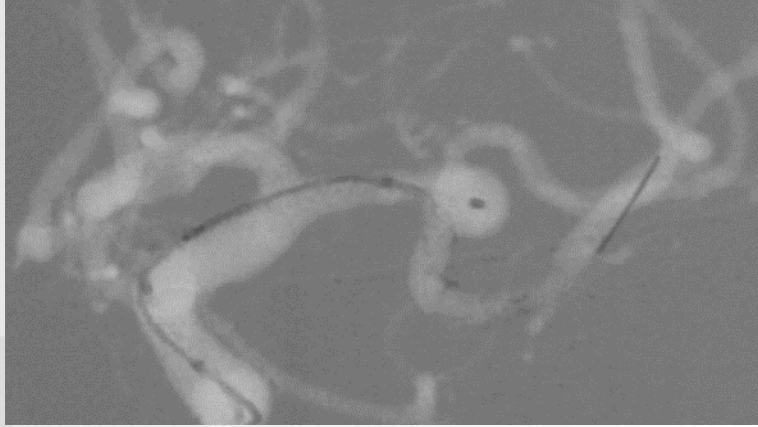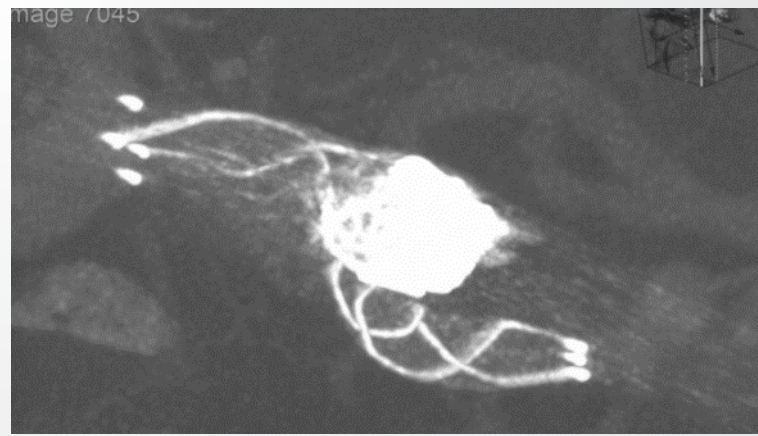
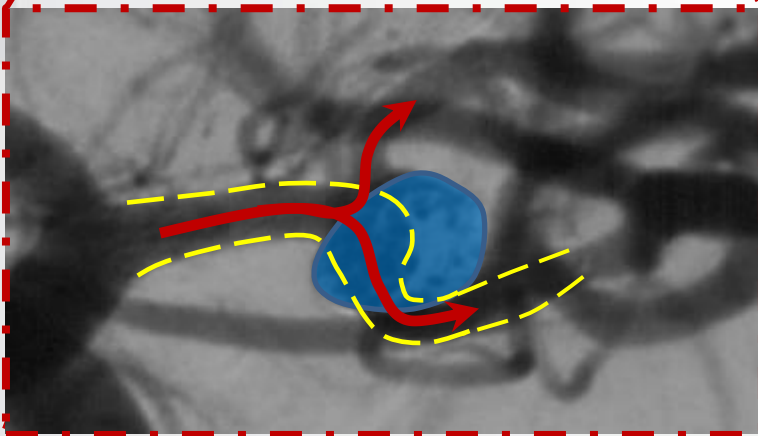
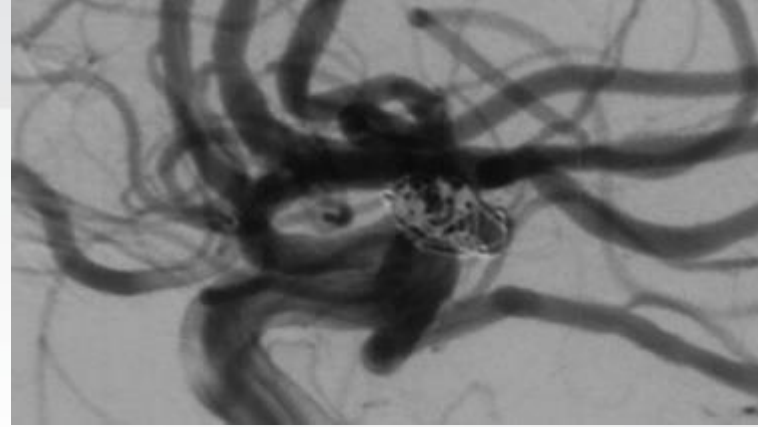
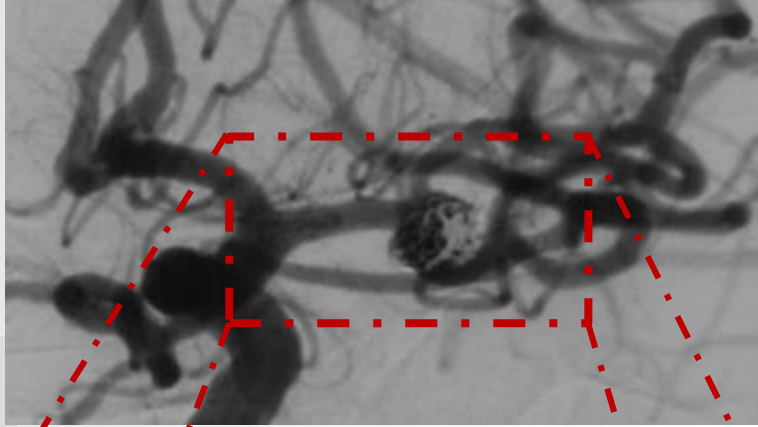
DSA



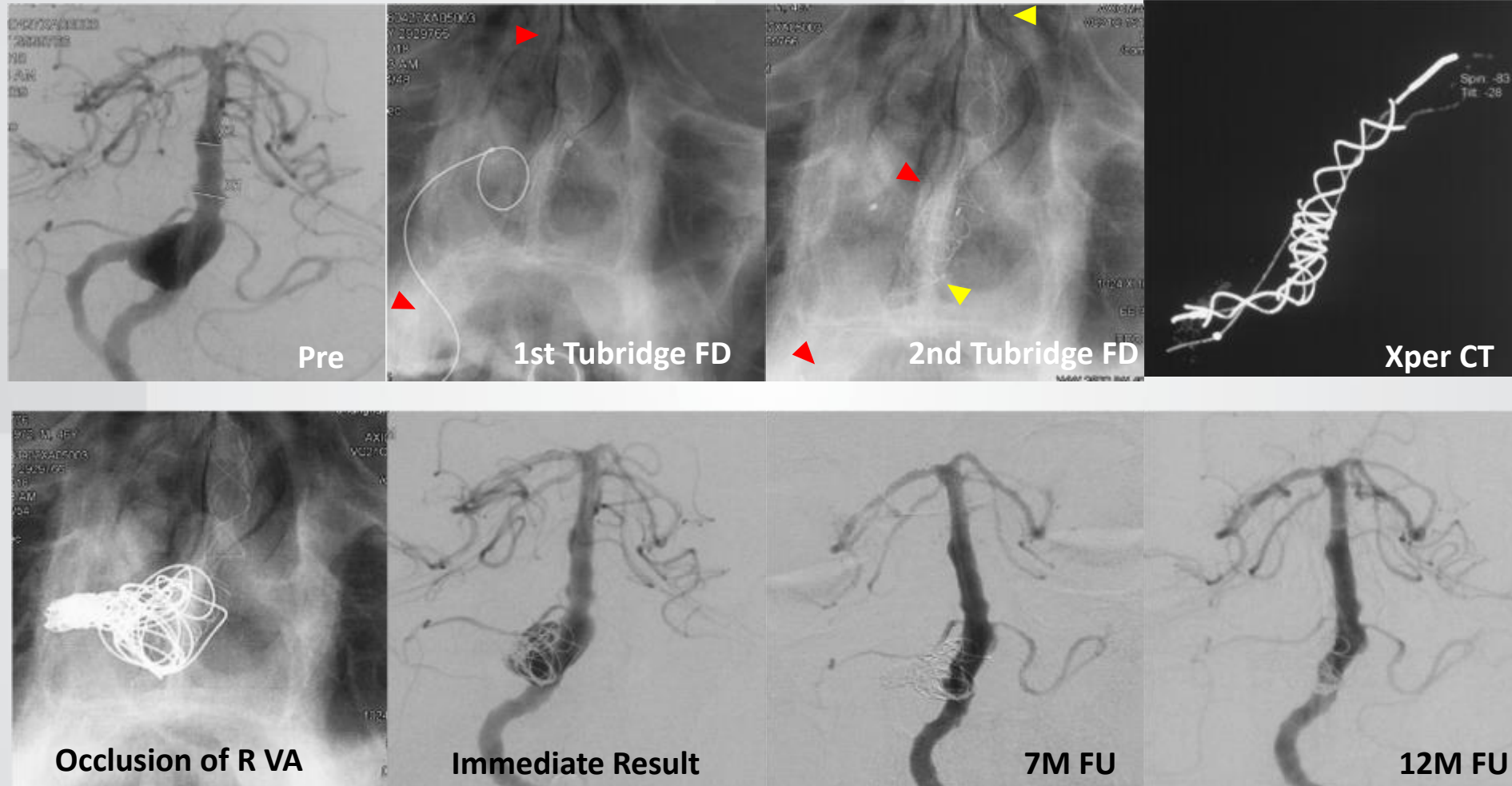
Materials

- Envoy DA guiding catheter
- Headway 21 micro-catheter
- Echelon-10 micro-catheter
- Traccess 14 micro-wire
- LVIS stent
- Orbit coils





Follow Up

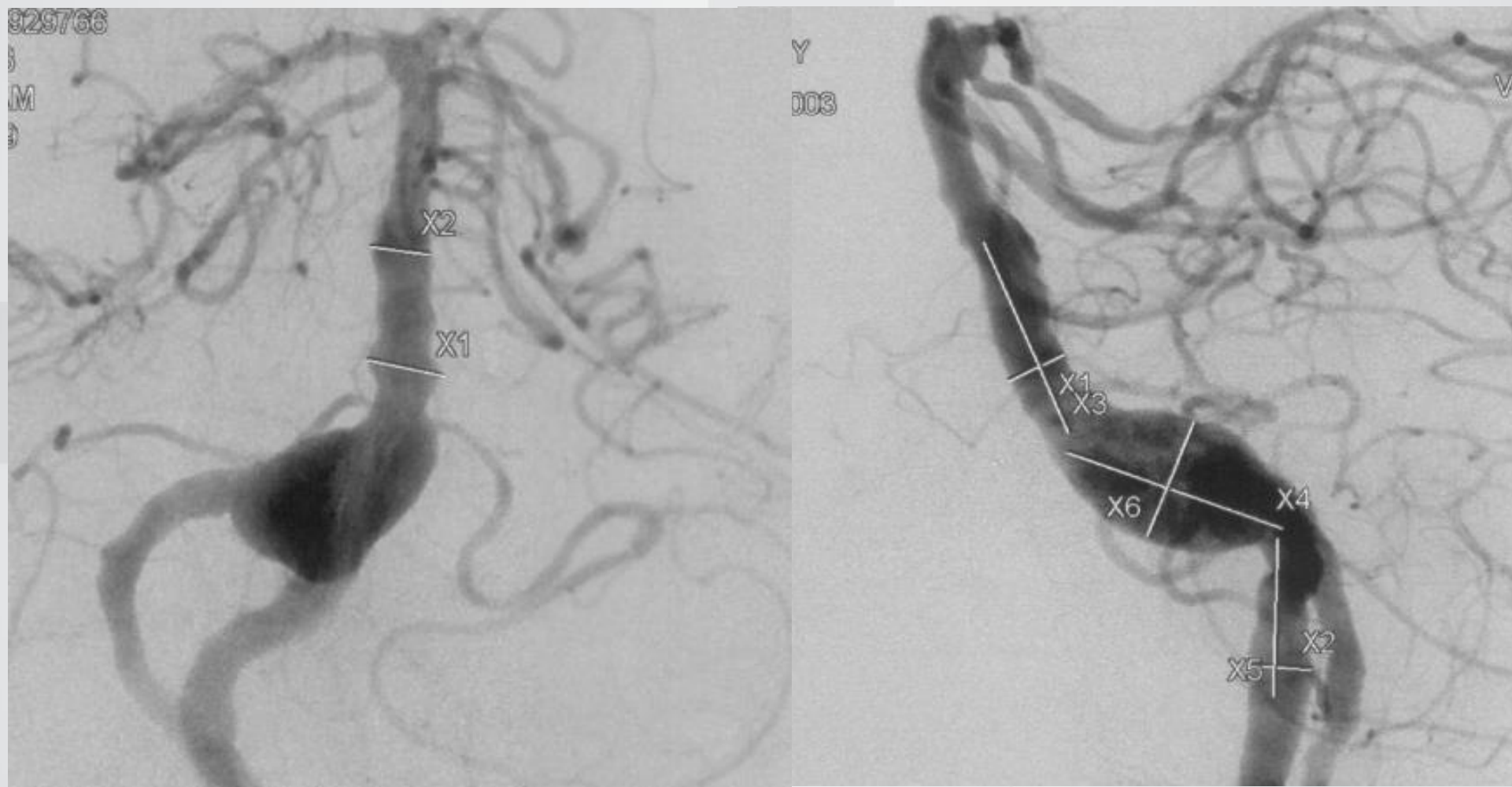


PATIENT 4

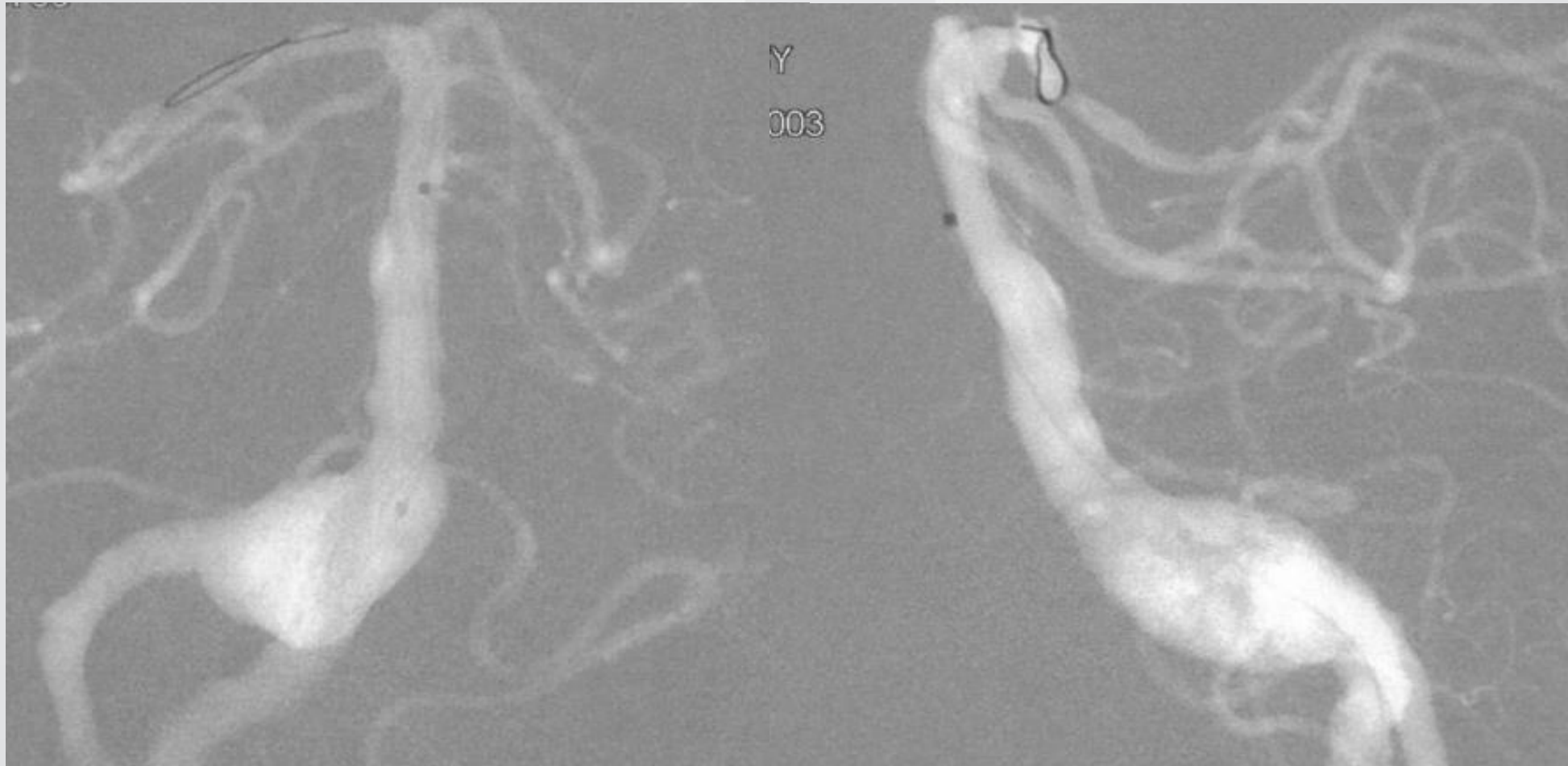- **46 yo, Male**
- **Dizziness for 10 Days**
- **PE : (-)**
- **Basilar artery aneurysm**
- **TEG : AA 87.6%, ADP 94.3%**



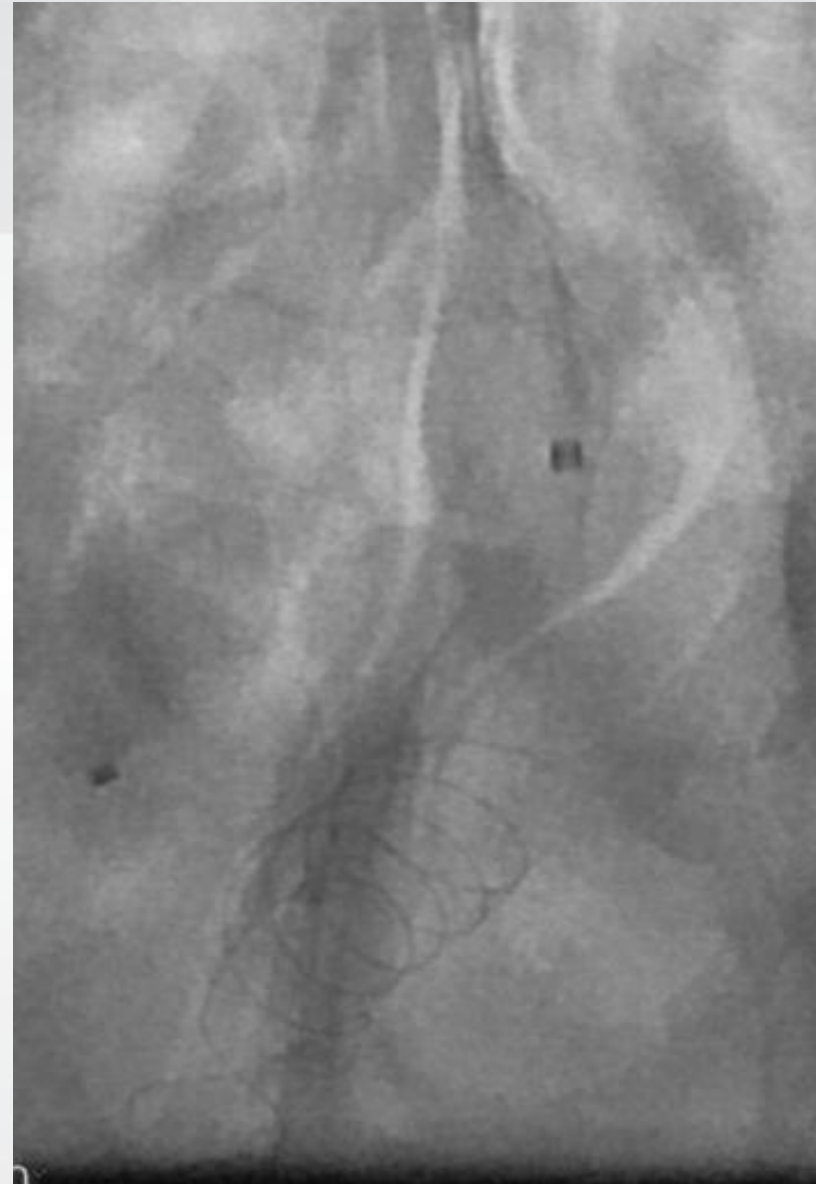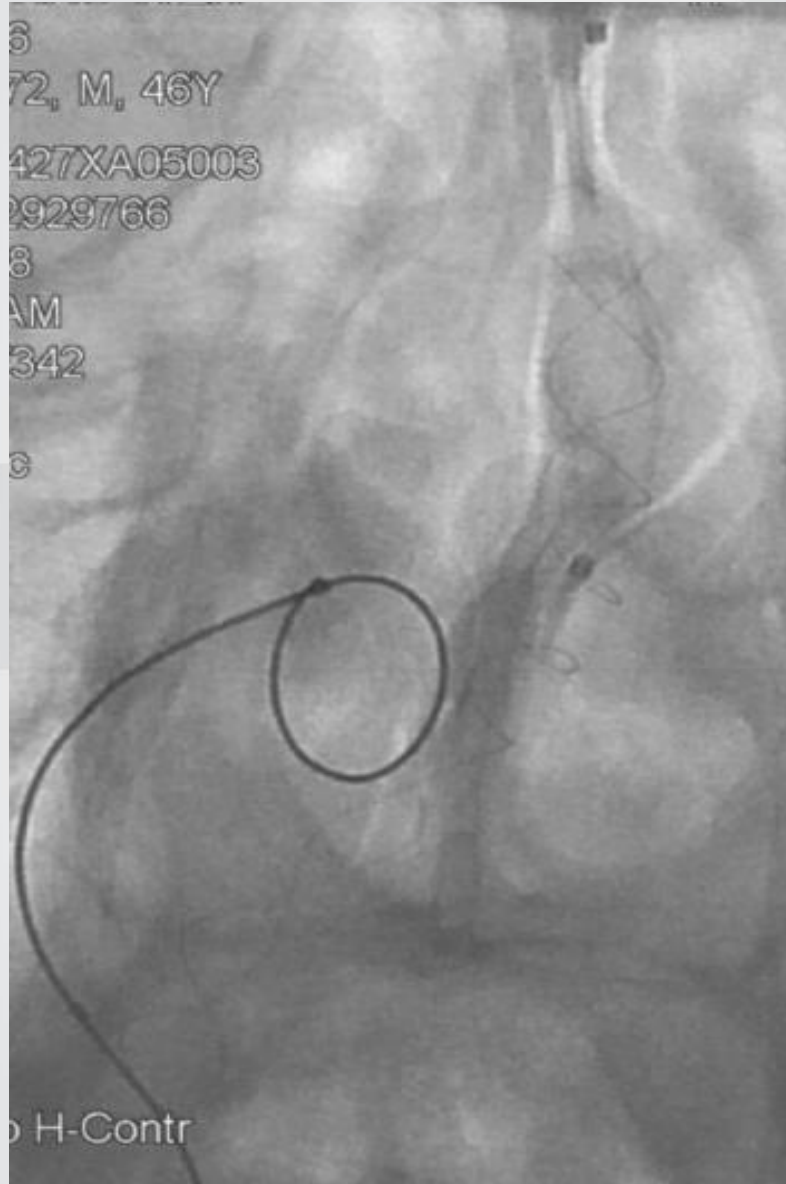
Size: 11.22*15.38mm



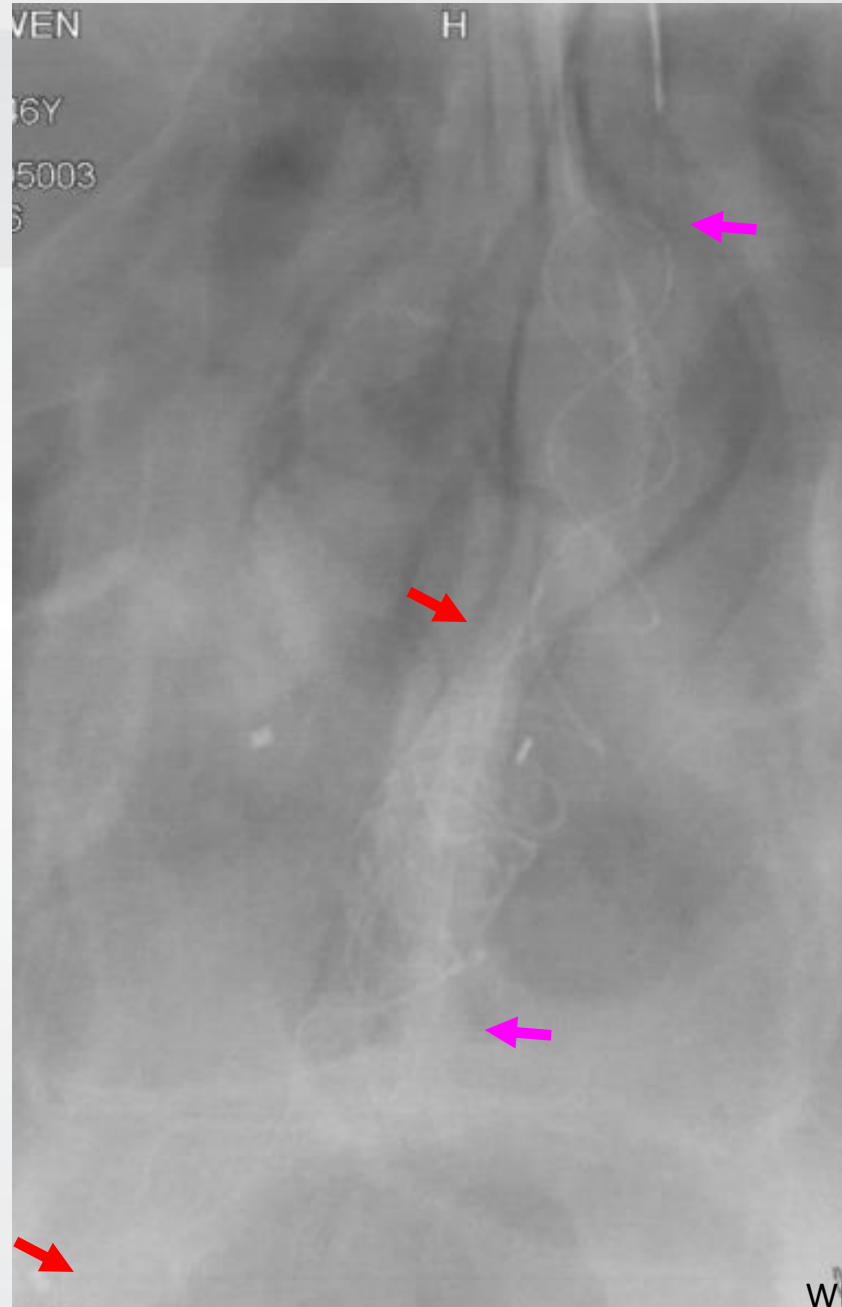
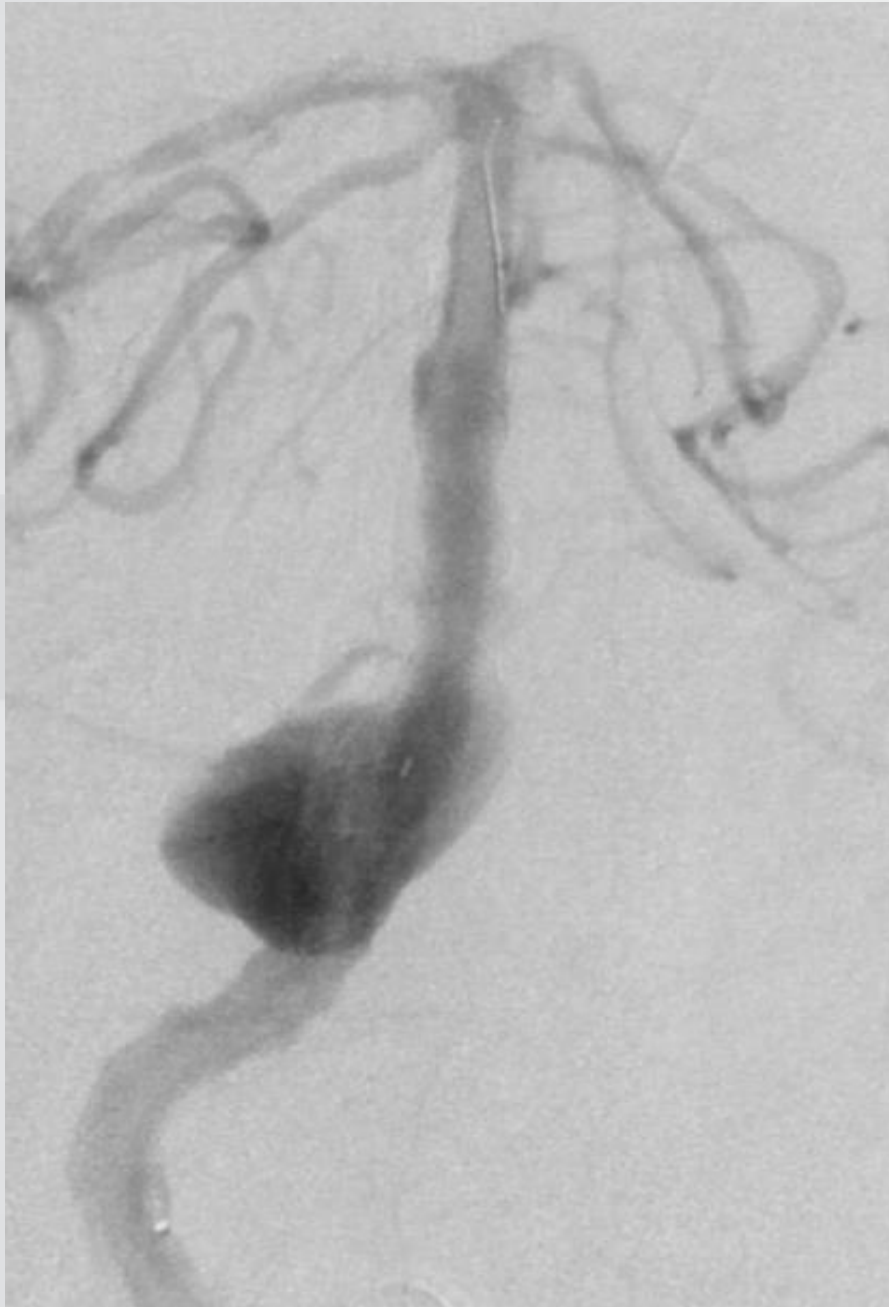
Microcatheter in Position



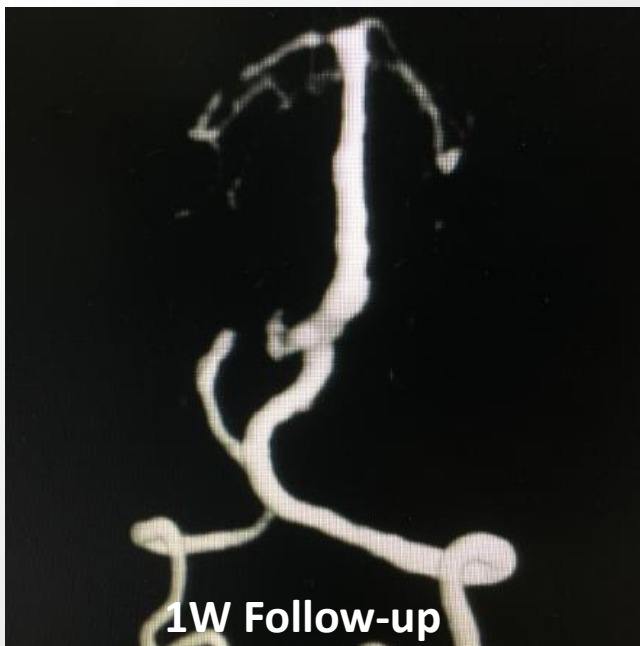
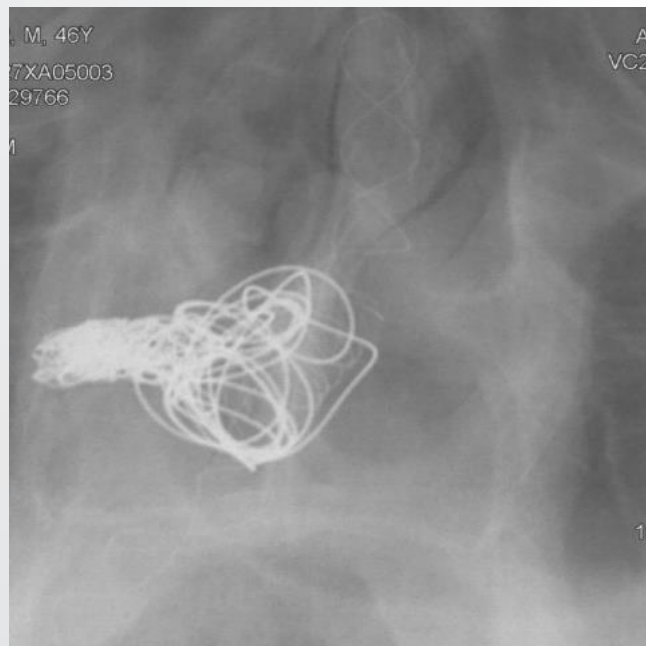
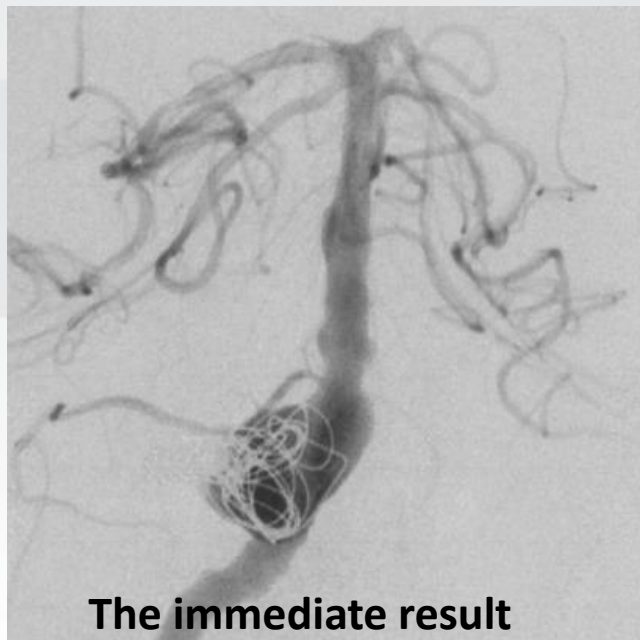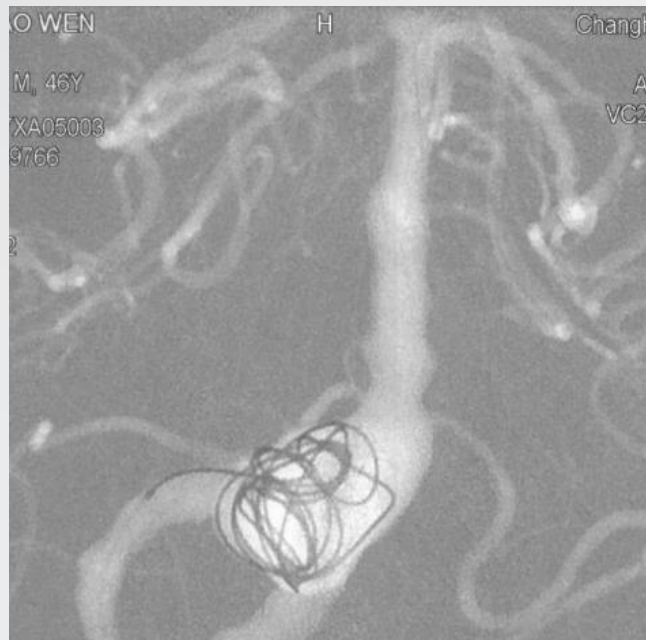1st Tubridge (6/45) Deployment



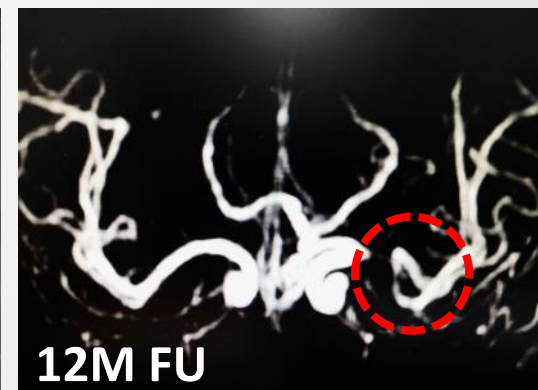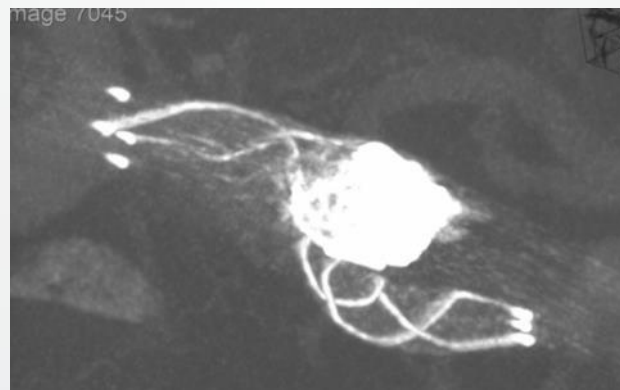
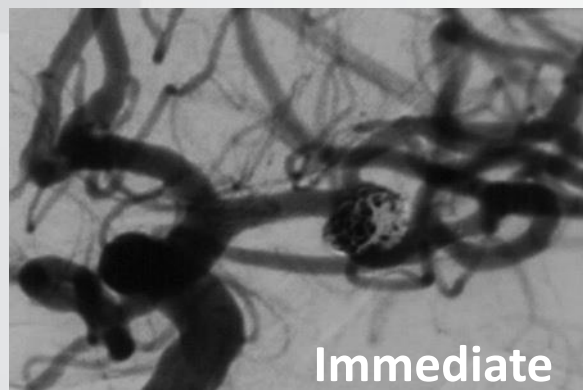
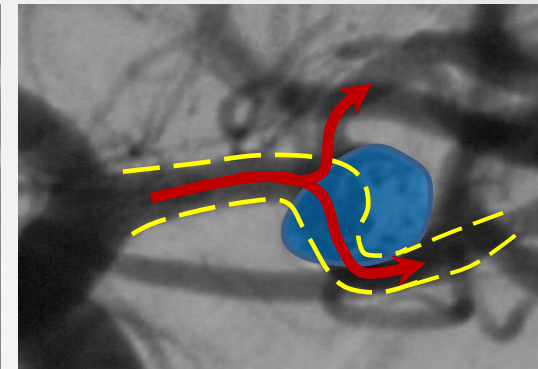
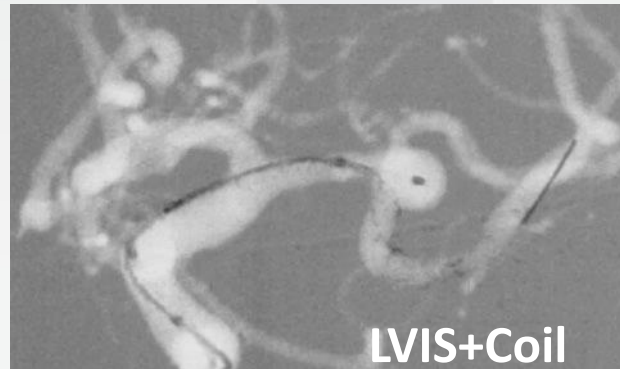
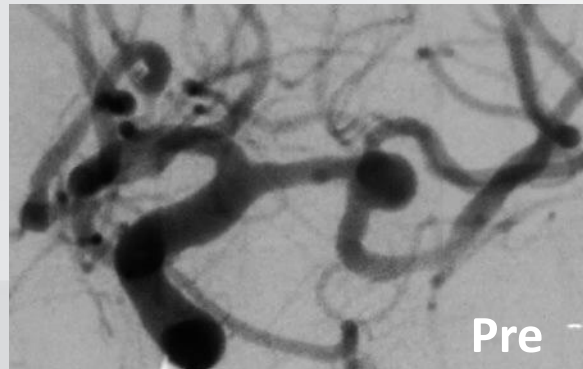
2nd Tubridge (6/35) Deployment




Contralateral vertebral artery occlusion



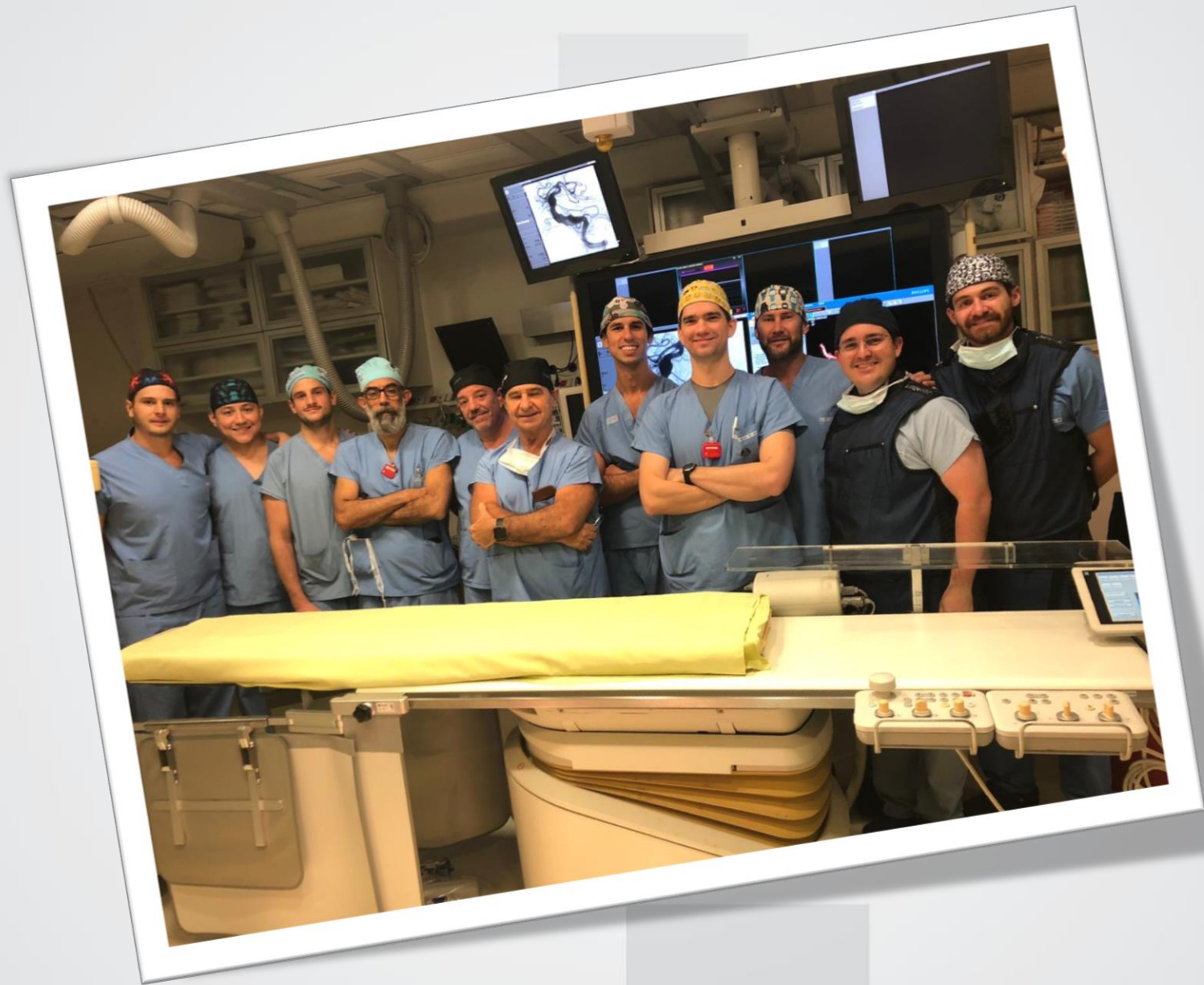Follow Up





WLNC 2018

BUENOS AIRES CASES



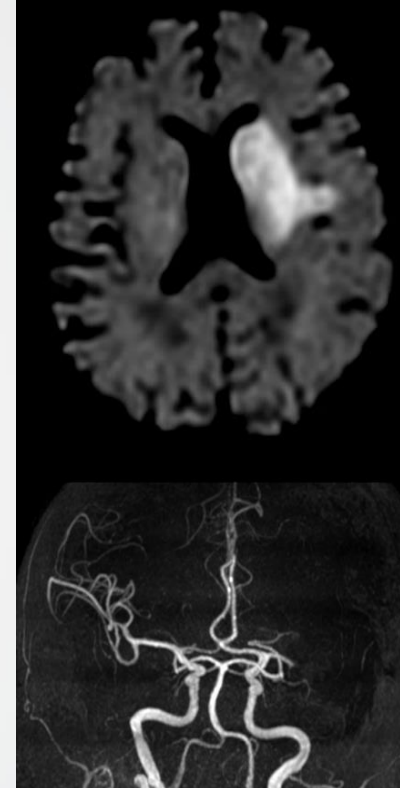
PATIENT 1

SM. Female, 56y.o.
HBP, DBT

04/26/2018: 4:00 PM onset : Stroke Nihss 18 pts

- Patient arrived To Clinica Sagrada Familia at 01:50 AM
MRI (04/27/2018; 02:20 PM)
DWI: Left caudate and insular restriction area
AMR: Left M1 MCA occlusion

DSA 02:45 PM
Recanalization 03:04 PM

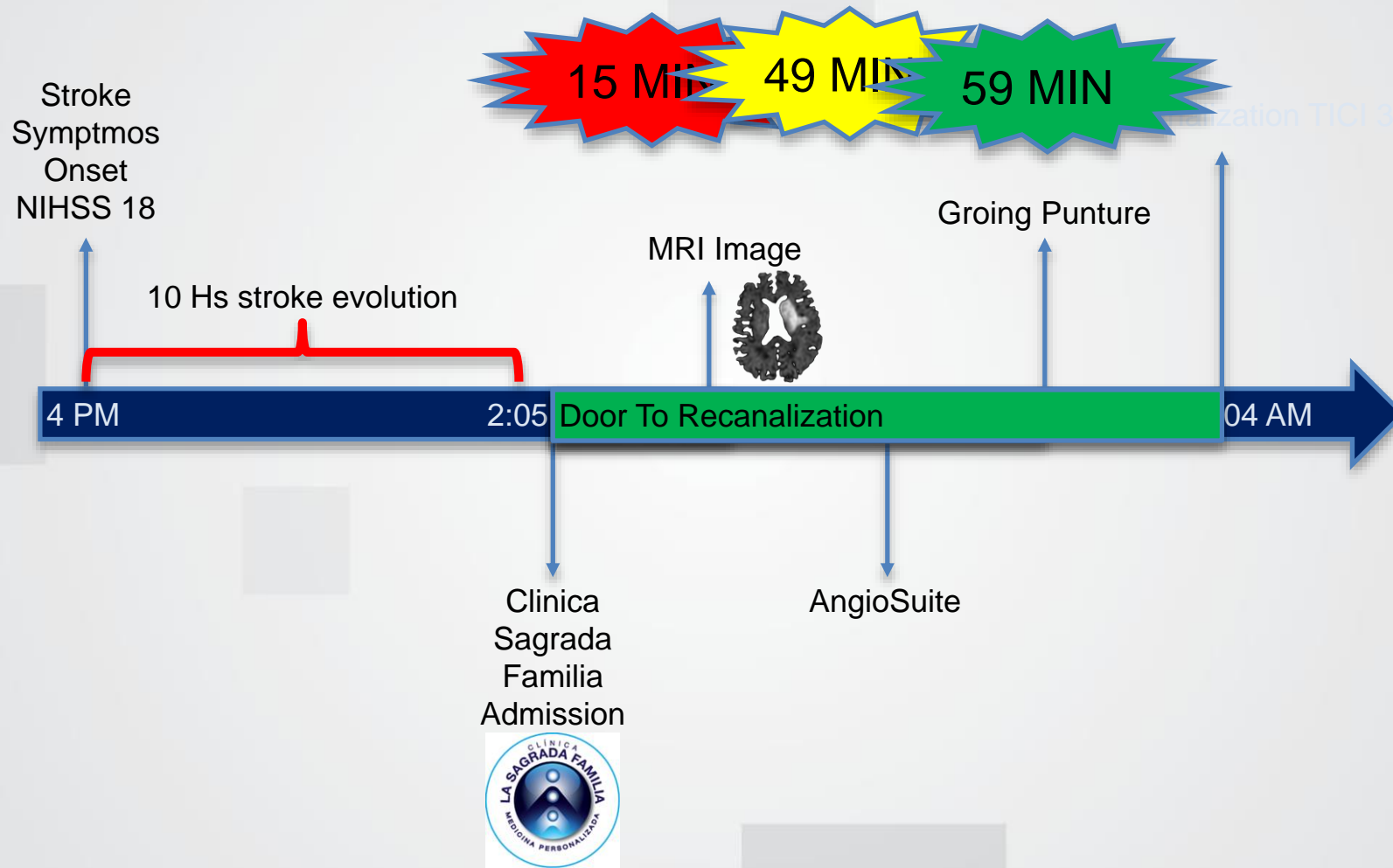


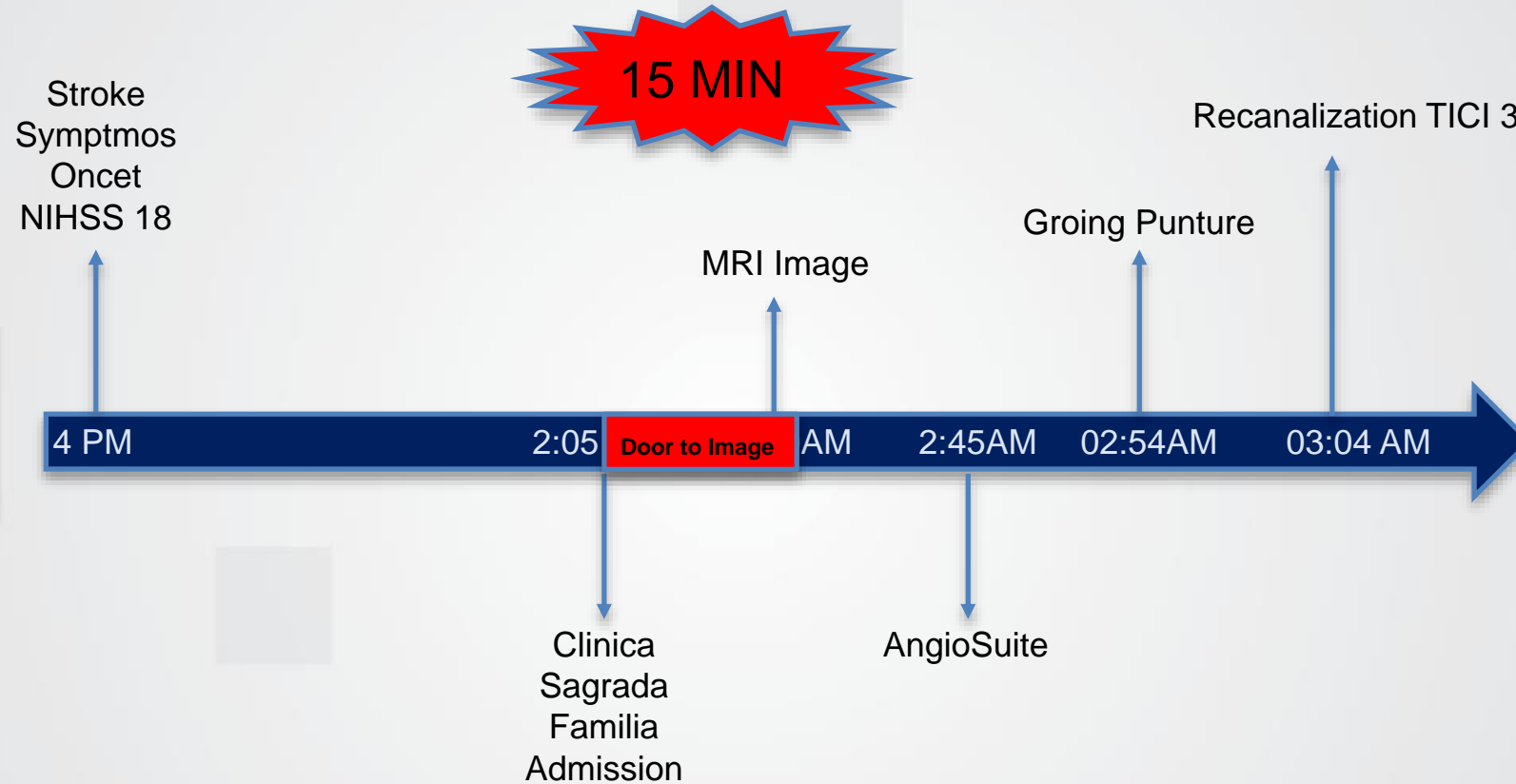
Door to image 15 min

Door to Groin 49 min

Door to recanalization 59 min







DWI

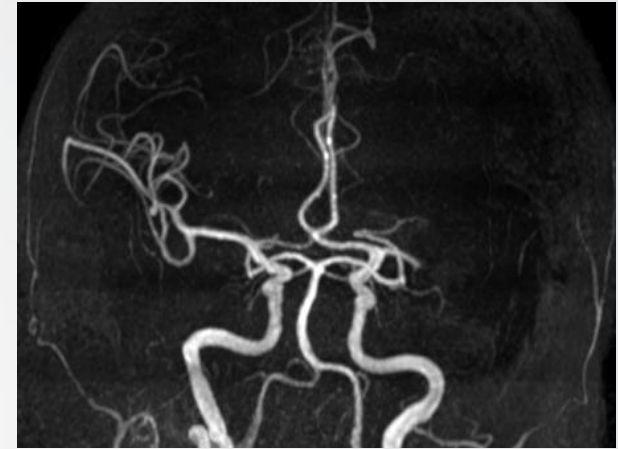
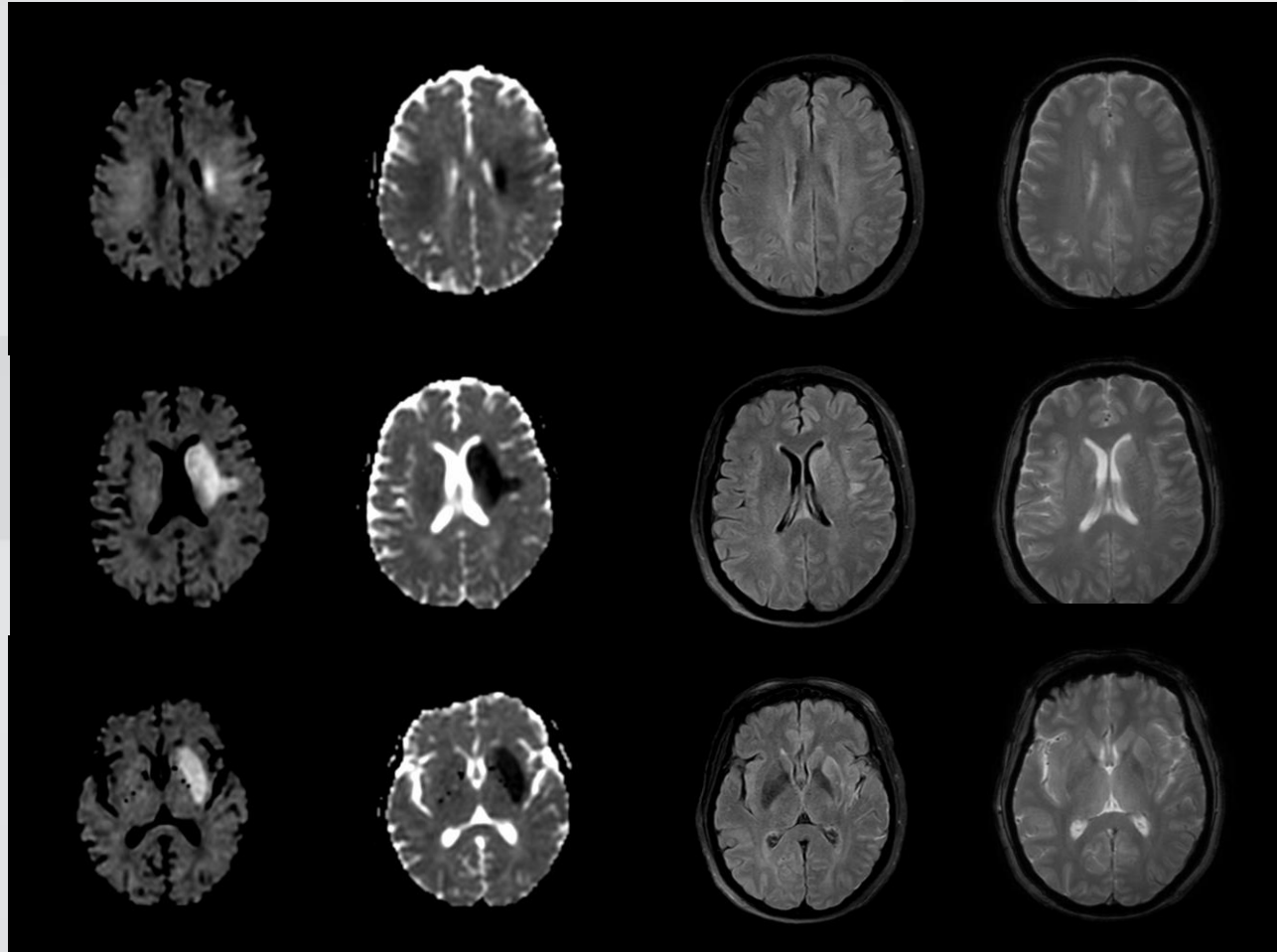
DWI

ADC

FLAIR

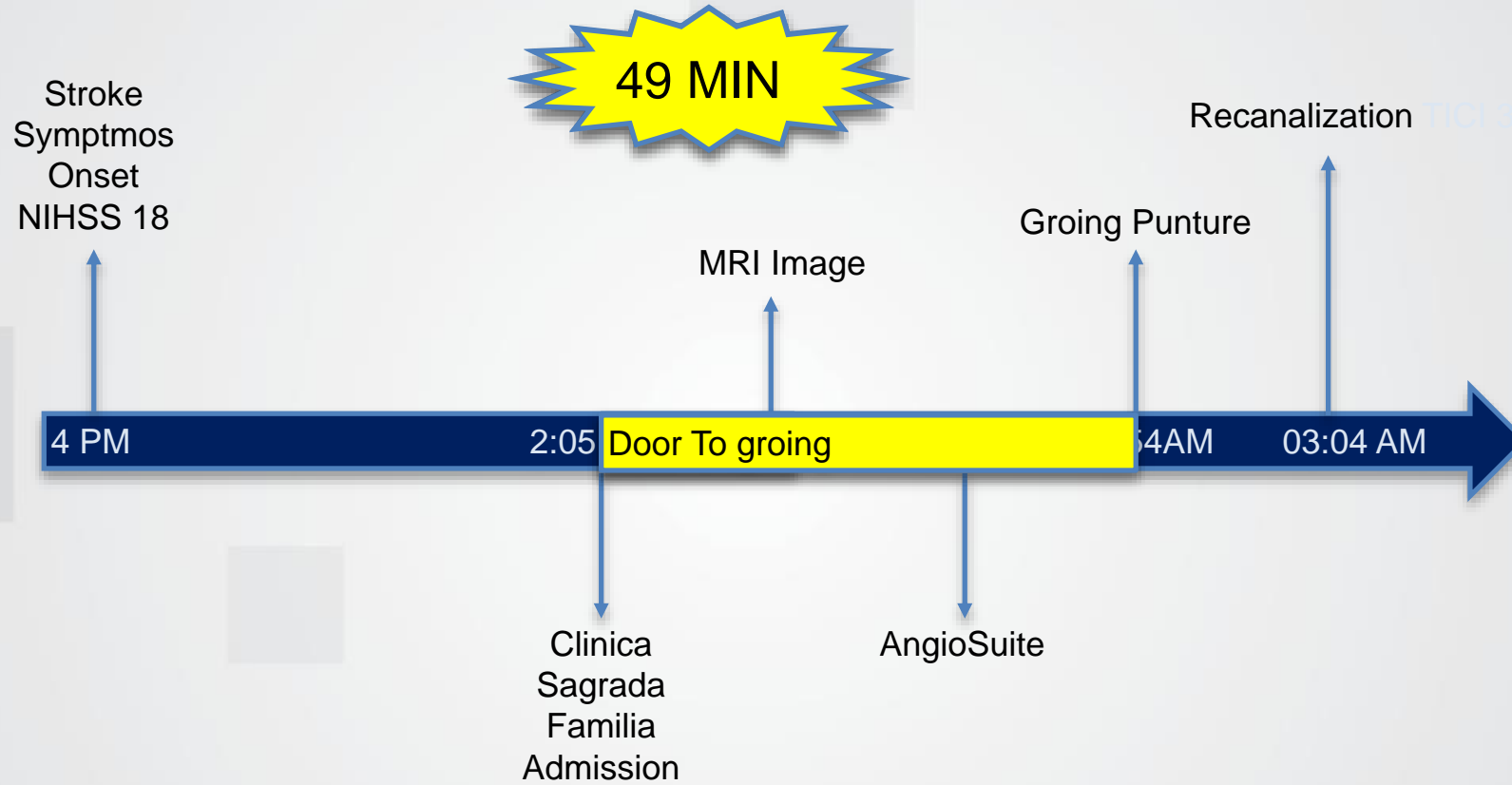
GRE

Diagnostic MRI

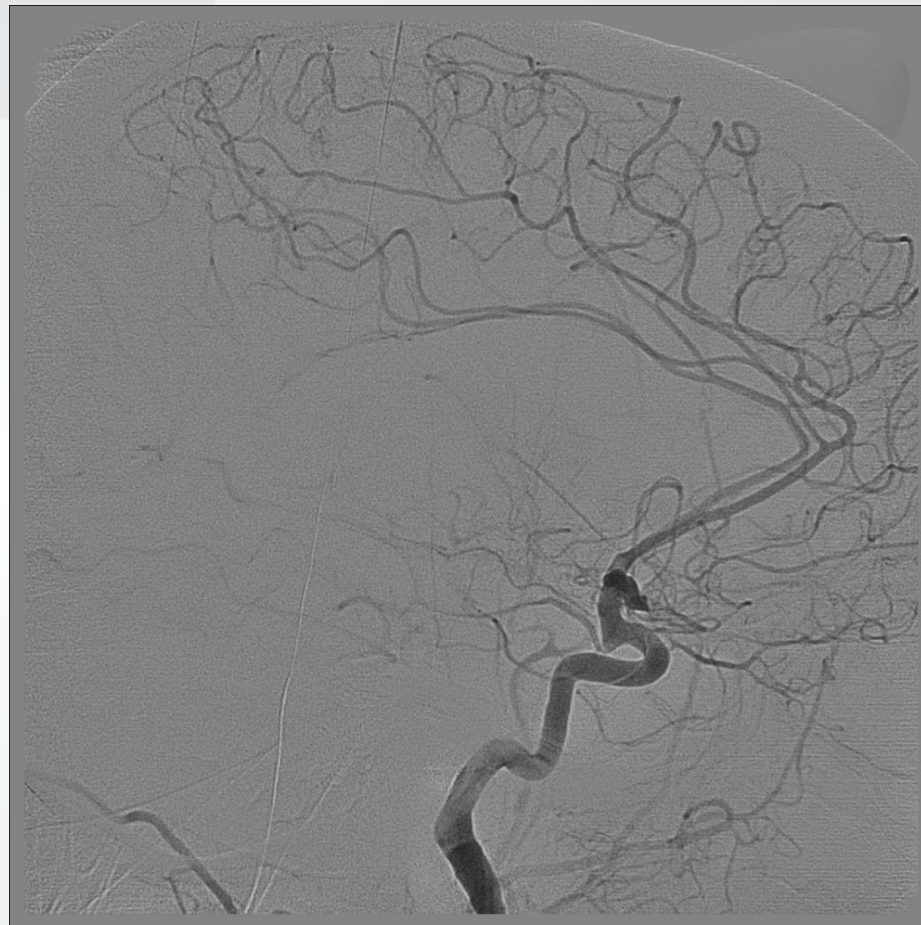
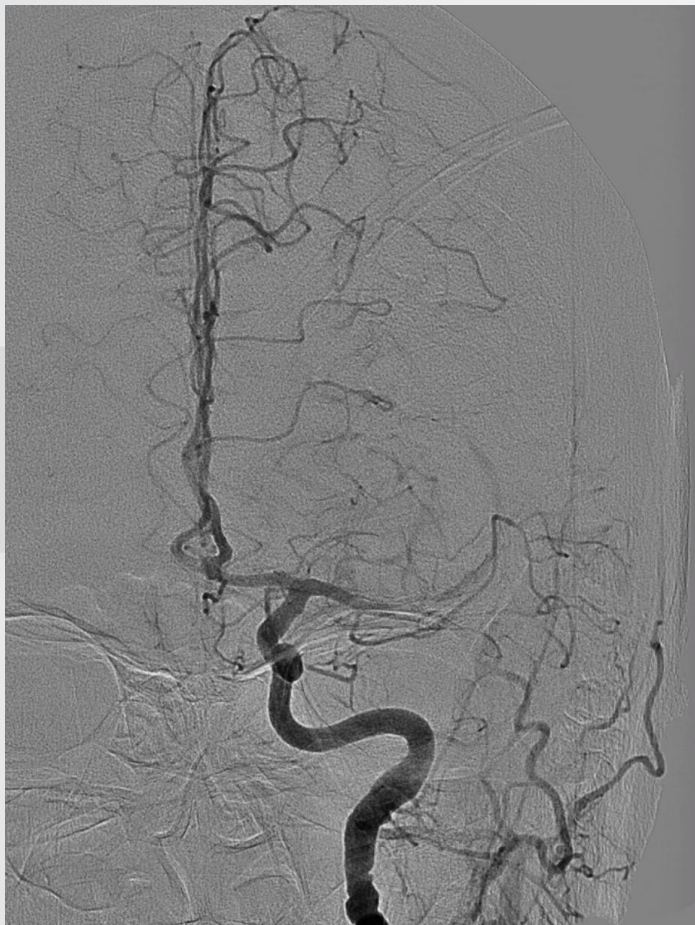

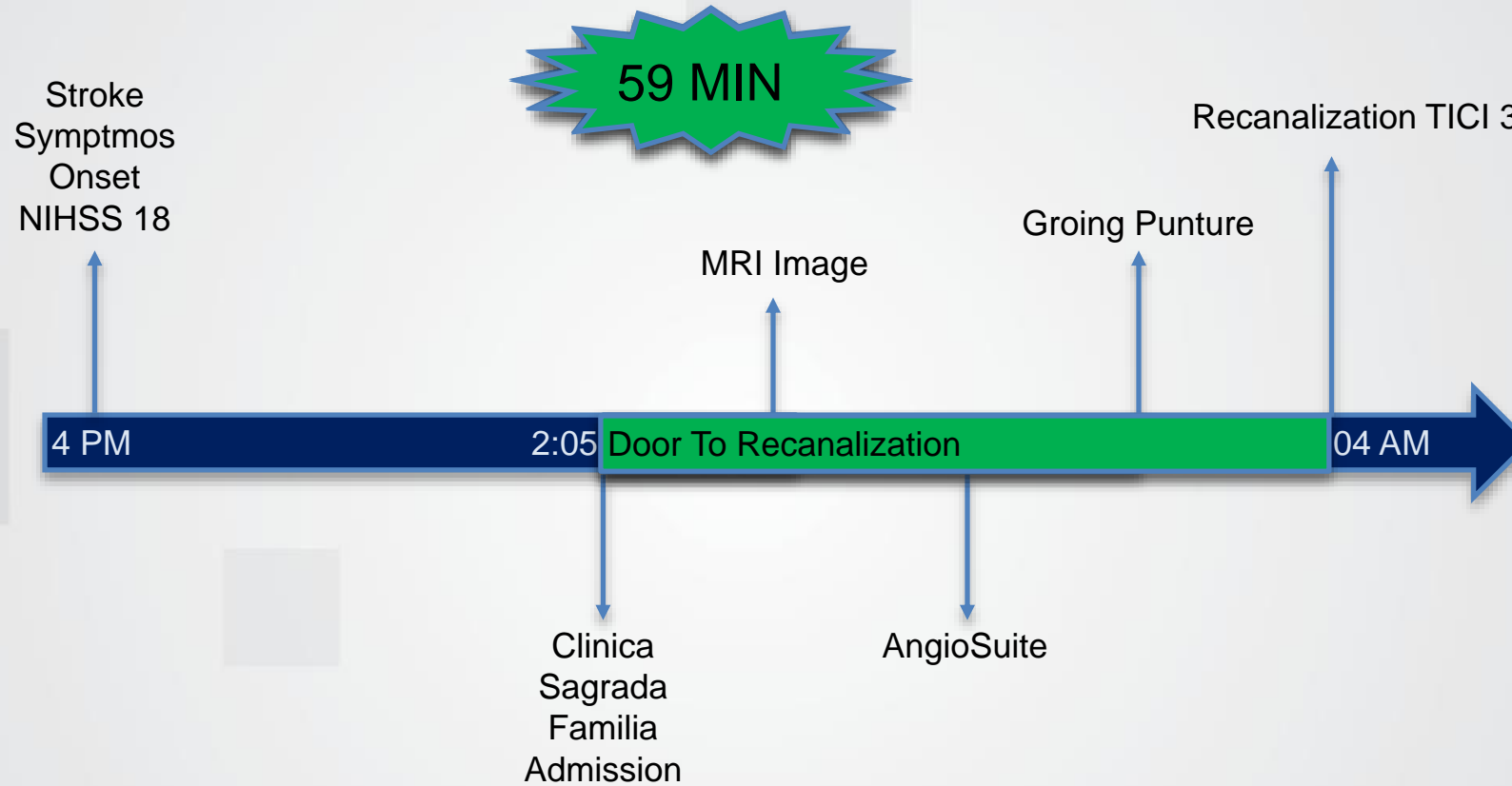
joMRI

Volume 15 cm3
Aspects 6

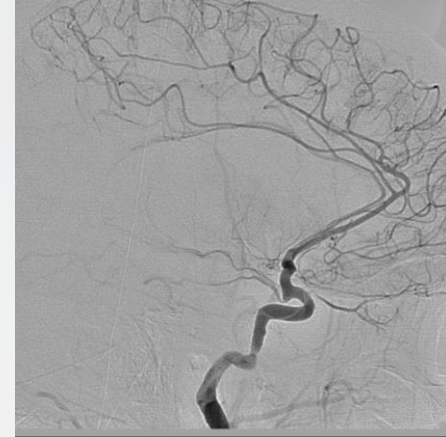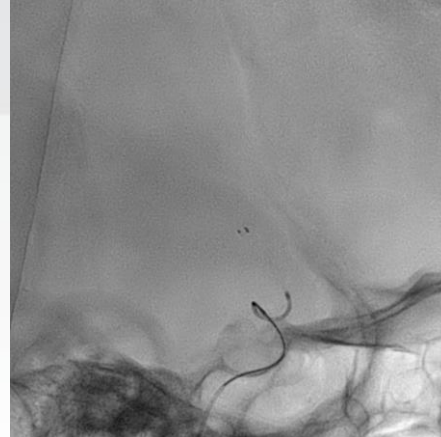
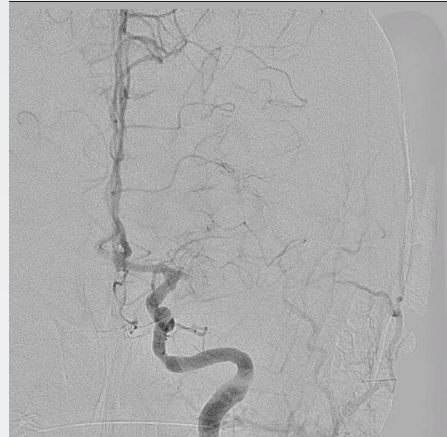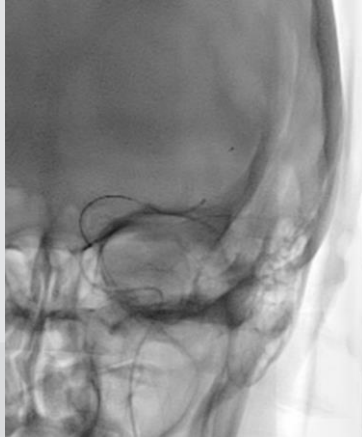


TREAT TIC1b

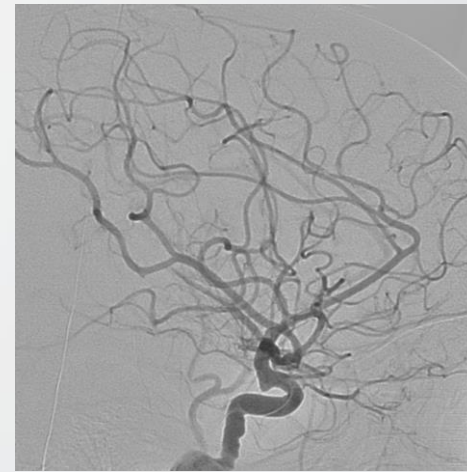
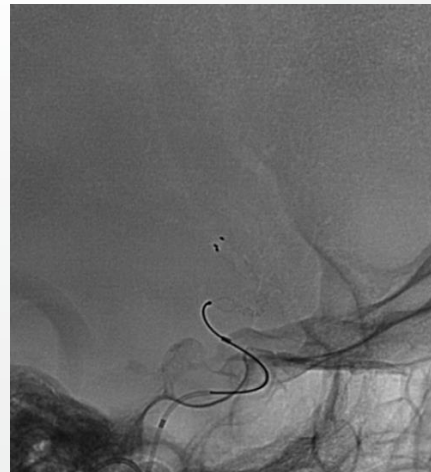
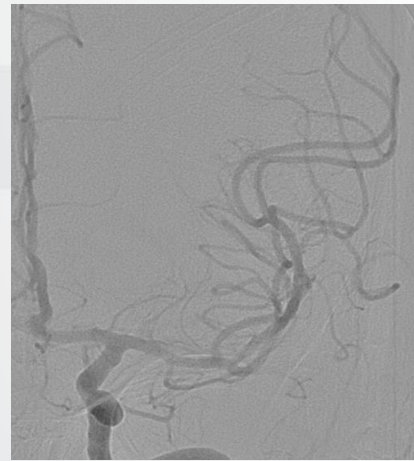
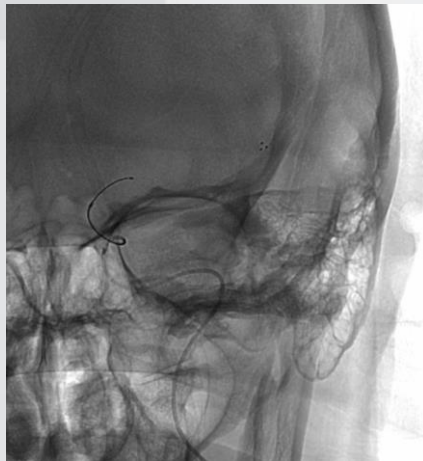


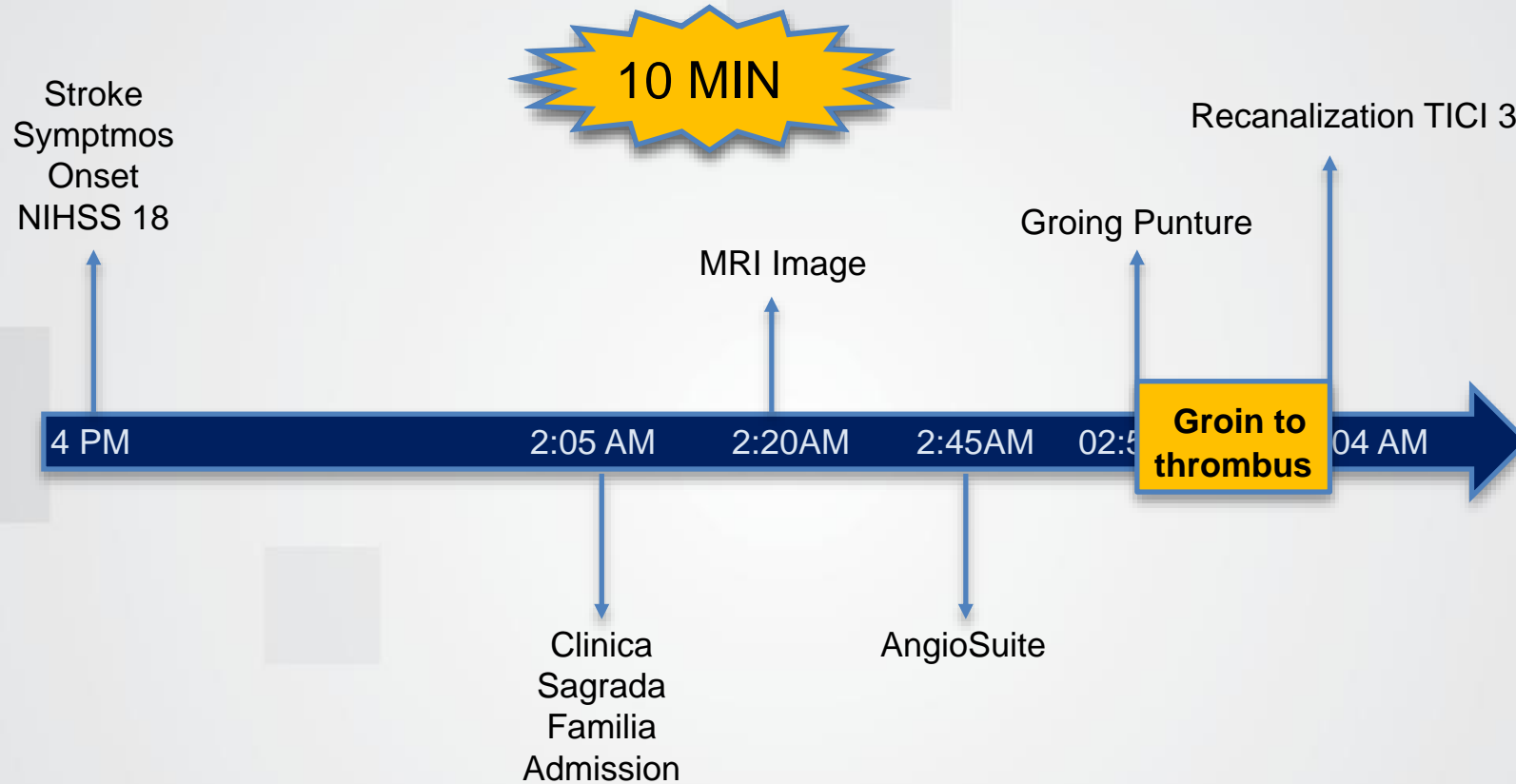
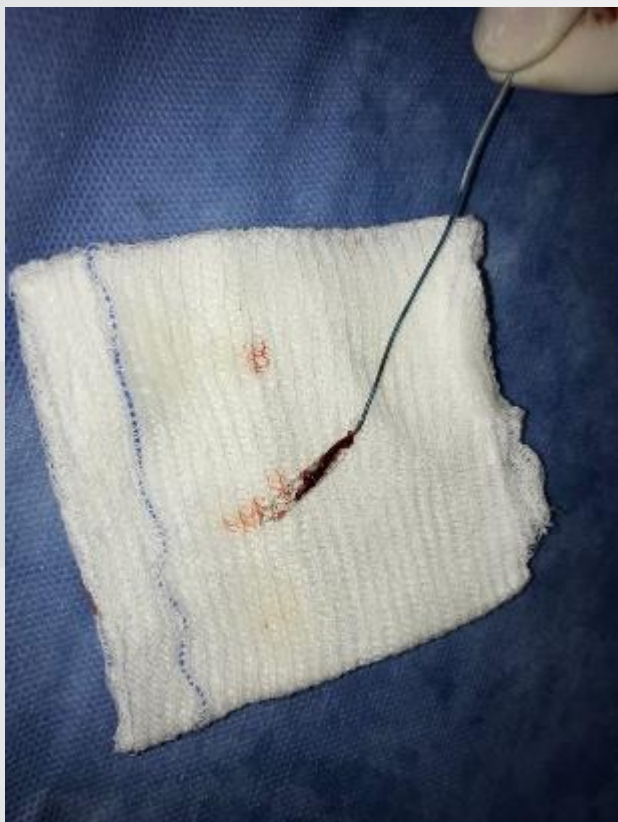First pass solitaire 4x20



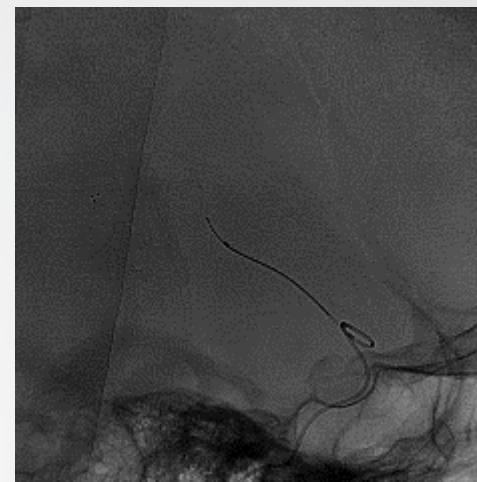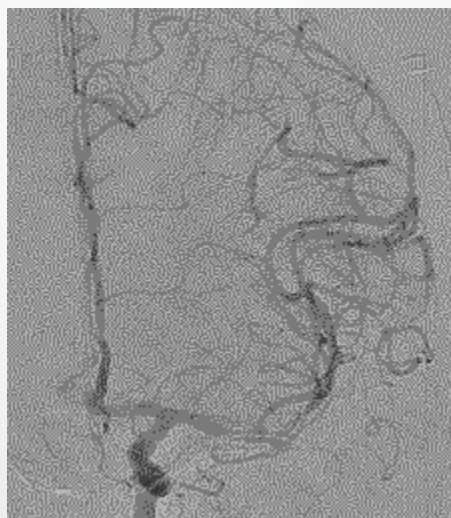
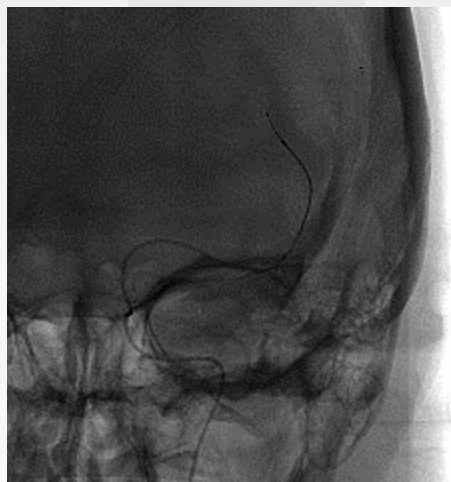Second pass solitaire 4x 20



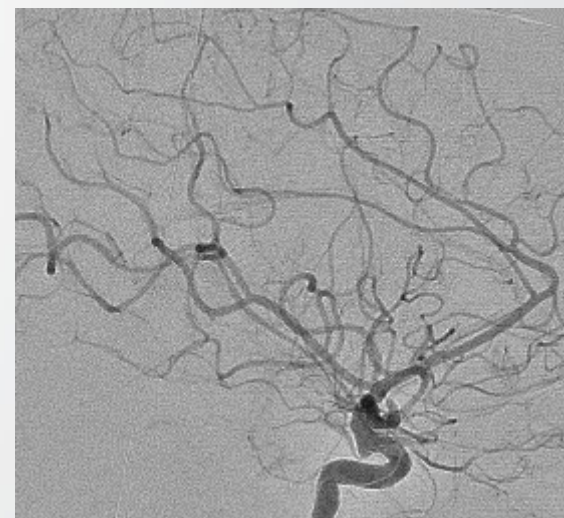




After second pass



Third pass solitarie 3 x20

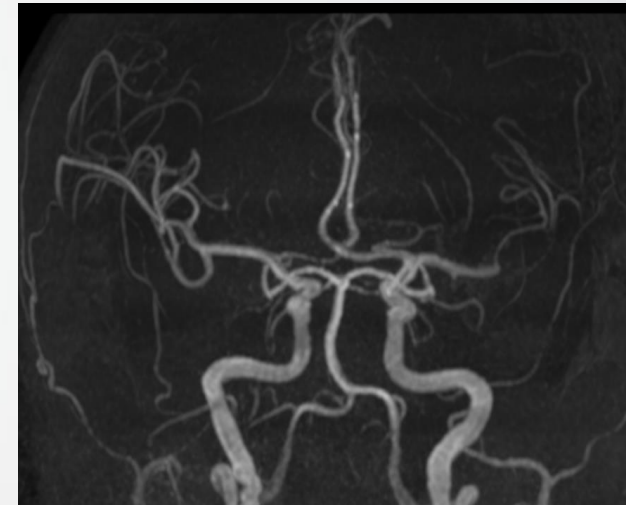
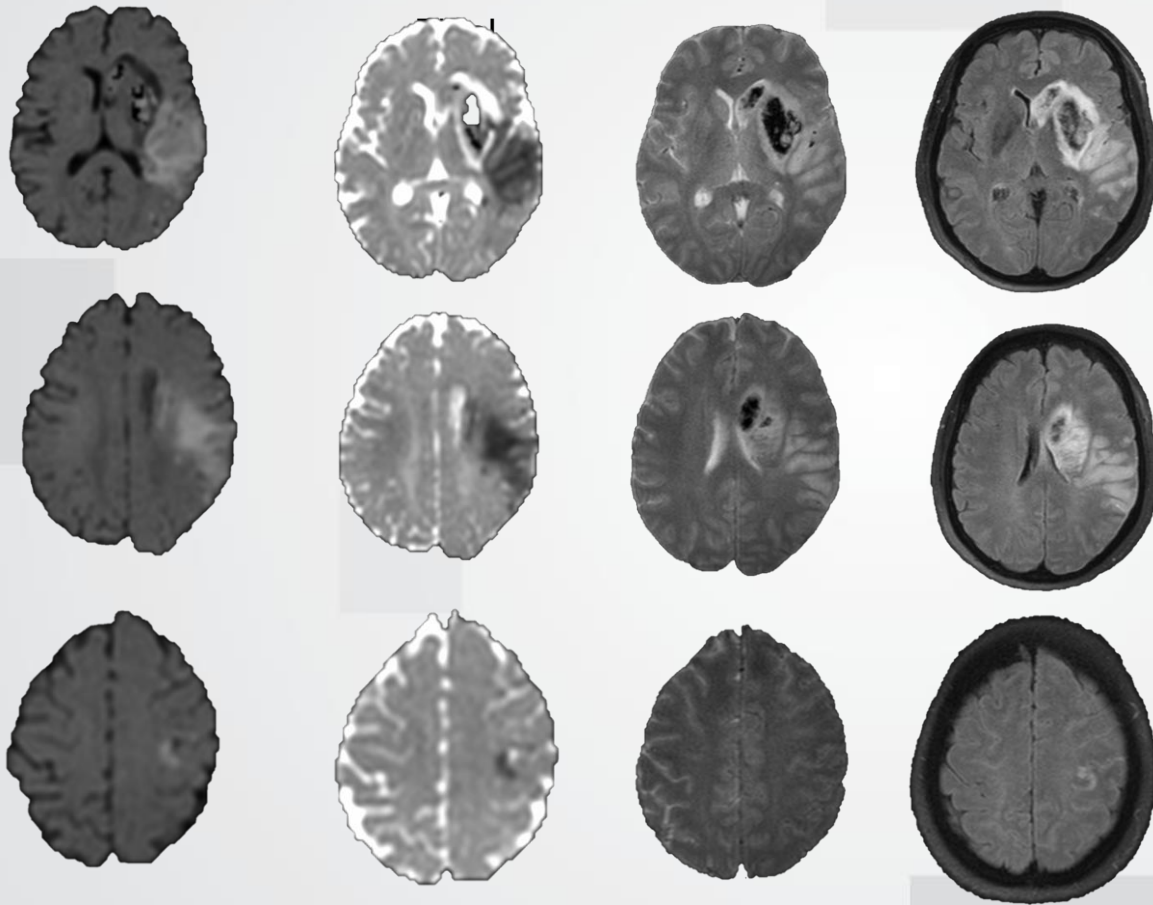


DWI

FLAIR

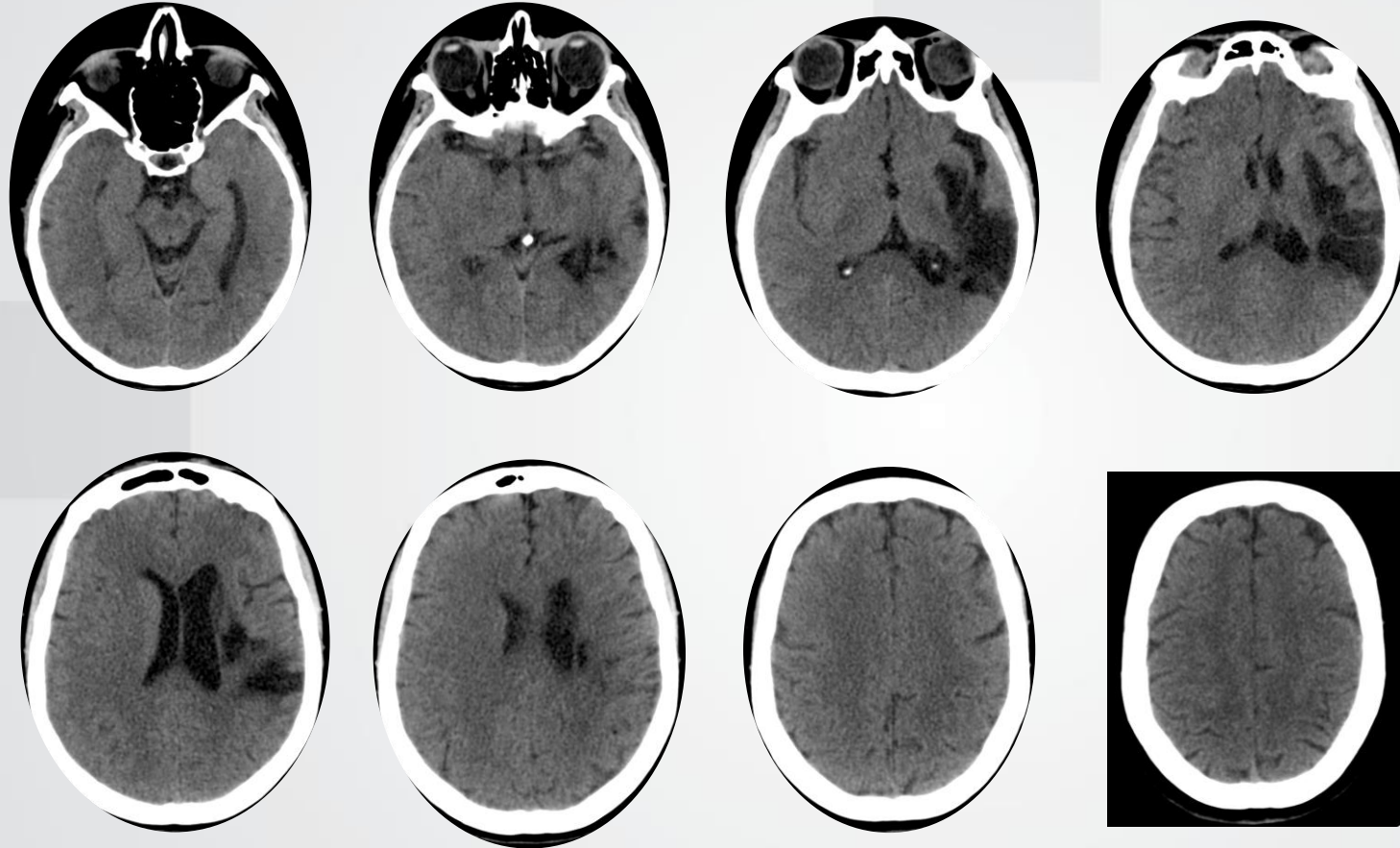
GRE

48 hours Control MRI



AngioMRI

10 Months FUP CT



NIHSS 7

mRs 3



PATIENT 2

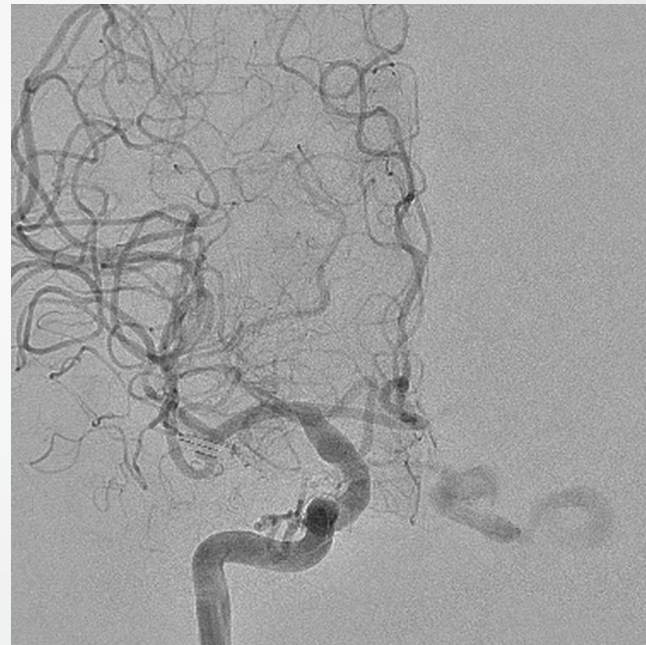**PL. Fem, 72 y.o.
HBP. SAH 1991, R-MCA clipped.**

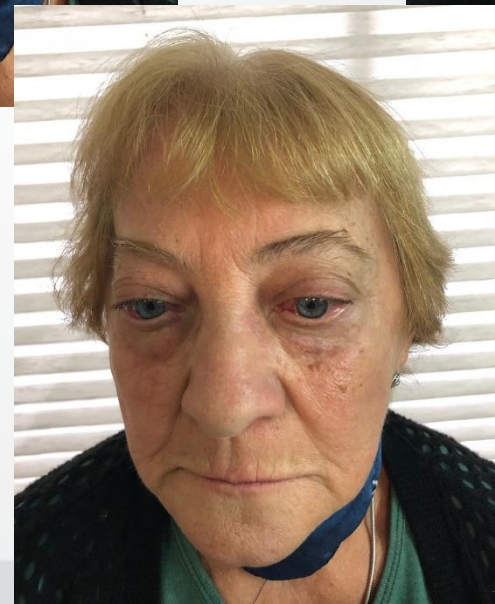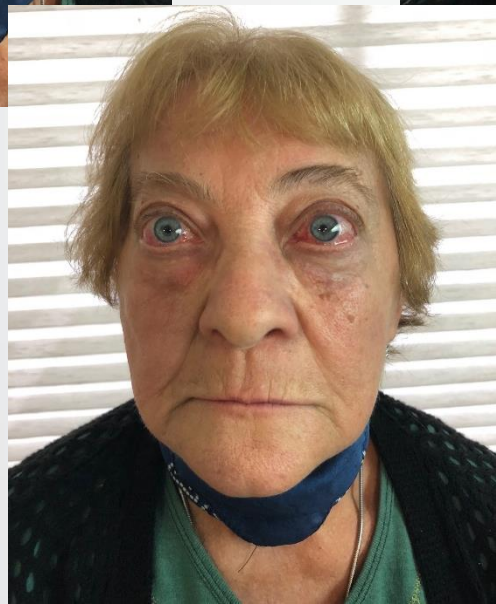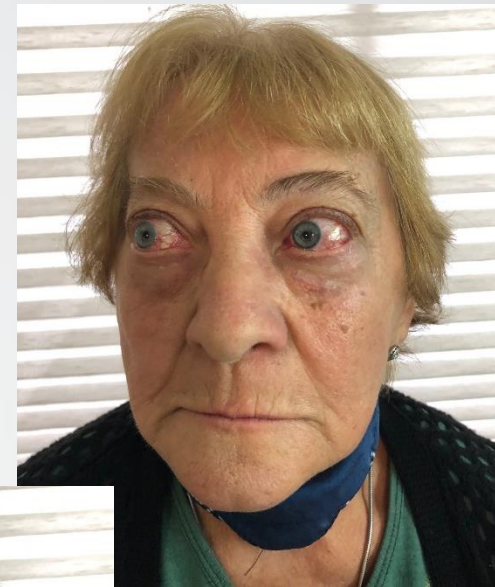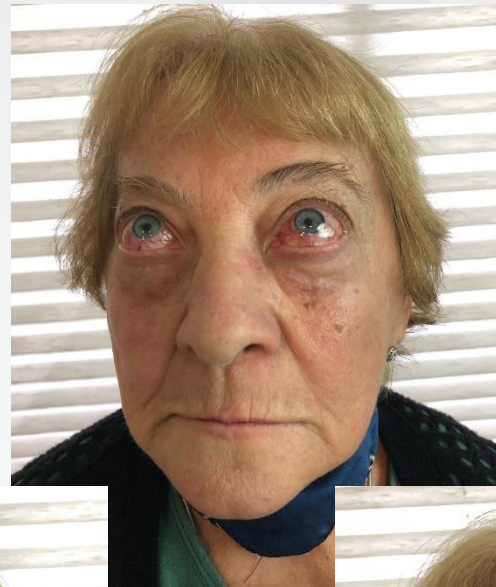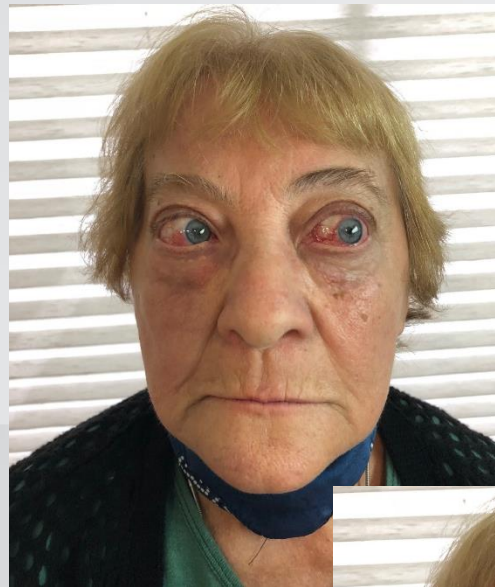Exophthalmos, proptosis, ocular pain and horizontal diplopia in left eye since september 2017.

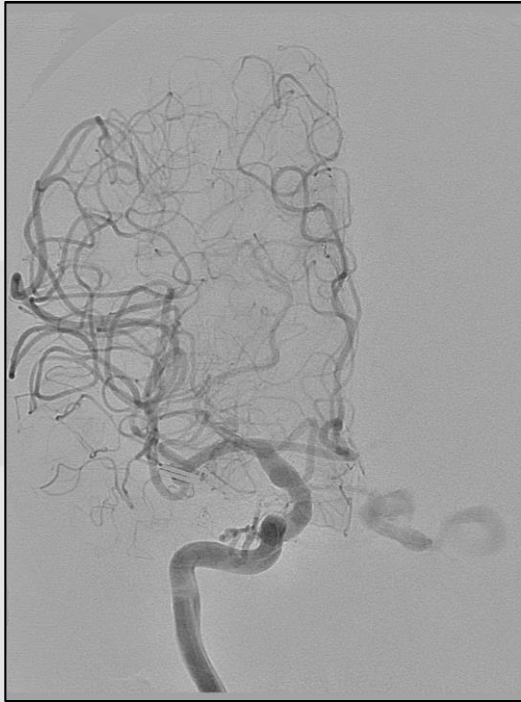**DSA:
R-small MCA bifurcation remnant aneurysm
L-small MCA bifurcation aneurysm**

**Left indirect CC fistula
Treatment through right inferior petrosal sinus
Treatment through left facial vein failed**

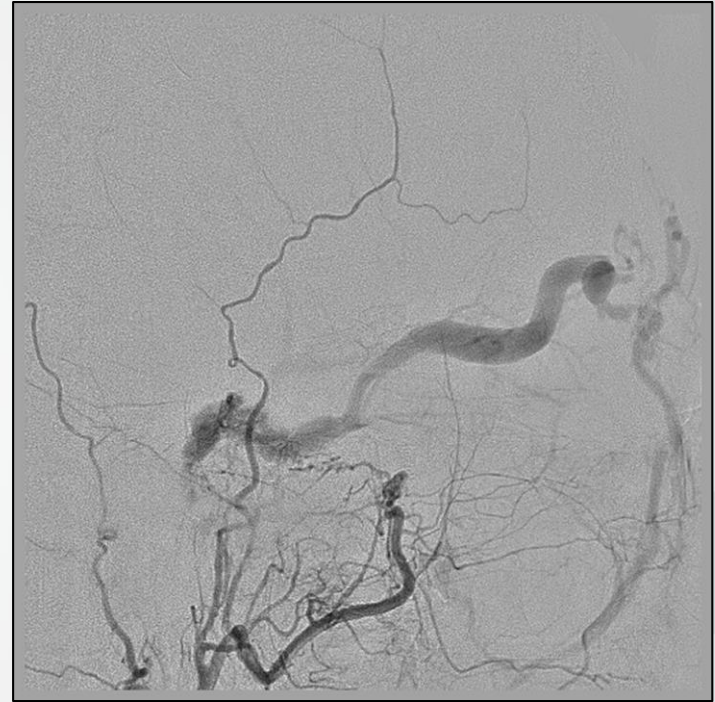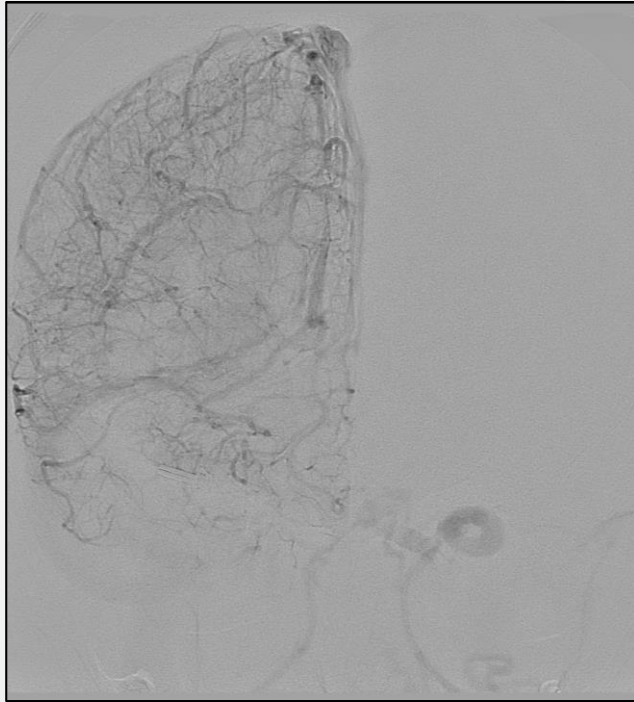
Strategy: Direct access + endovascular





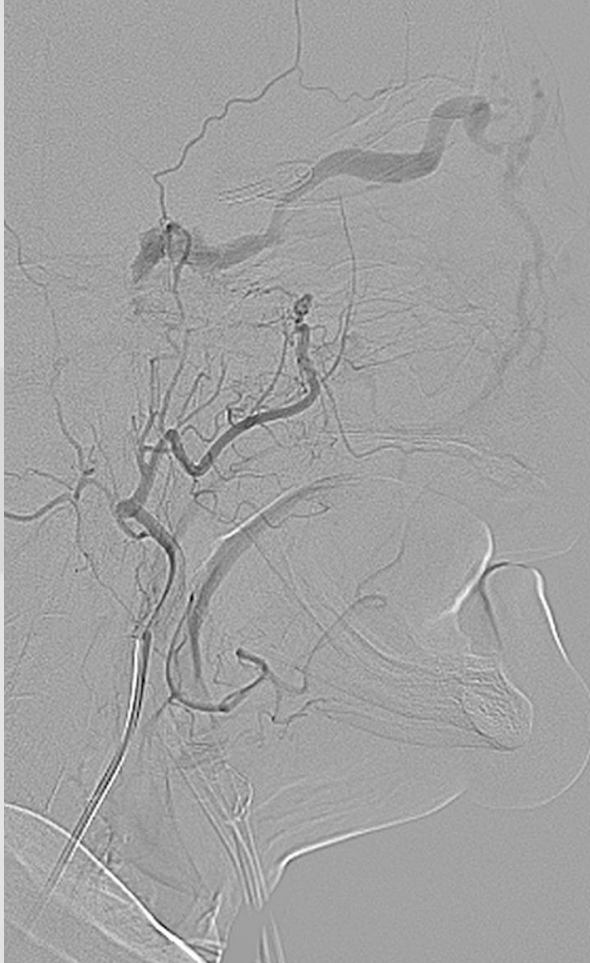


R-ICA

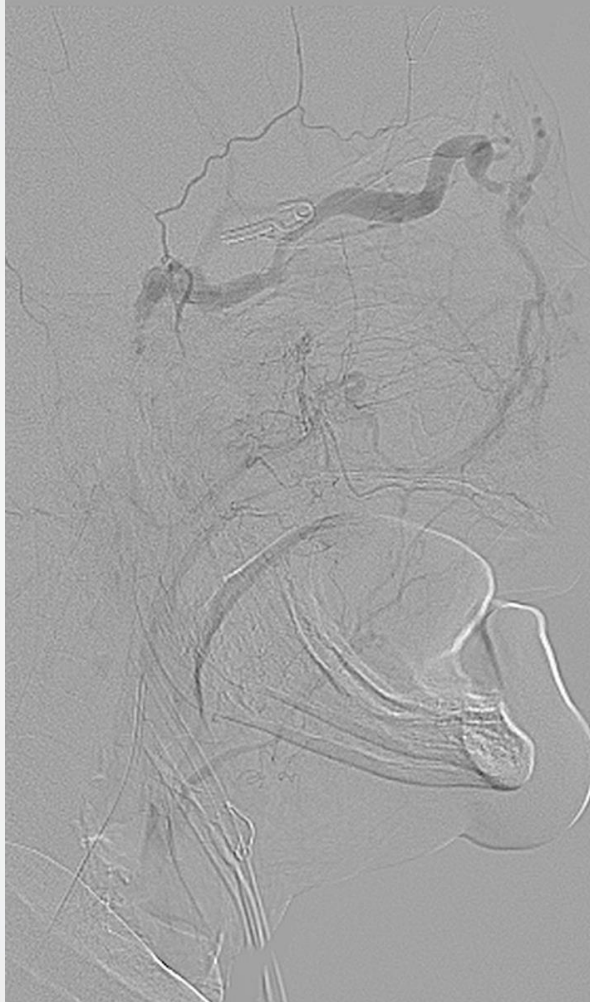


R-ECA

PRE TREATMENT

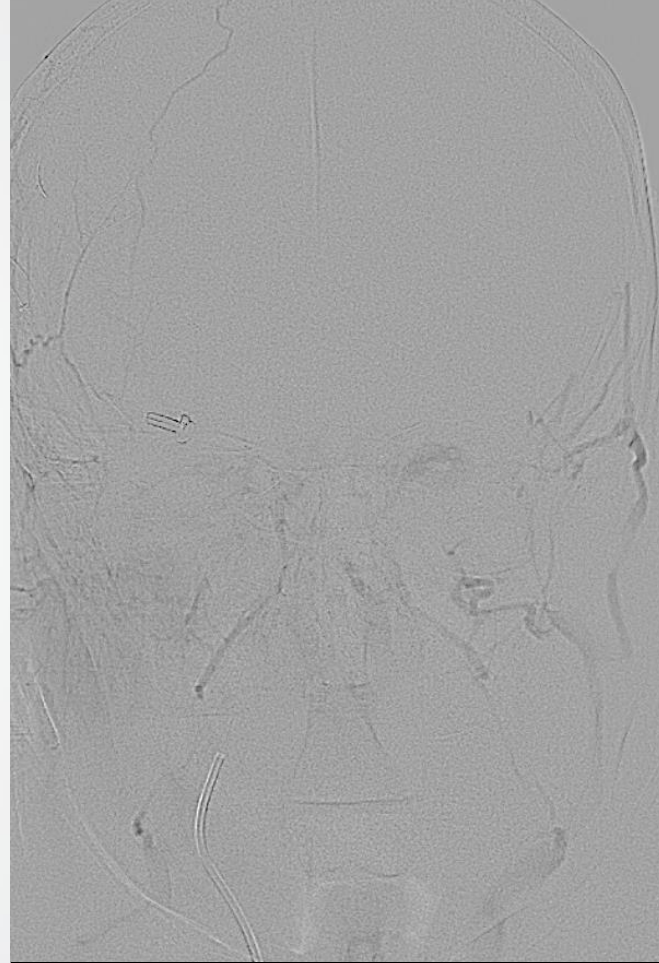


R-ECA



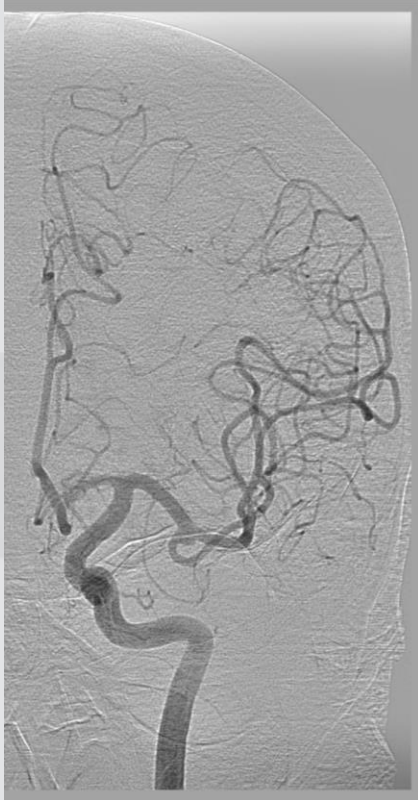R-ECA

PRE TREATMENT

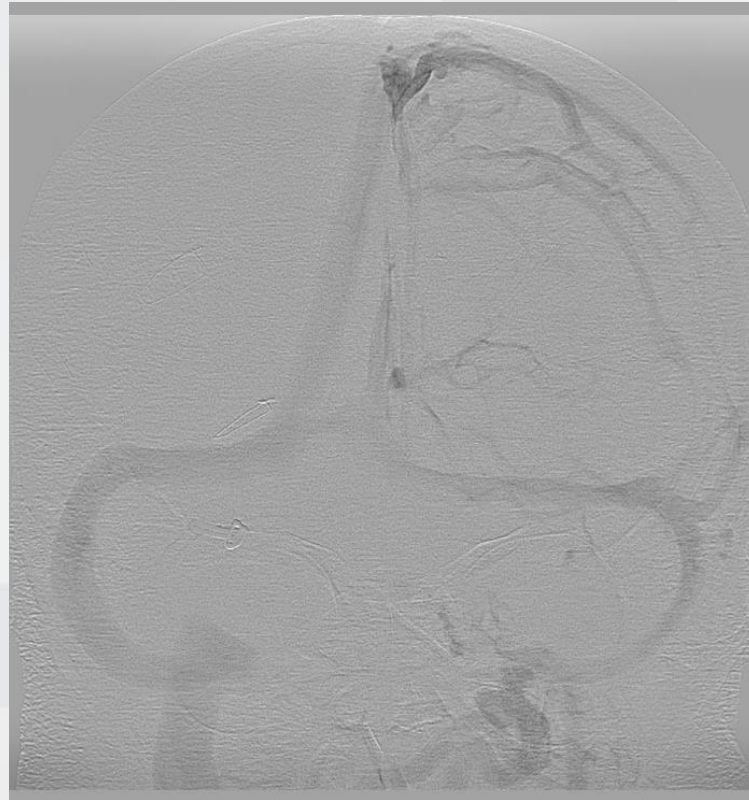


R-ECA

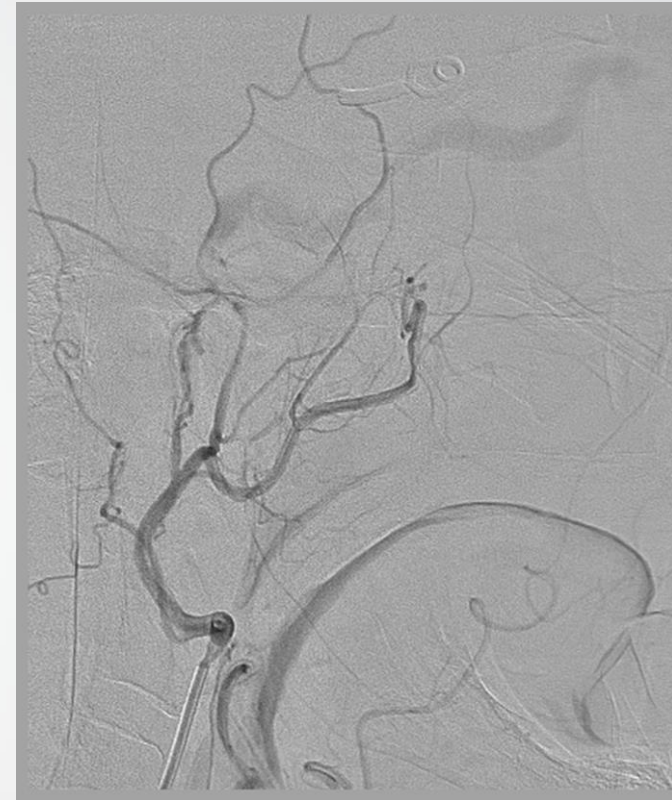PRE TREATMENT



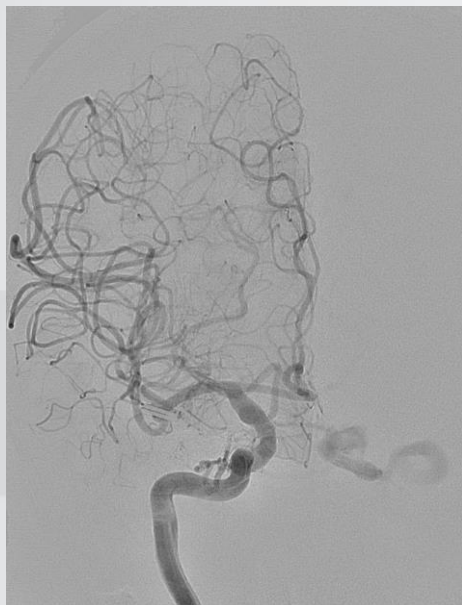L-ICA



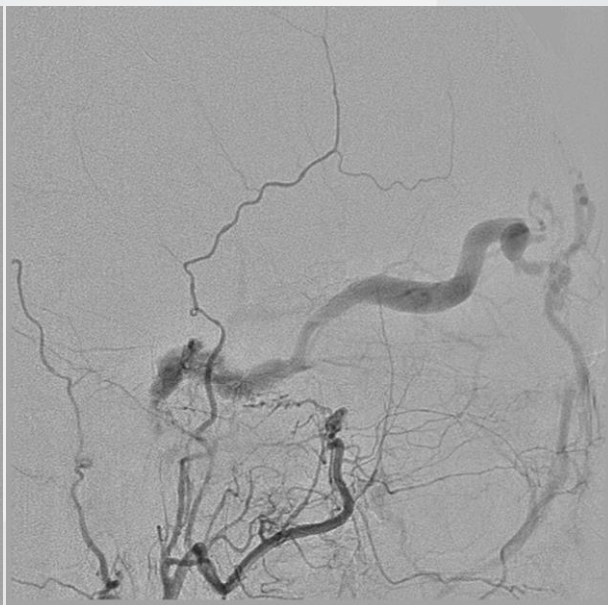
PRE TREATMENT



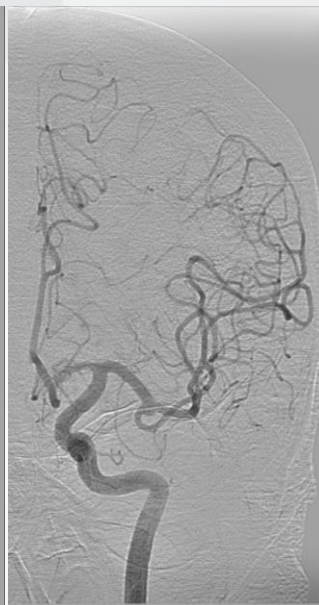L-ECA



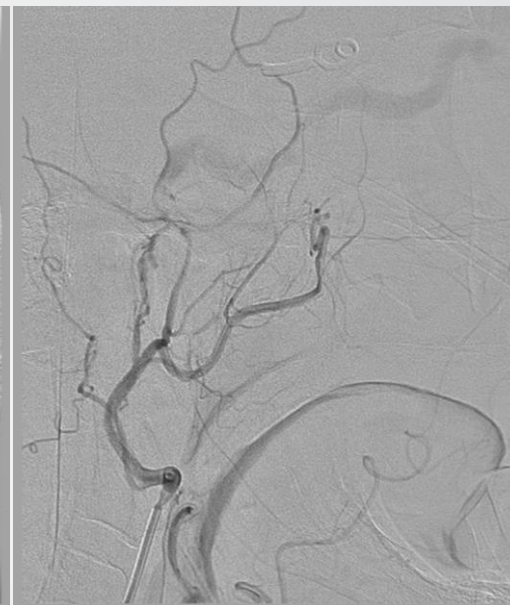R-ICA



R-ECA

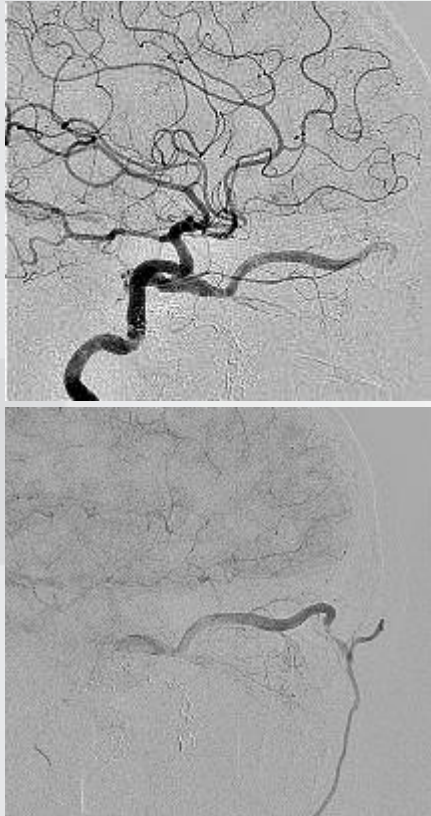

L-ICA

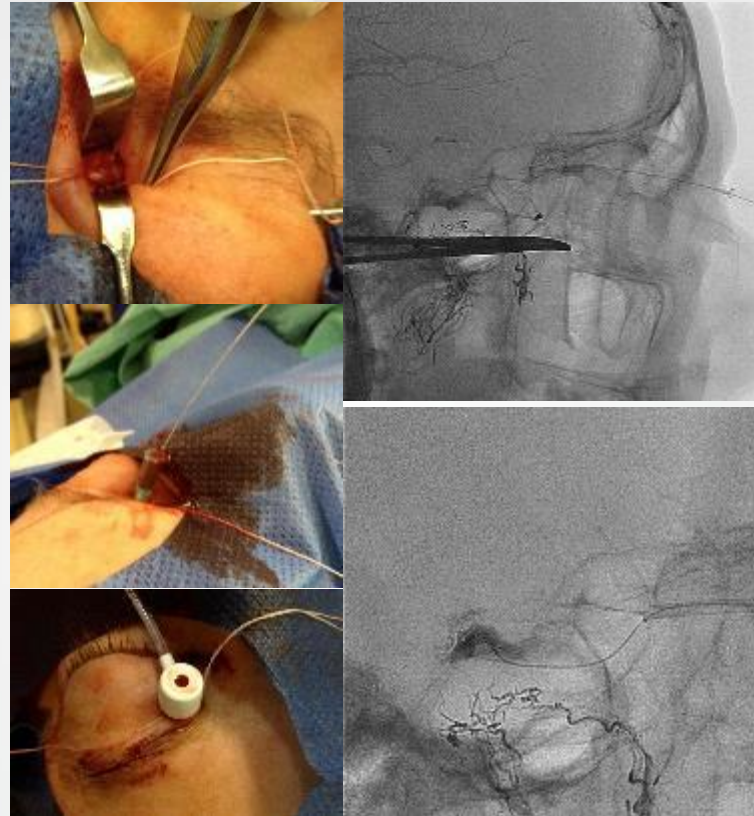


L-ECA

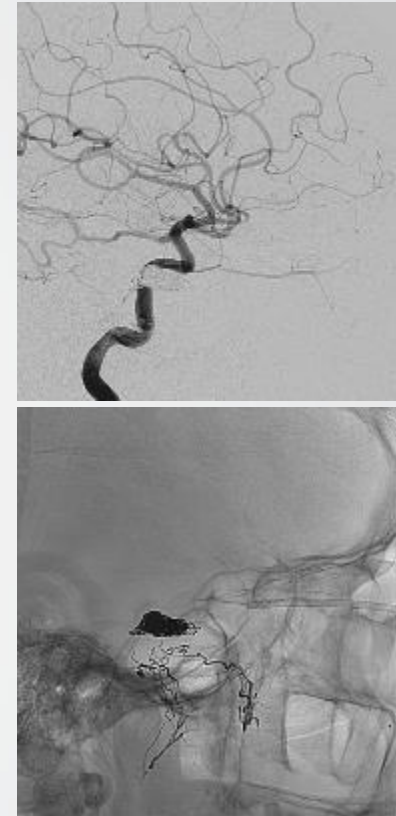
Pre treatment



During treatment



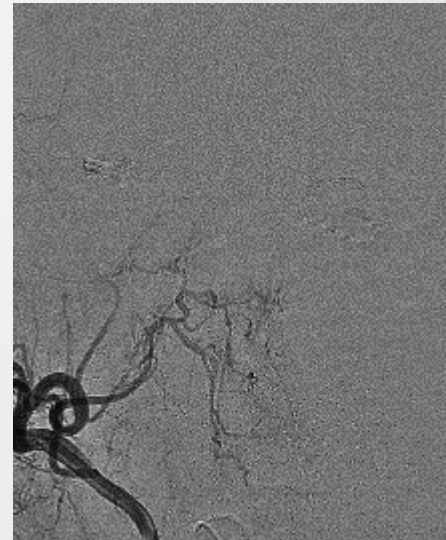
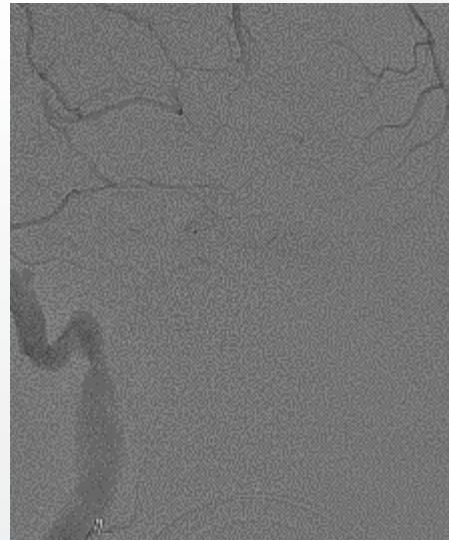
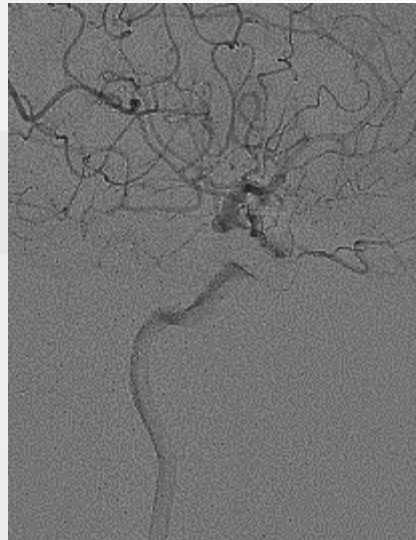
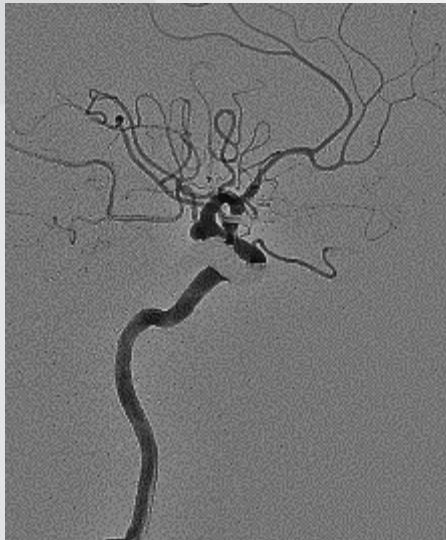
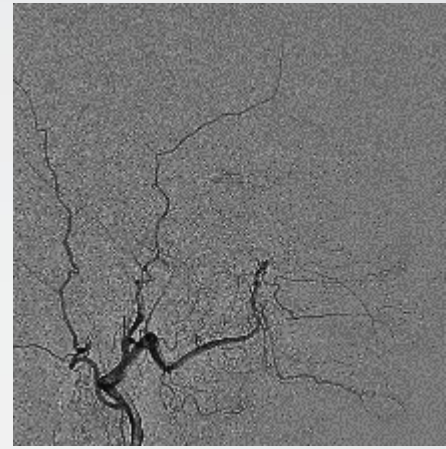
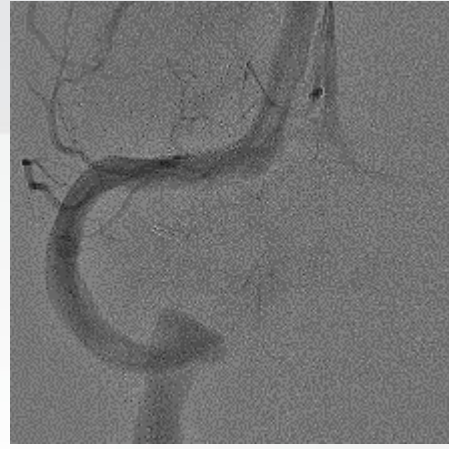
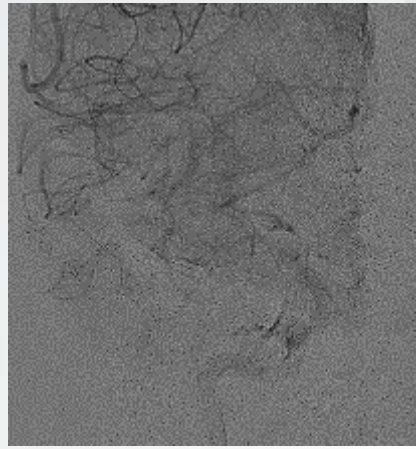
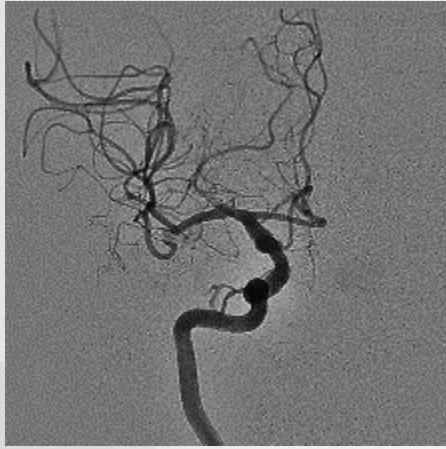Post treatment



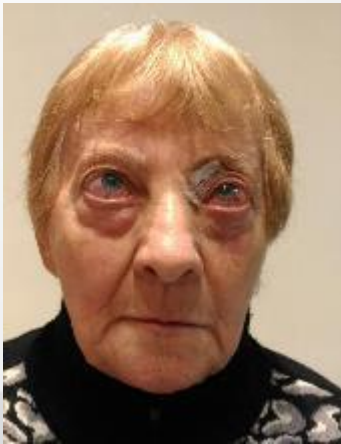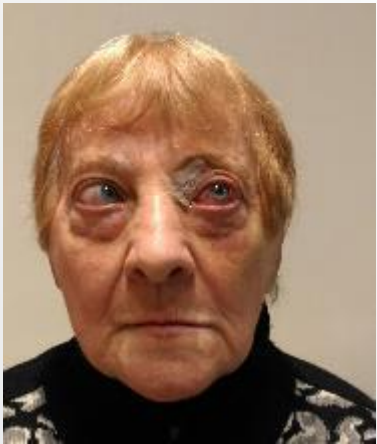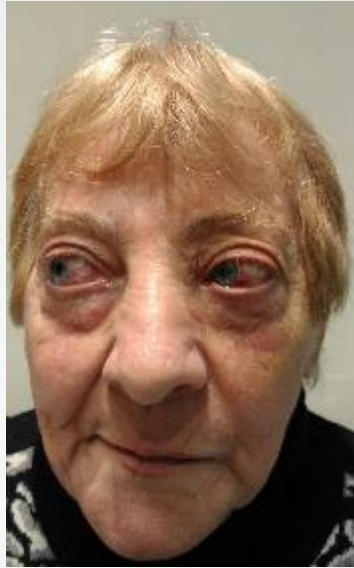
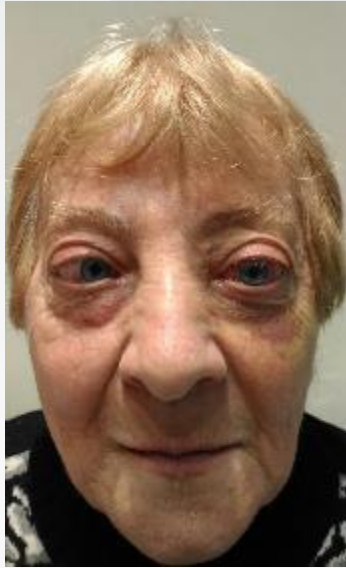
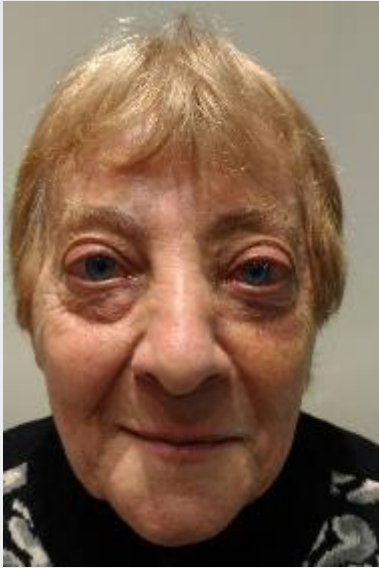INDIRECT CCF - COMBINED TREATMENT

CCF Type D in Barrows classification. 1st treatment with liquid embolic agent (ONYX) through ECA. 2nd treatment with direct puncture of superior ophthalmic vein and coils.

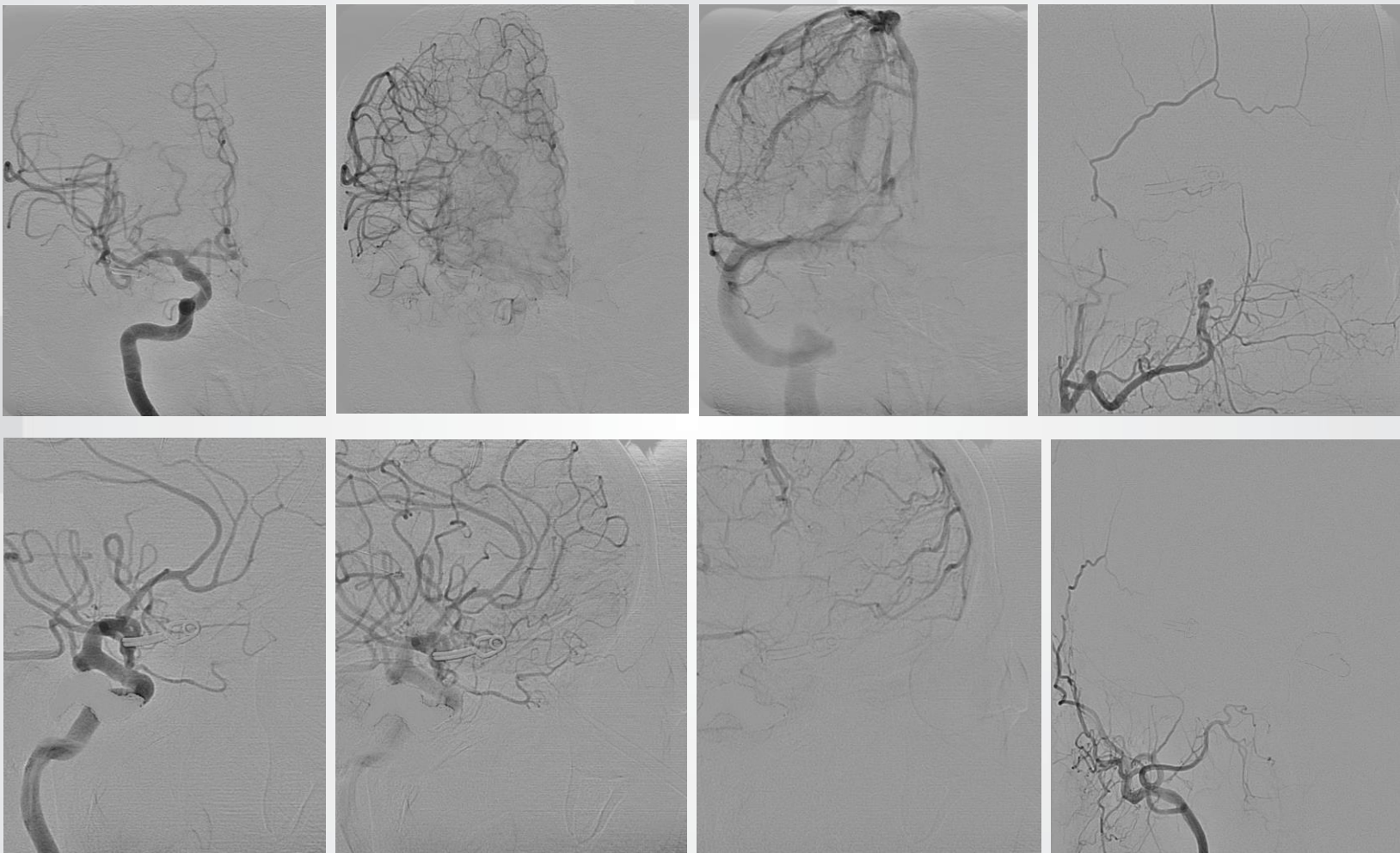
POST TREATMENT



1 WEEK CLINICAL CONTROL



8 Months FUP DSA



PATIENT 3

RM. Fem, 48 y.o.

HBP, SMK, migraine, family history of brain aneurysm.

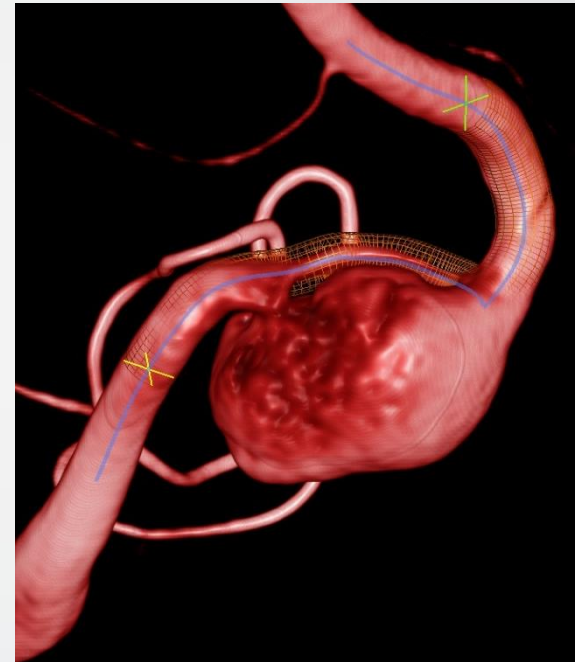
2015: acute cervical pain.

MR / DSA: right V4 dissecting aneurysm

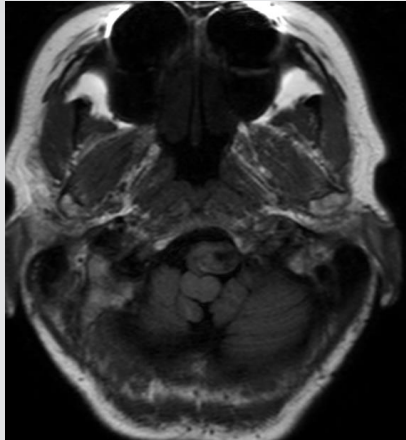
DSA:

Right V4 dissecting aneurysm

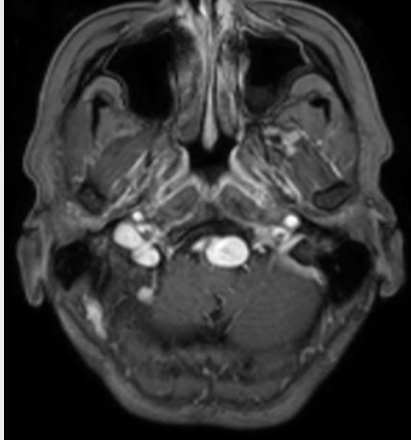
Strategy: Flow diversion



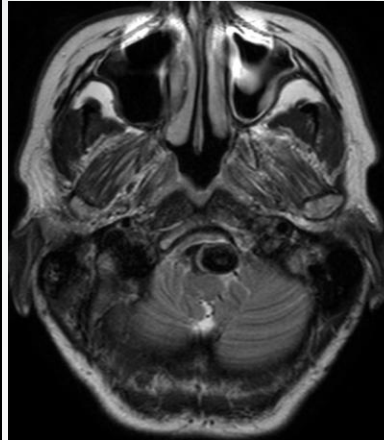
T1



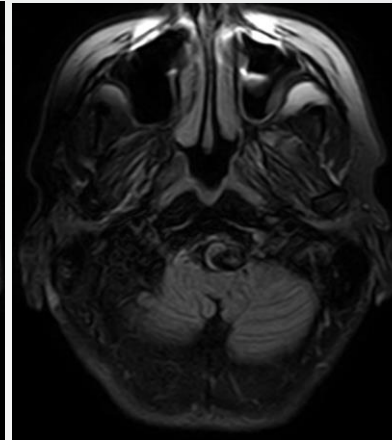
T1 w/gad



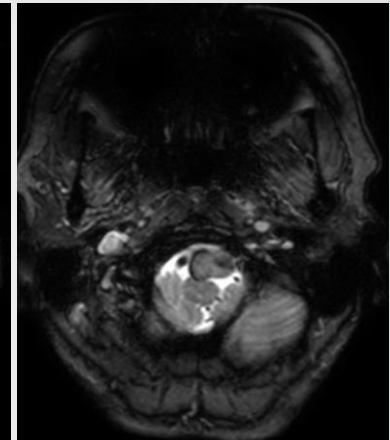
T2



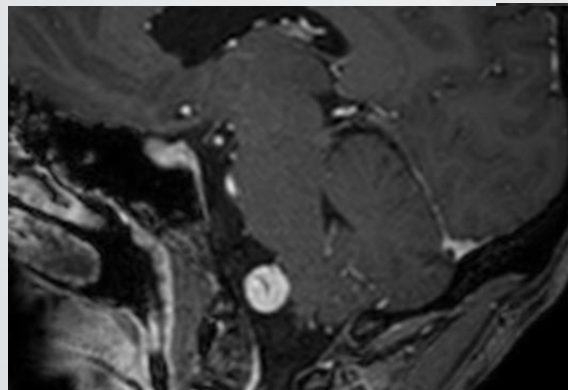
FLAIR



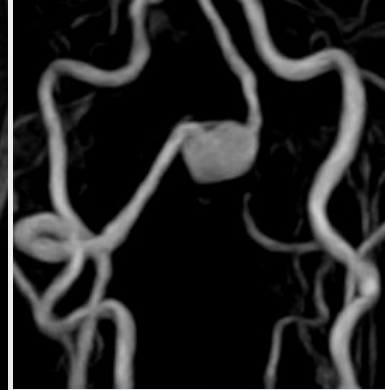
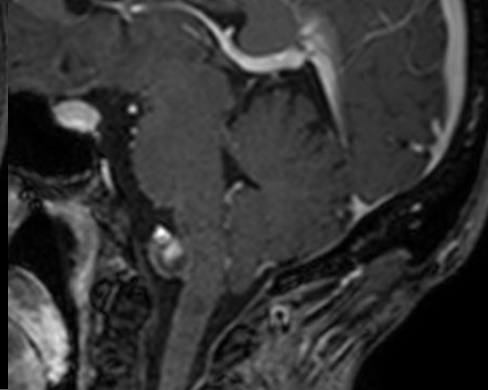
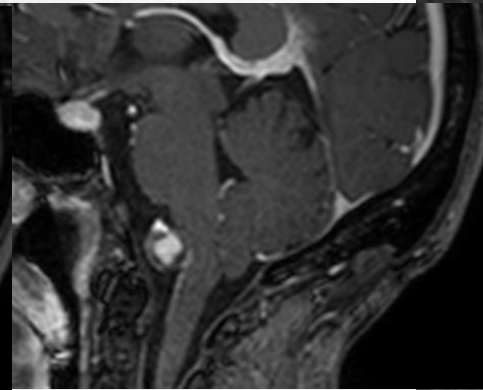
GRE



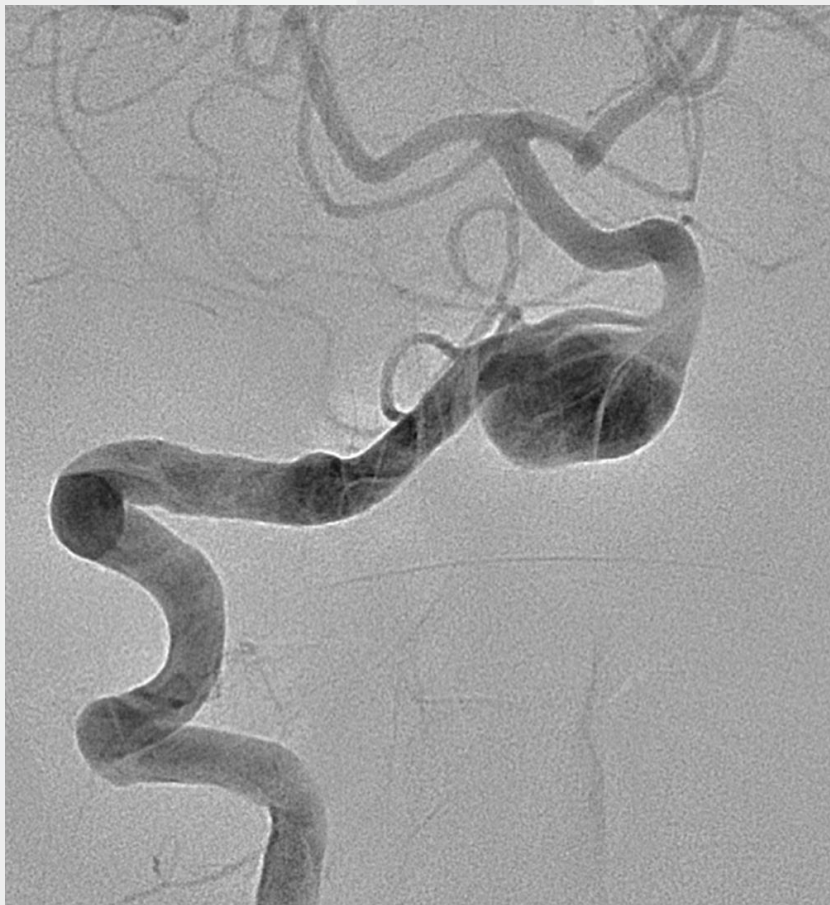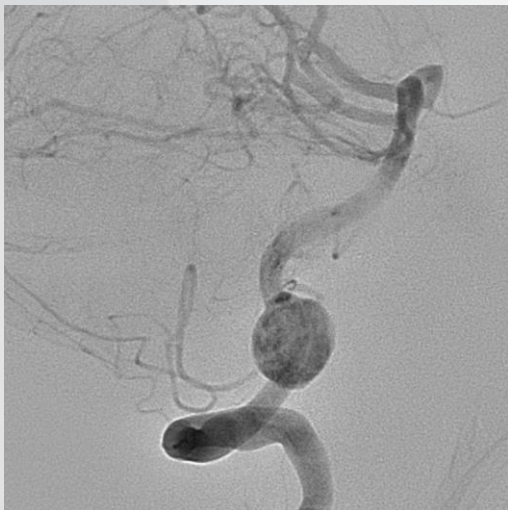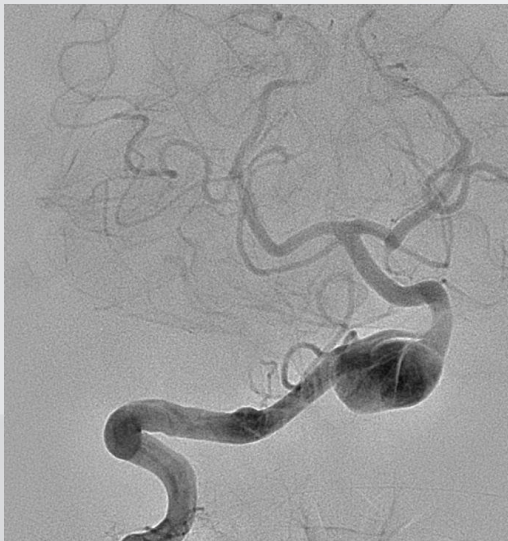T1 w/gad



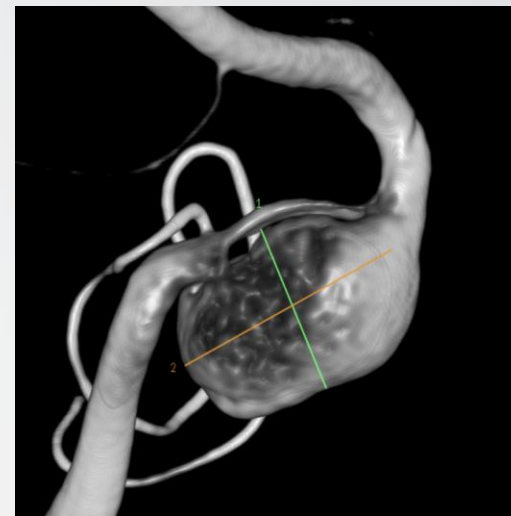
MRA



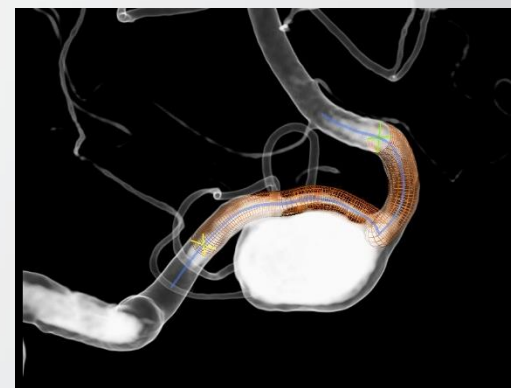PRE TREATMENT



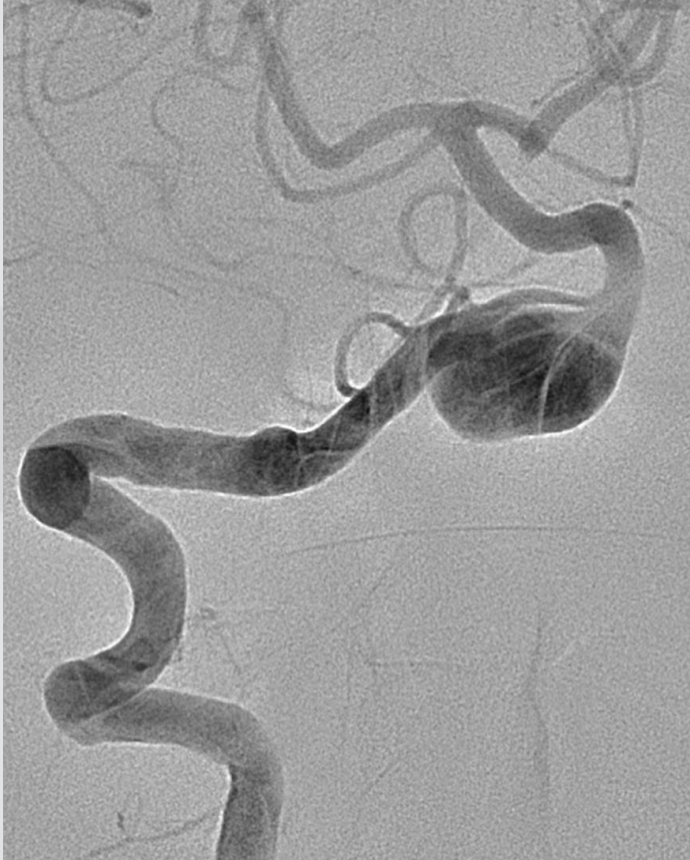PRE TREATMENT



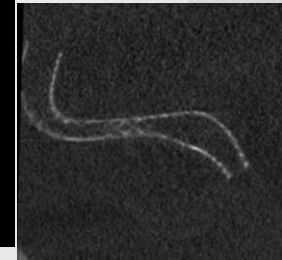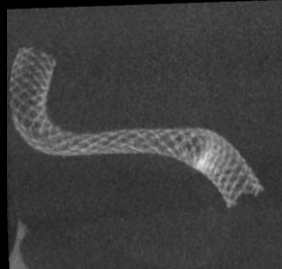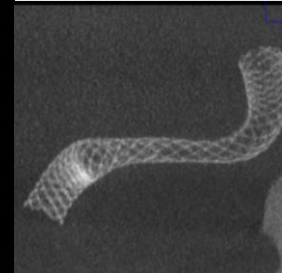
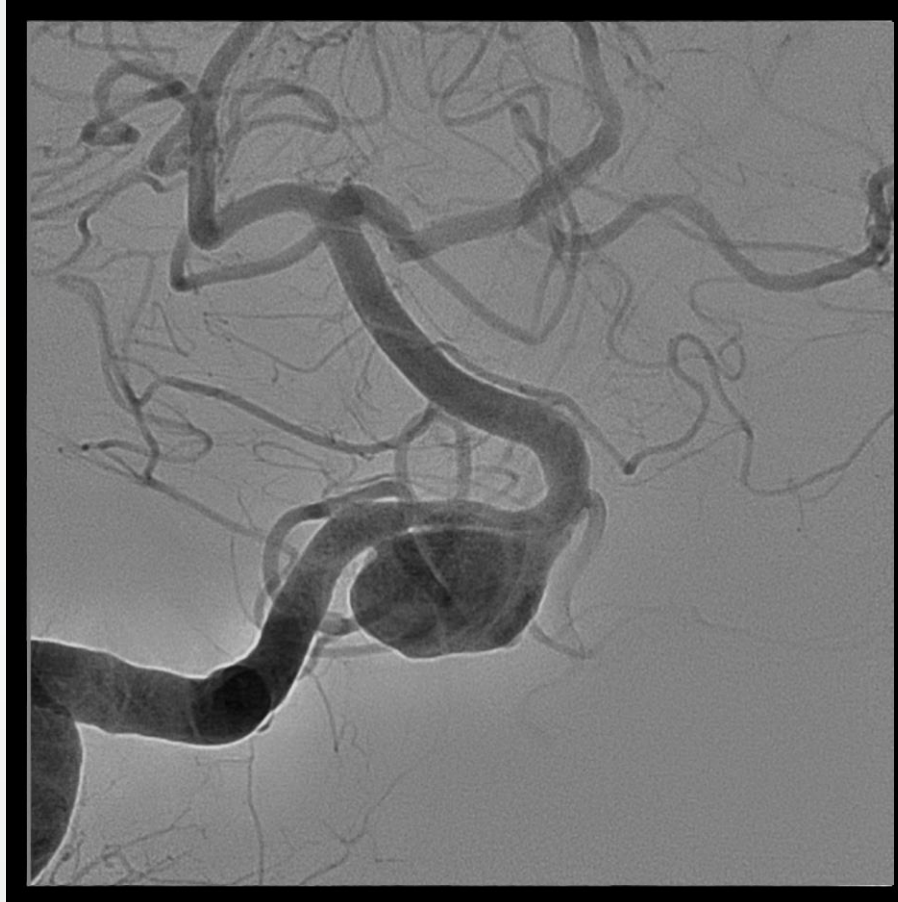Medición rápida 1 11.47 mm
Medición rápida 2 15.82 mm

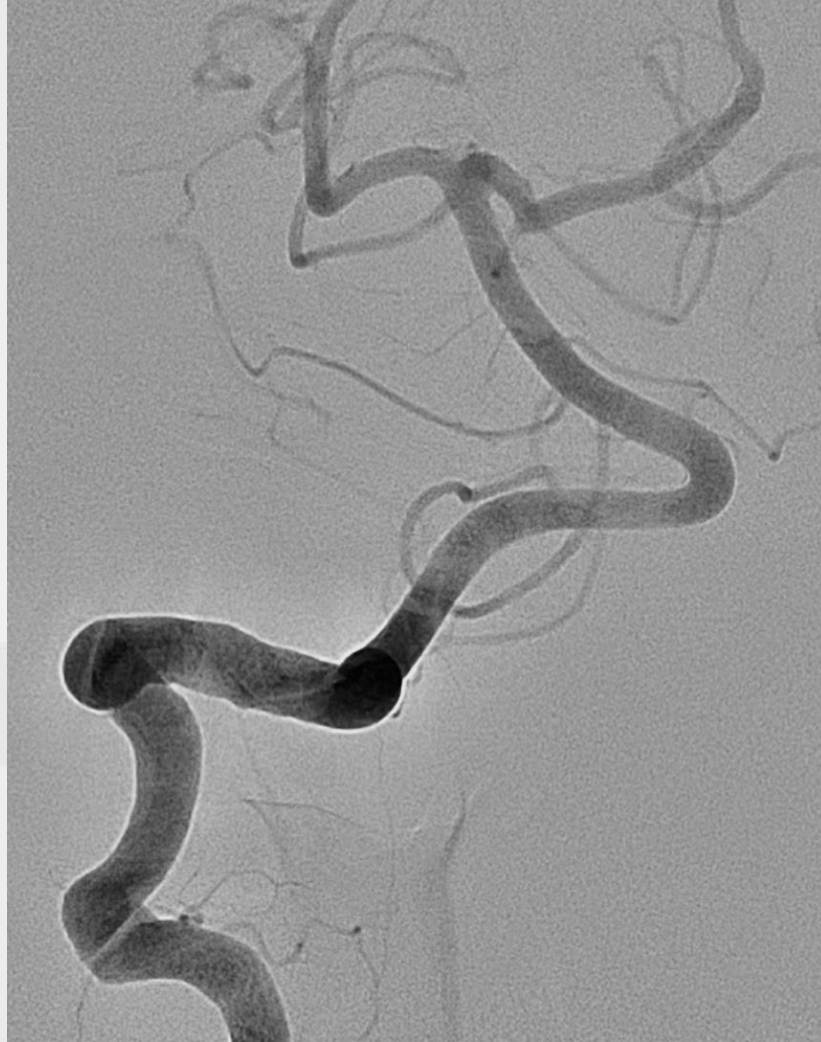
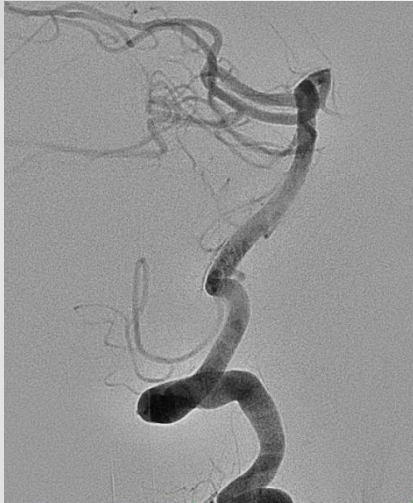
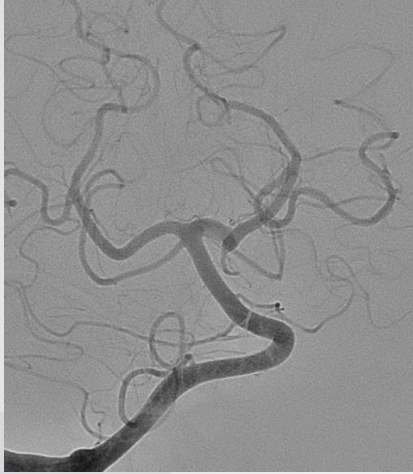PRE TREATMENT

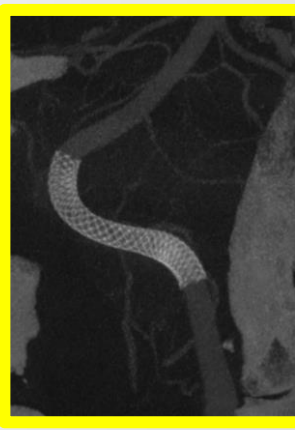
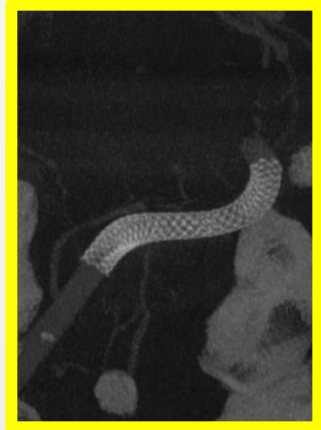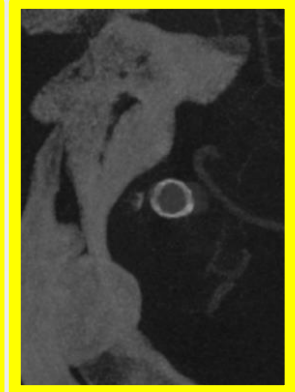
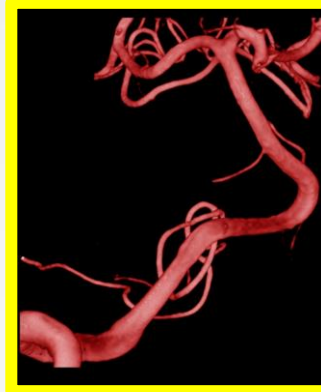


POST TREATMENT





6 Months FUP DSA



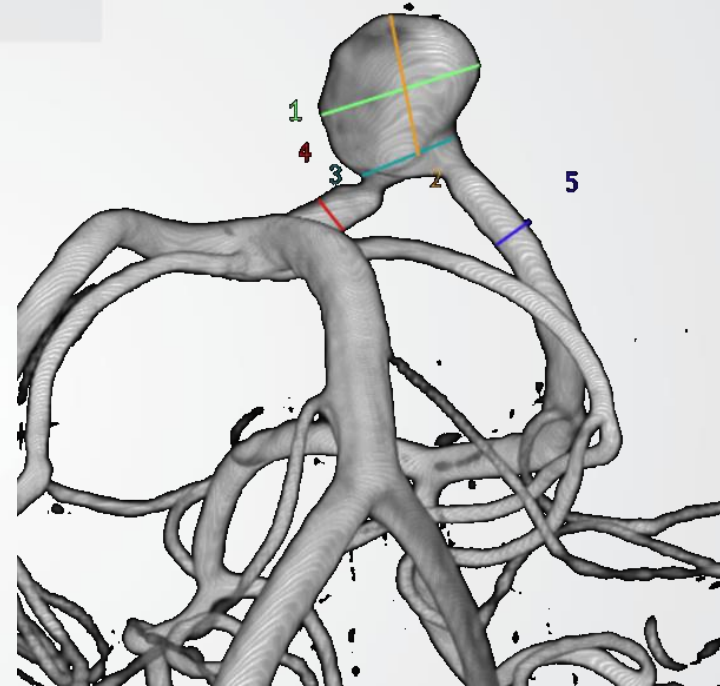
PATIENT 4

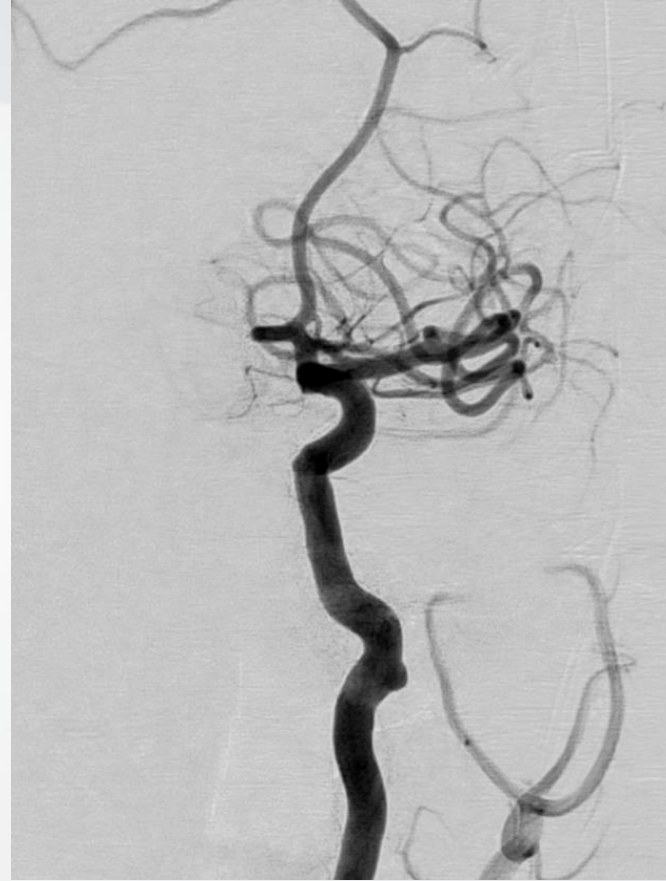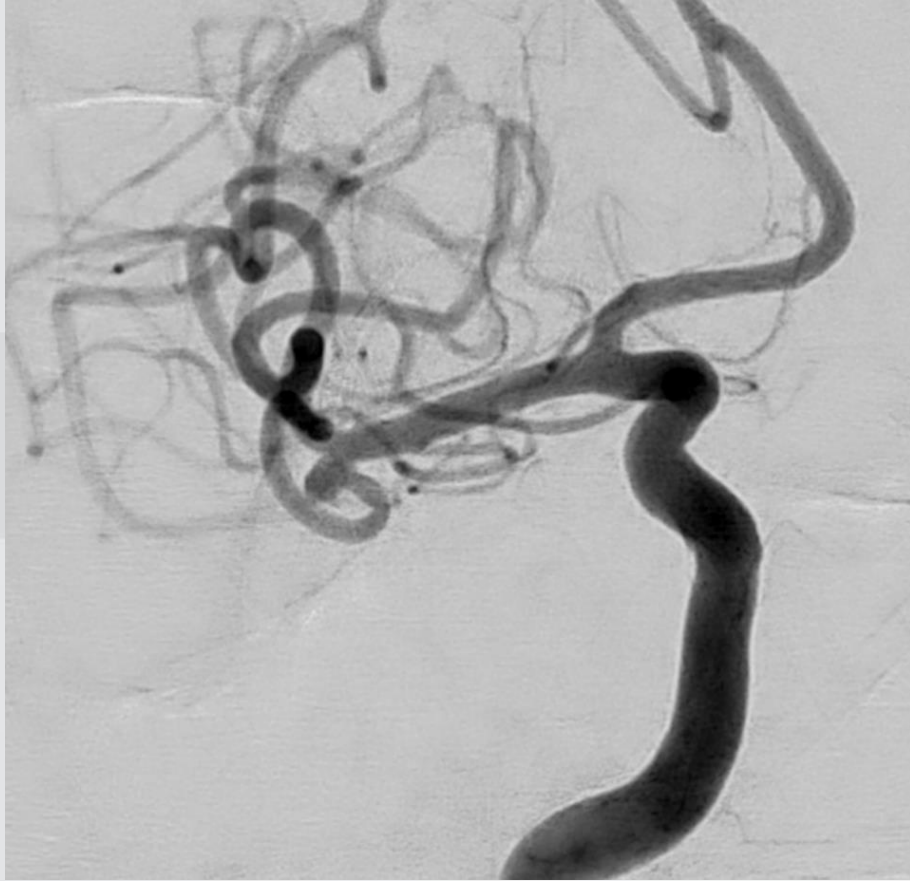FS. Fem, 69 y.o.
HBP, SMK.

Thunderclap headache 1 month ago.
CT: no SAH.

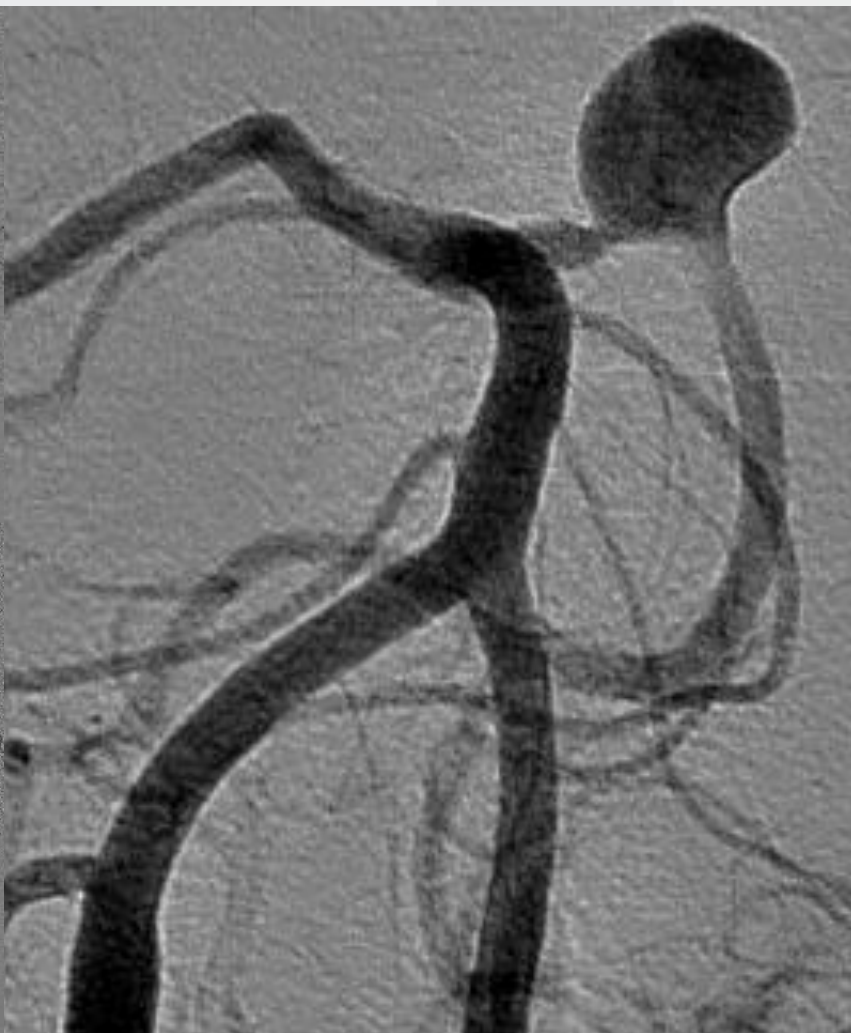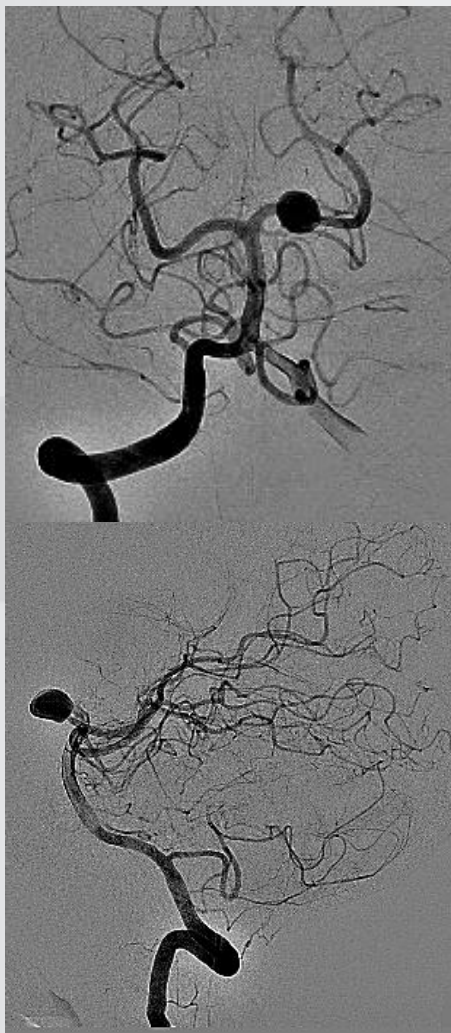DSA:
Left P1 dissecting aneurysm

Strategy: Flow diversion

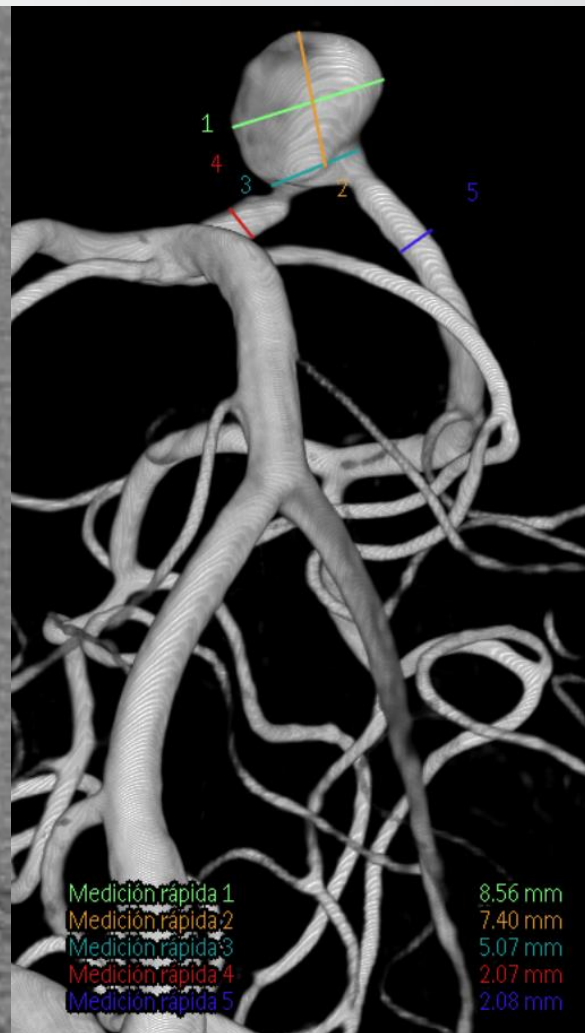



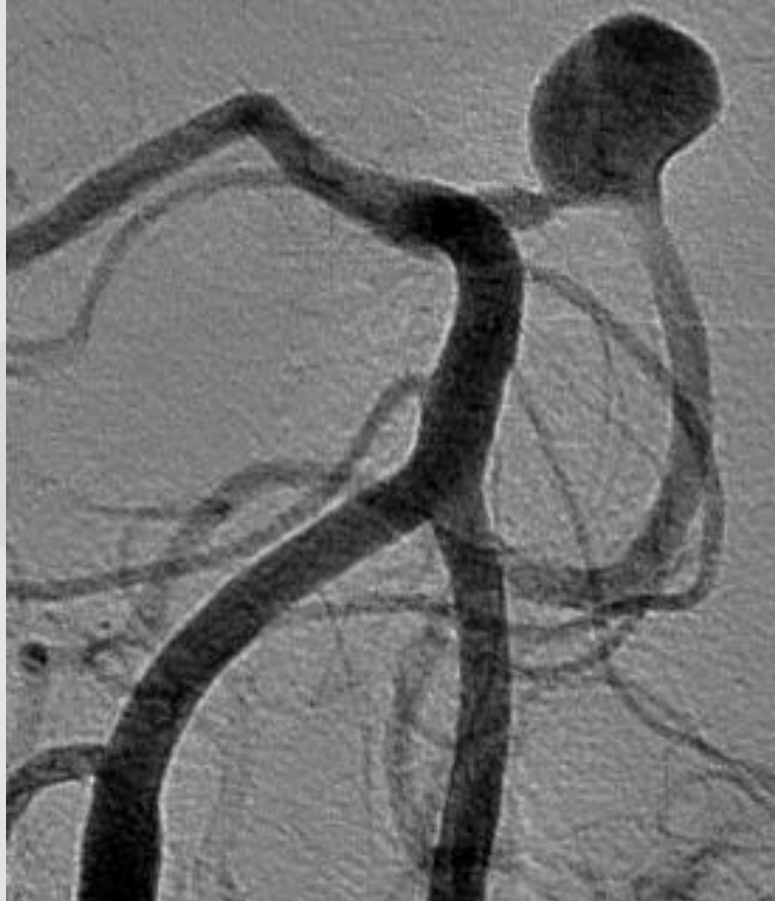PRE TREATMENT



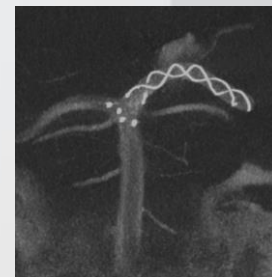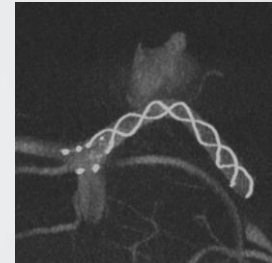
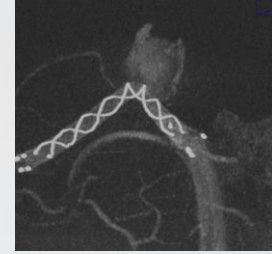
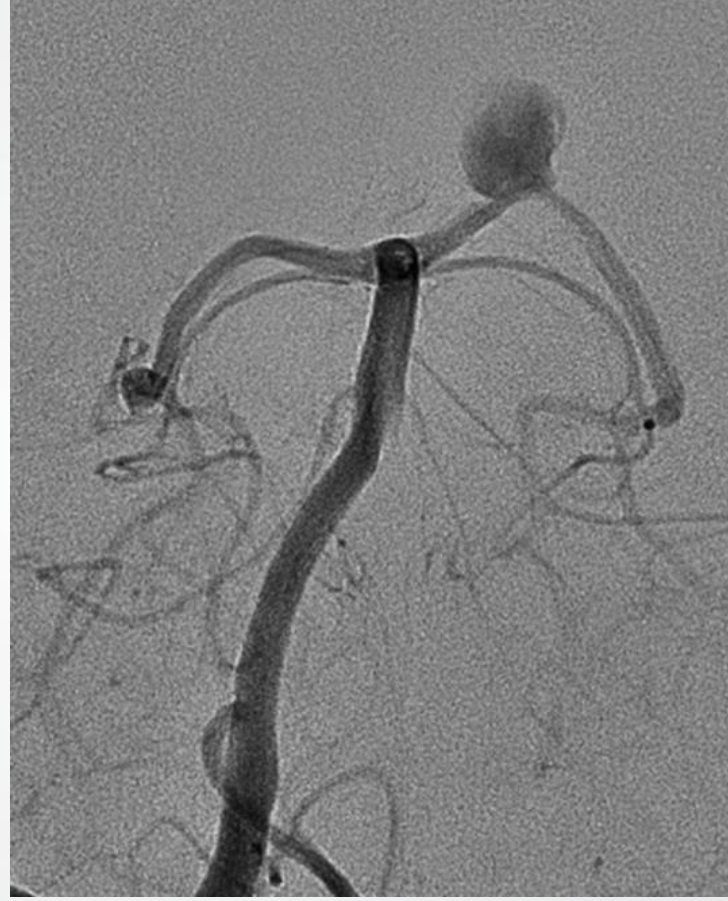PRE TREATMENT

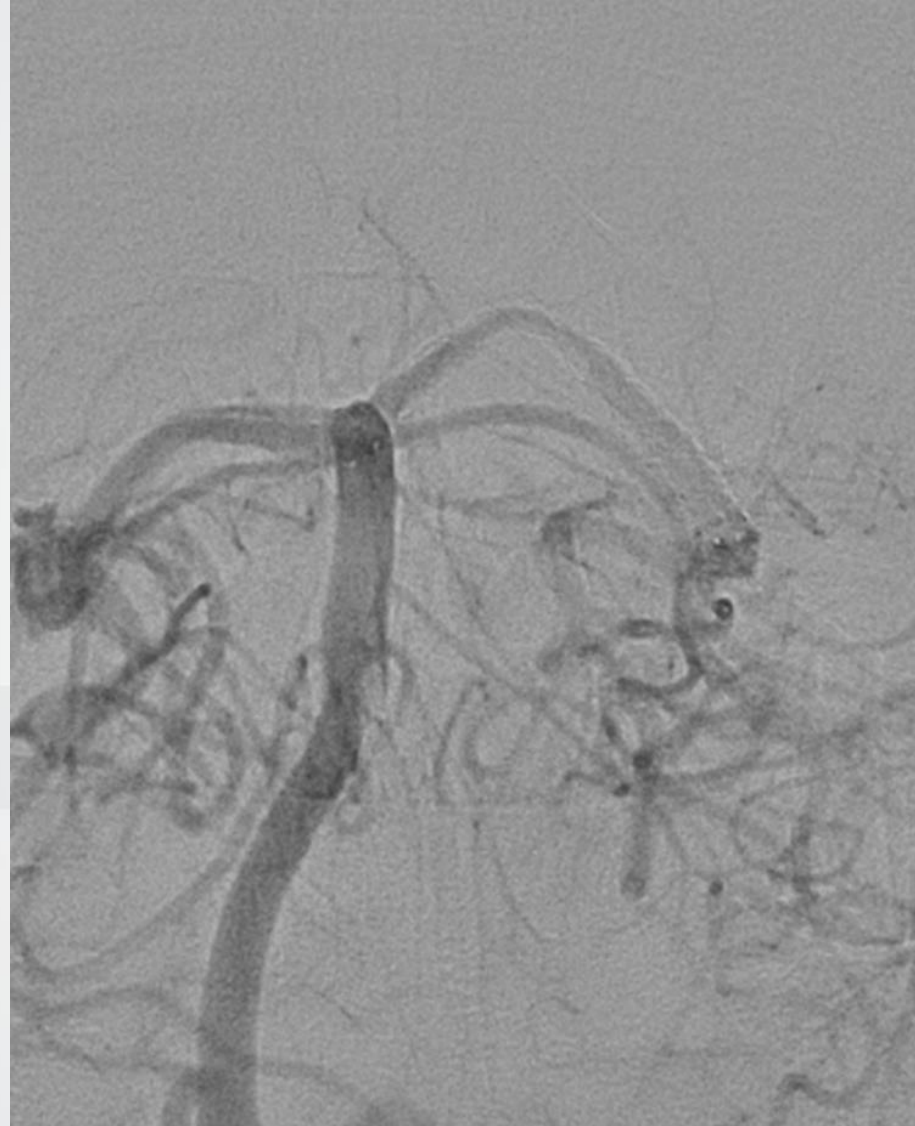
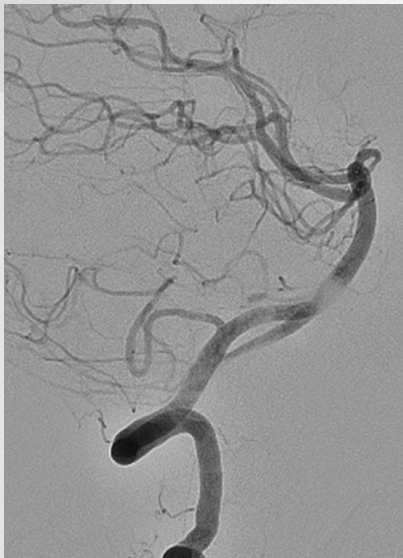
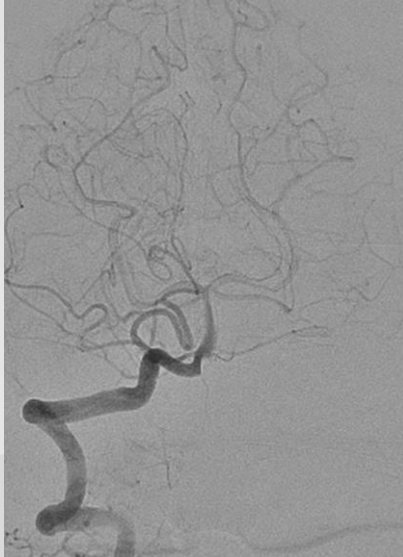PRE TREATMENT

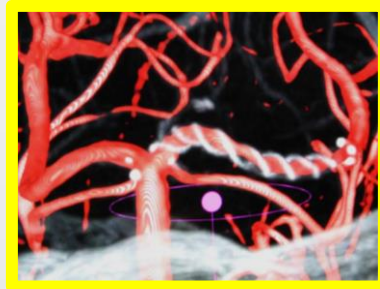
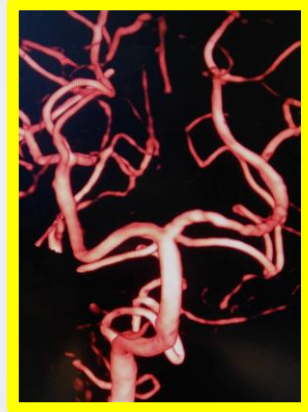
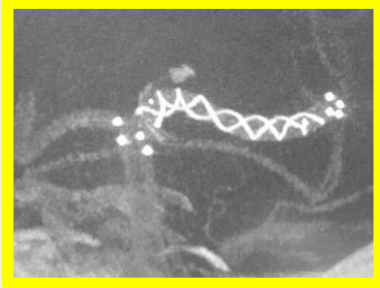


POST TREATMENT





6 Months FUP DSA



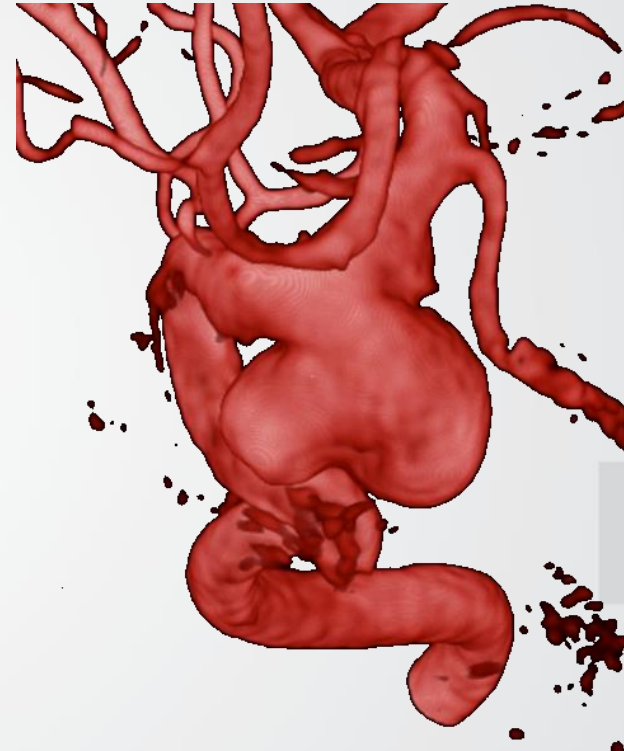PATIENT 5

**CK. Fem, 47 y.o.
HBP.**

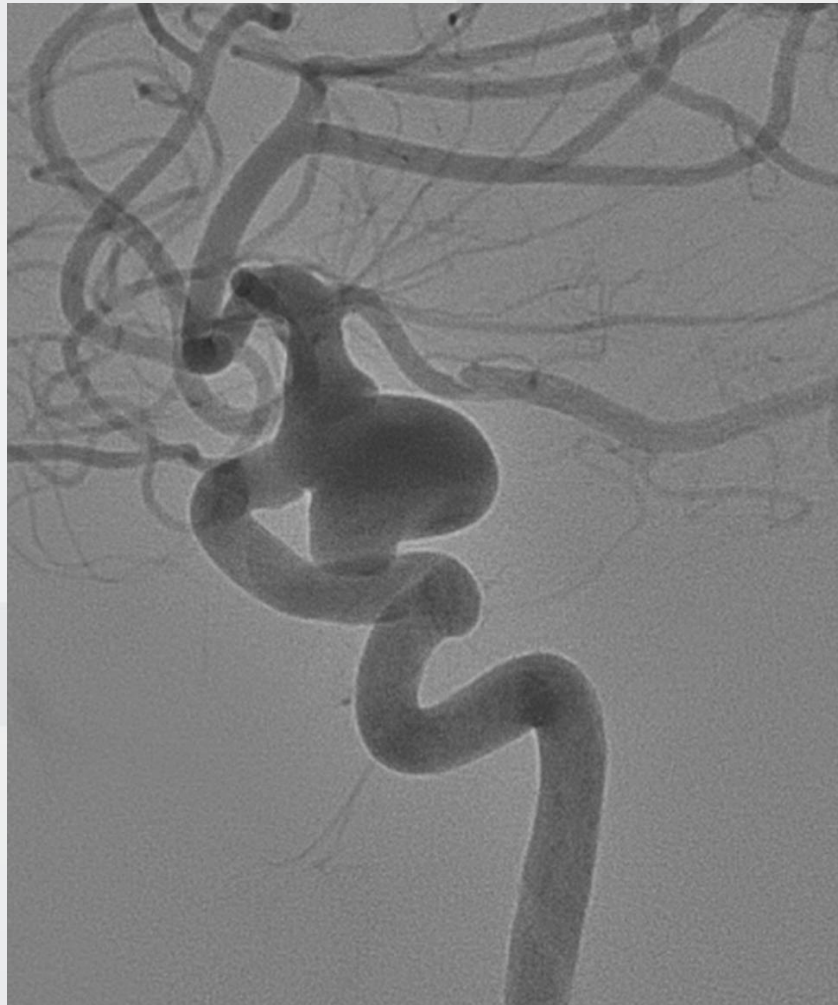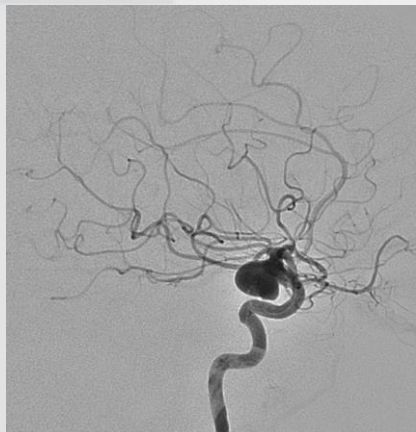
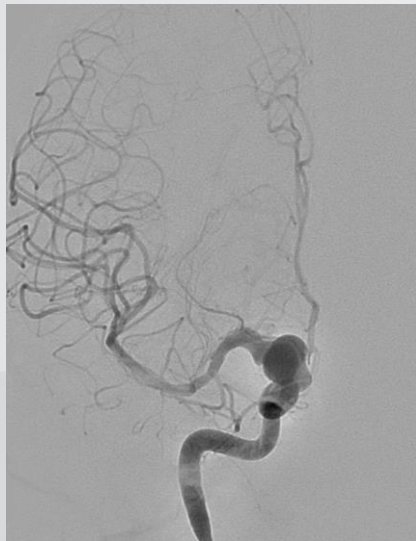Right large paraophthalmic aneurysm

**DSA:
Right large PARAOPHTHALMIC bilobulated aneurysm**

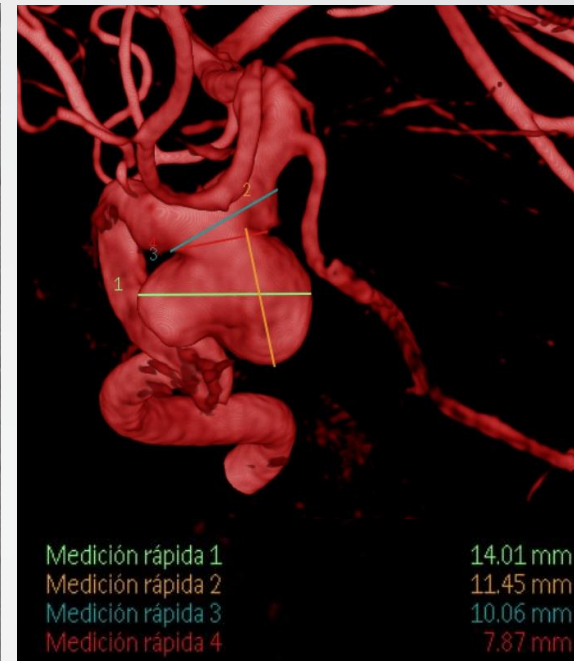
Strategy: Flow Diversion



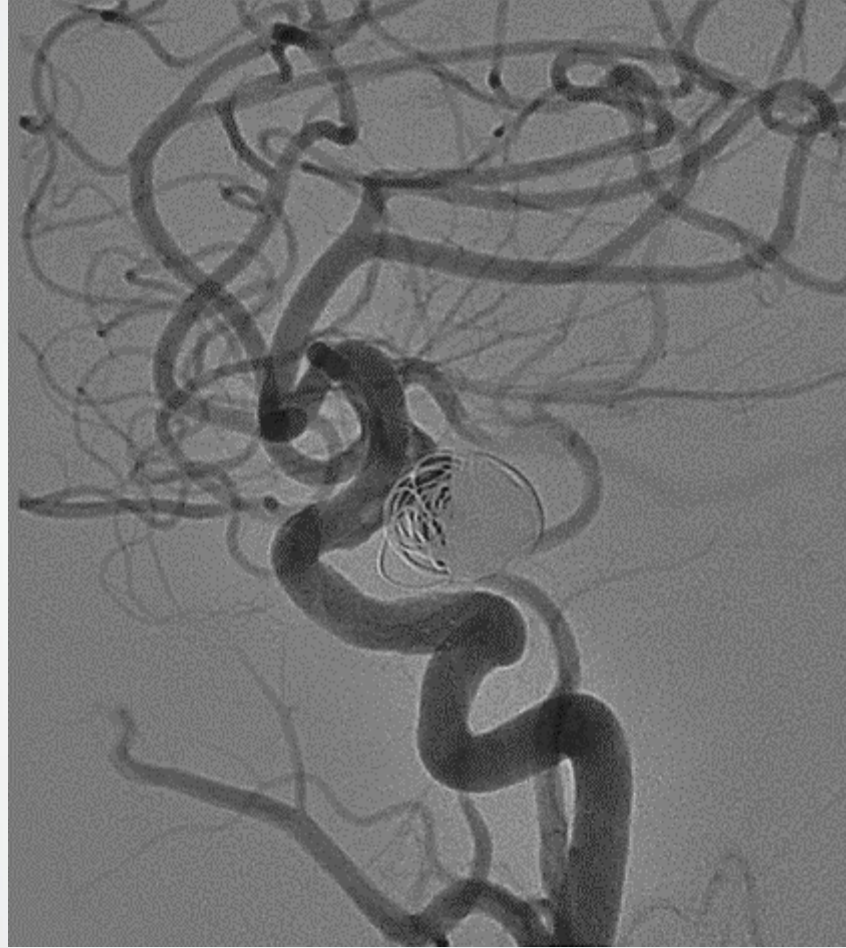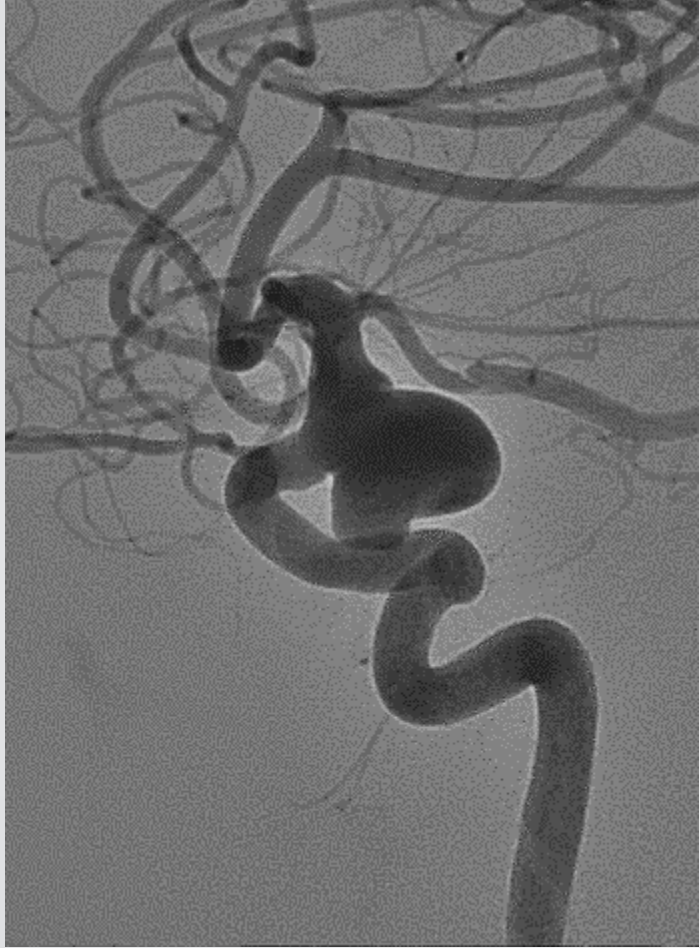PRE TREATMENT



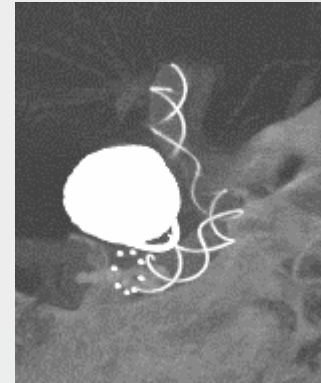
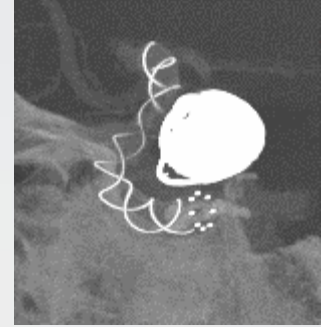PRE TREATMENT



PRE TREATMENT

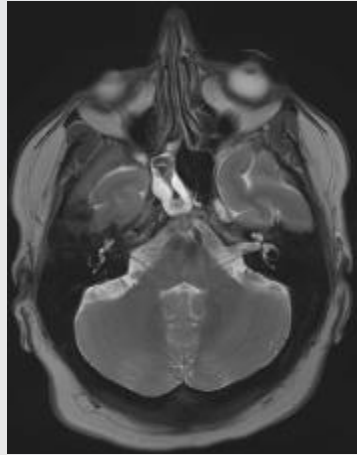


POST TREATMENT

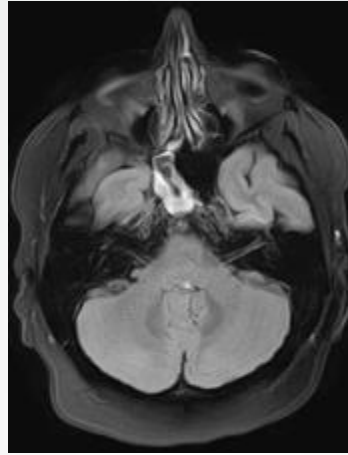


6 Months FUP MRI/MRA

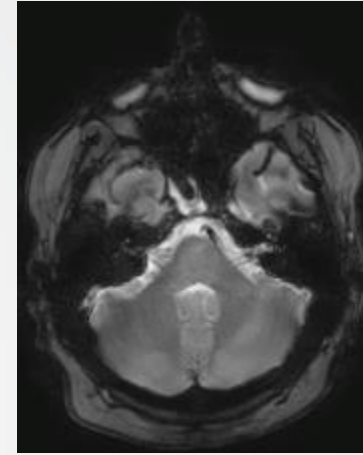
T2



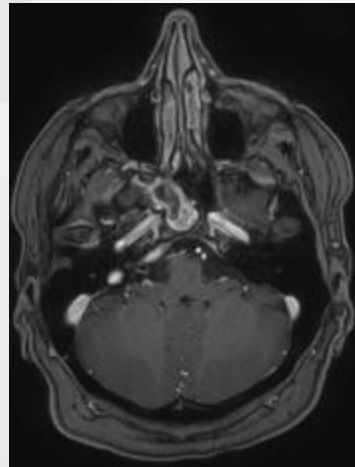
FLAIR



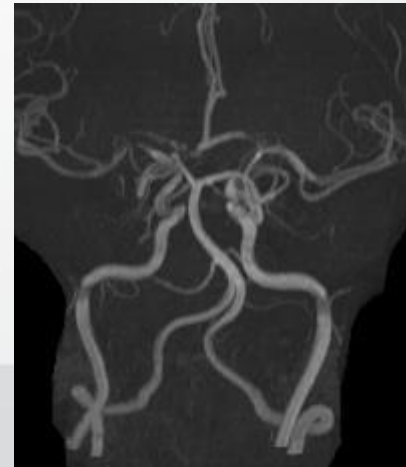T2W FFE



T1 w/gad



MRA



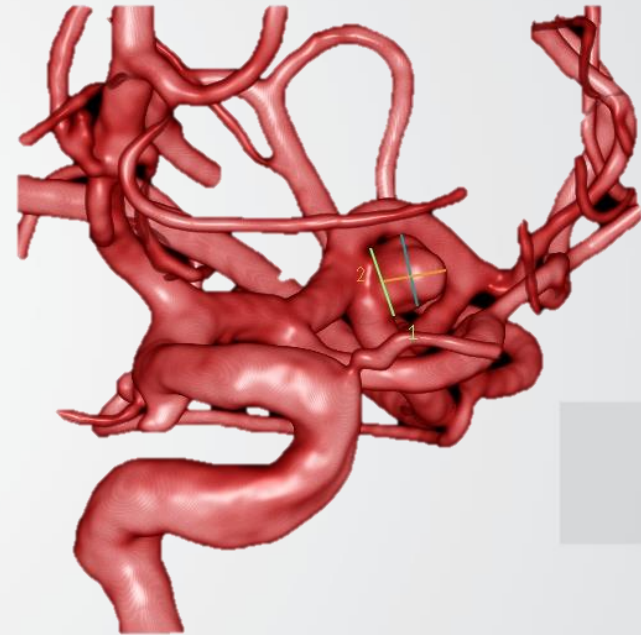PATIENT 6

CA. Fem, 59 y.o.
HBP, headache, seizures

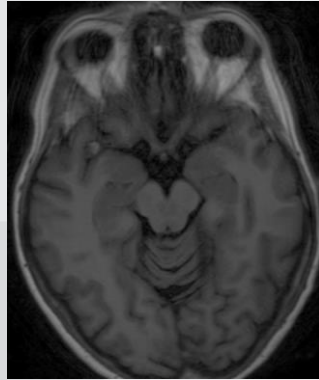
R-MCA bifurcation aneurysm treated with stent & coils

DSA:
Left MCA bifurcation aneurysm

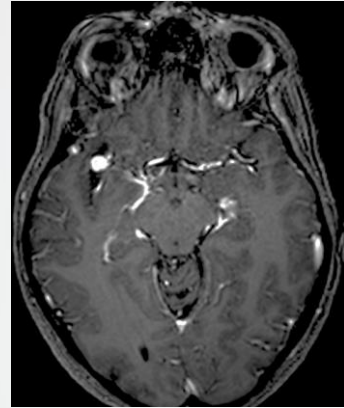
Strategy: Flow Diversion



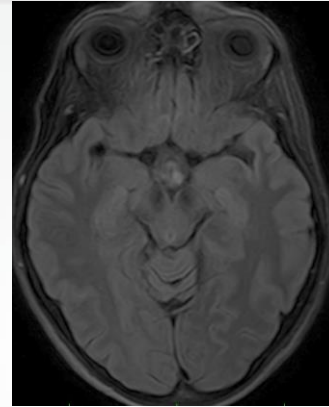
T1



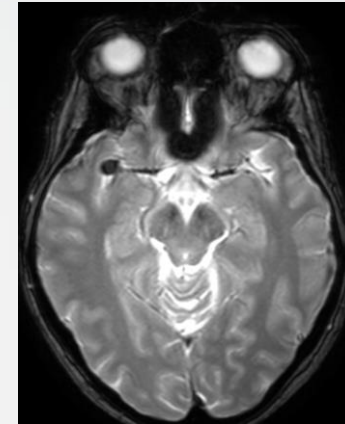
T1 W/GAD



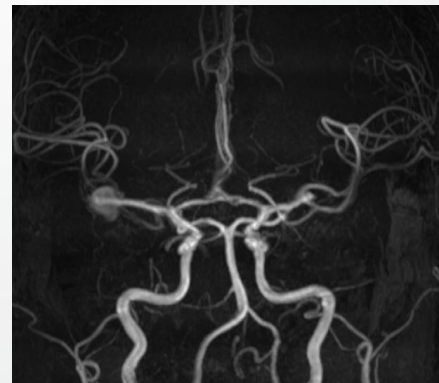
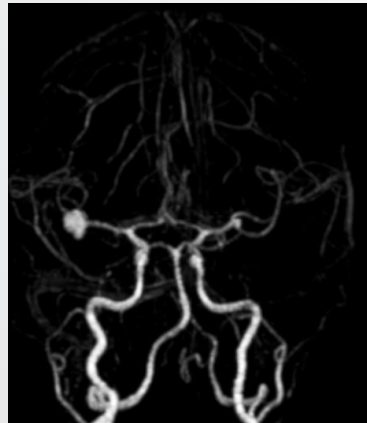FLAIR



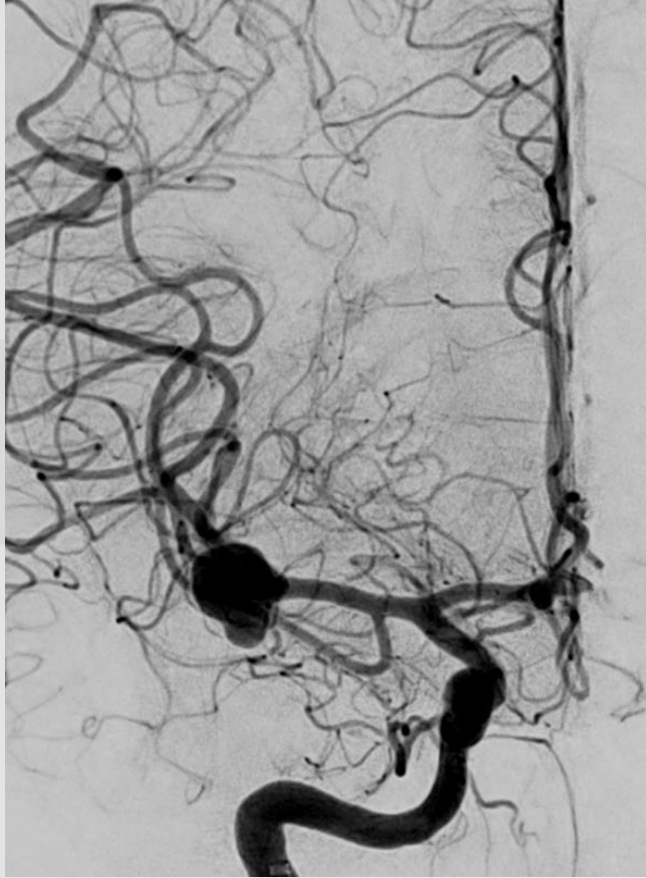
GRE



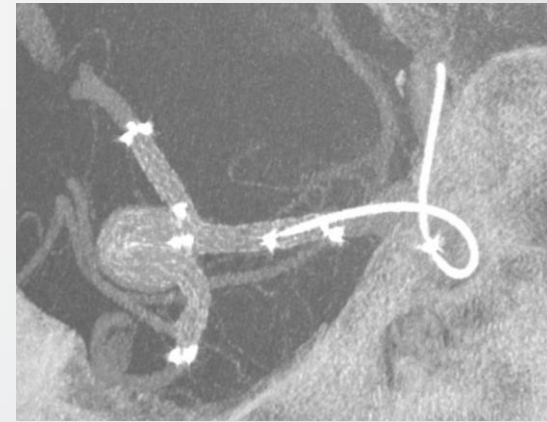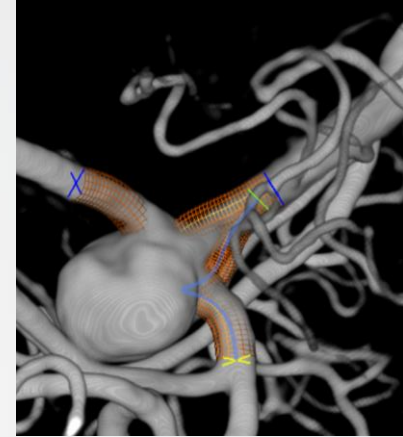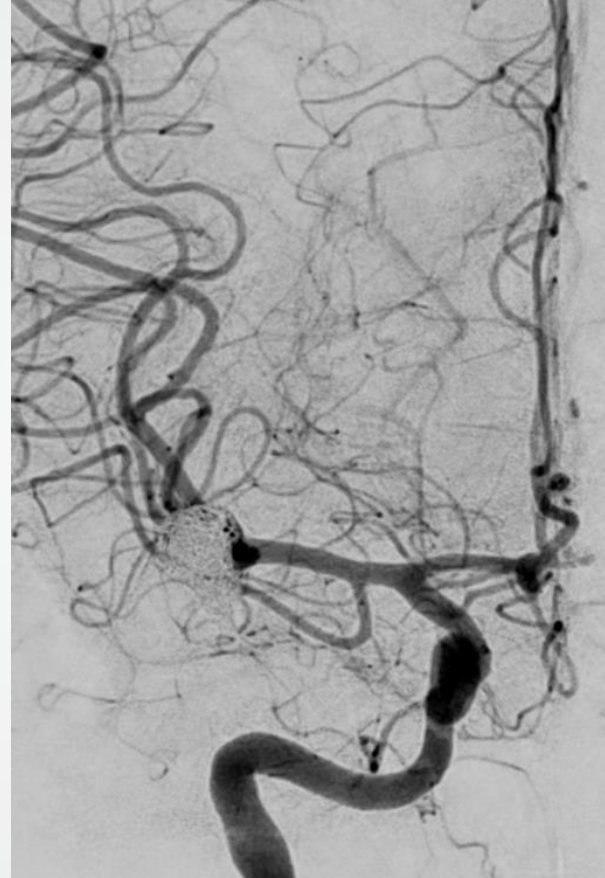
MRA



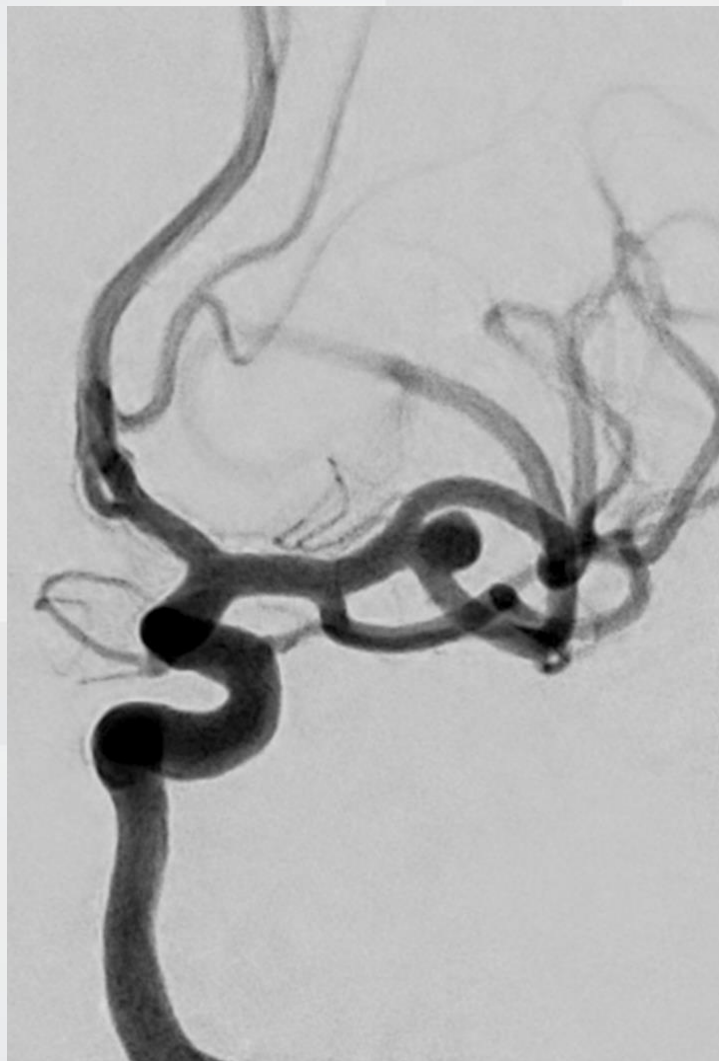
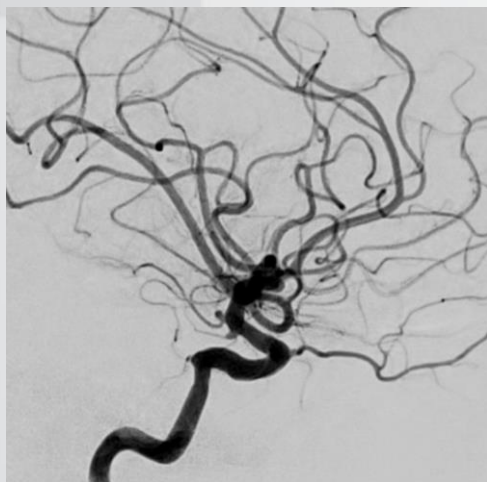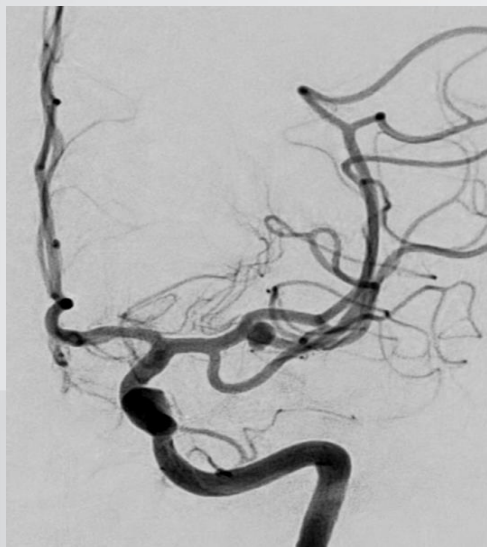PRE TREATMENT



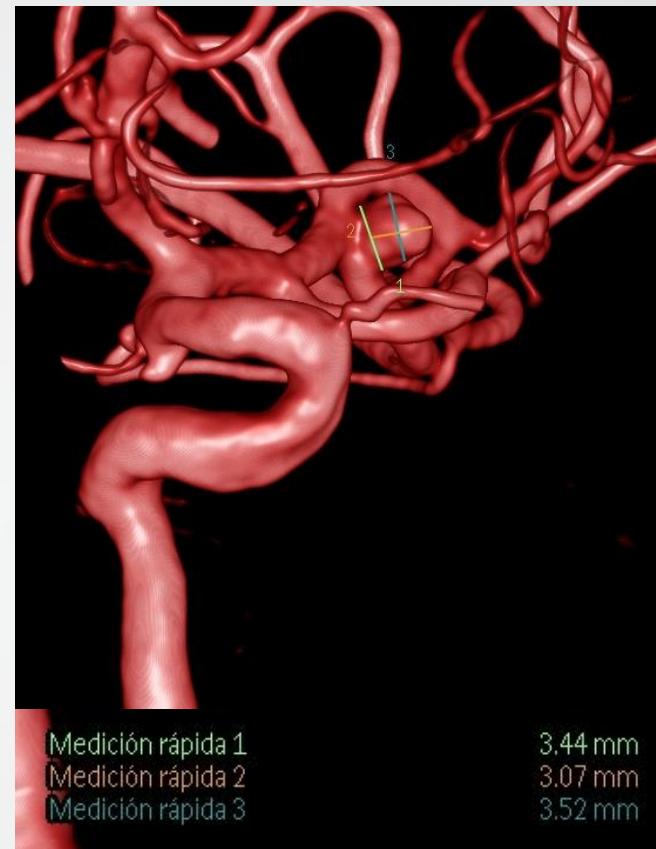POST TREATMENT



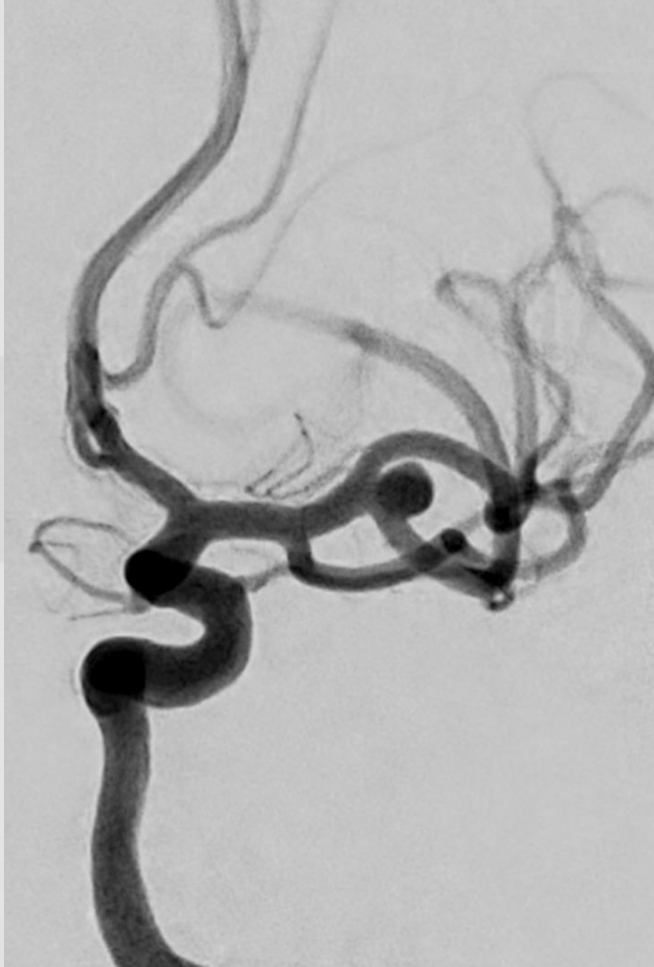
PRE TREATMENT



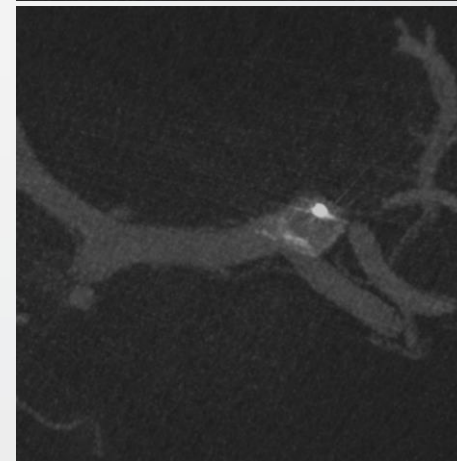
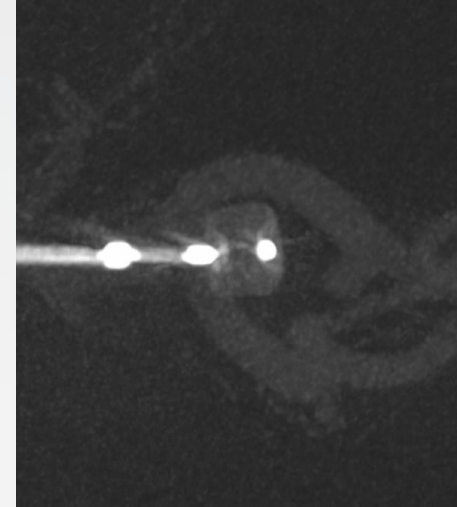
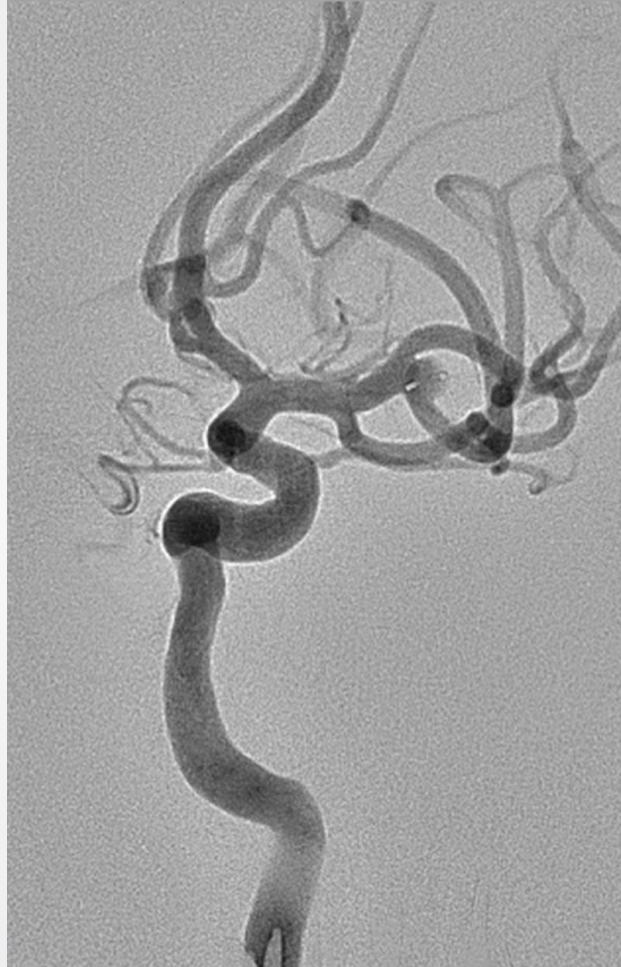
PRE TREATMENT

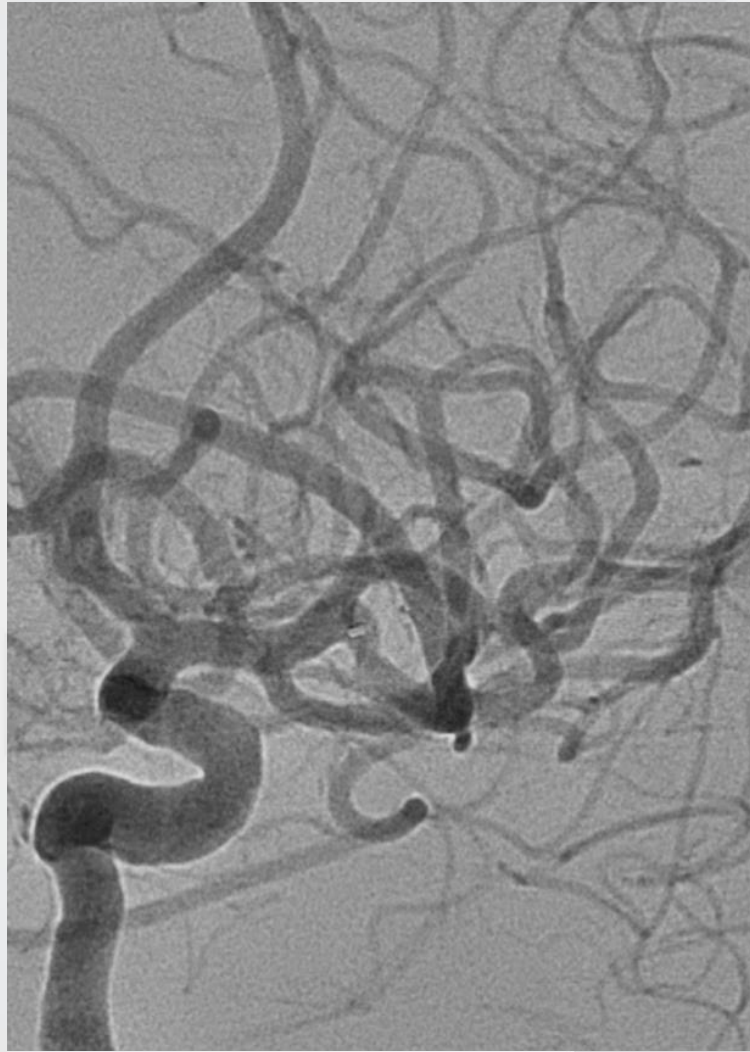
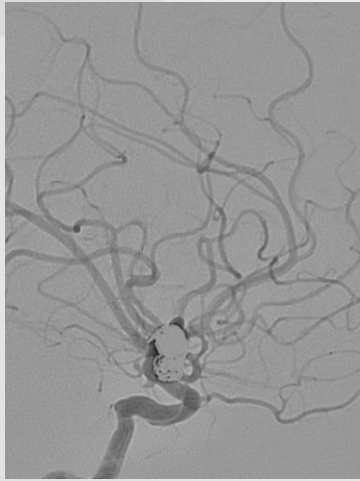
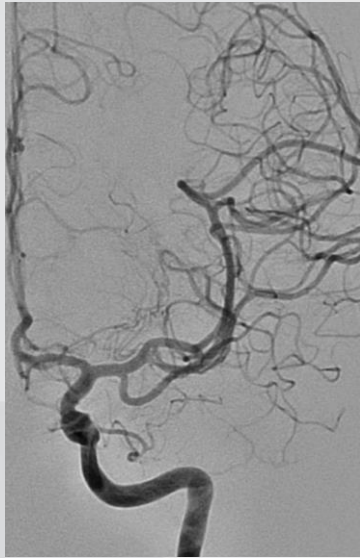


PRE TREATMENT

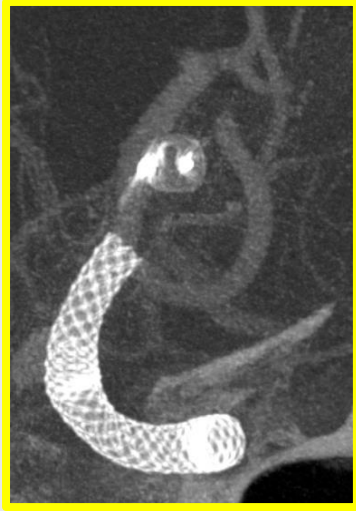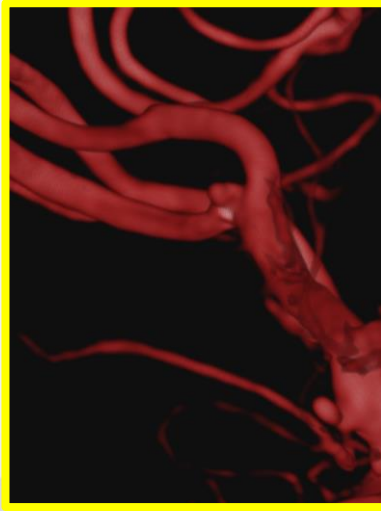
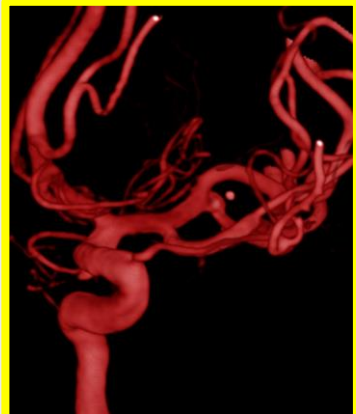

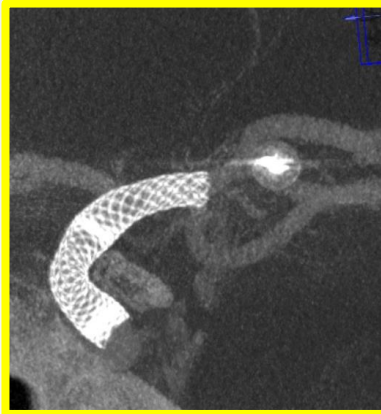
POST TREATMENT

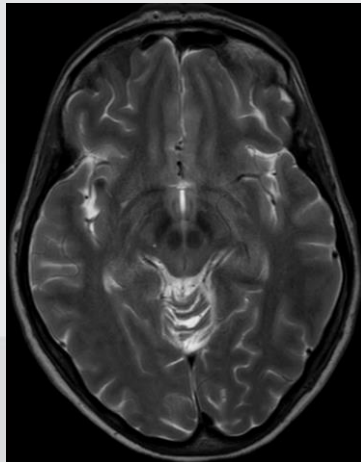




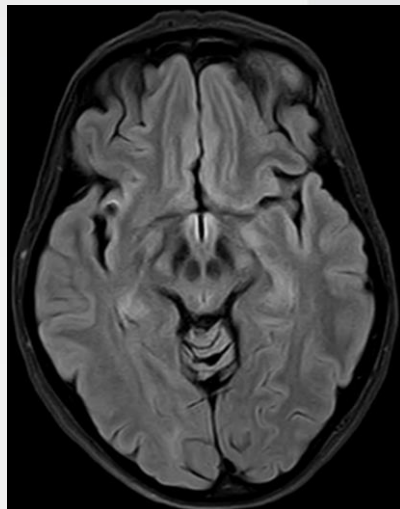
8 Months FUP DSA



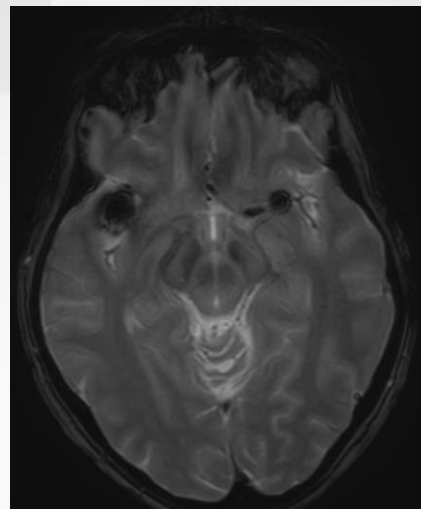
T2



FLAIR

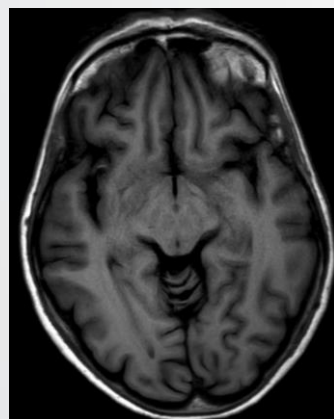


T2W FFE

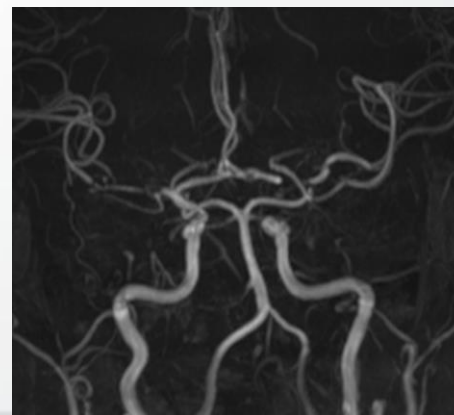


10 Months FUP MRI/MRA

T1



MRA



PATIENT 7

**ME. Fem, 59 y.o.
SMK.**

SAH Fisher IV Hunt Hess II

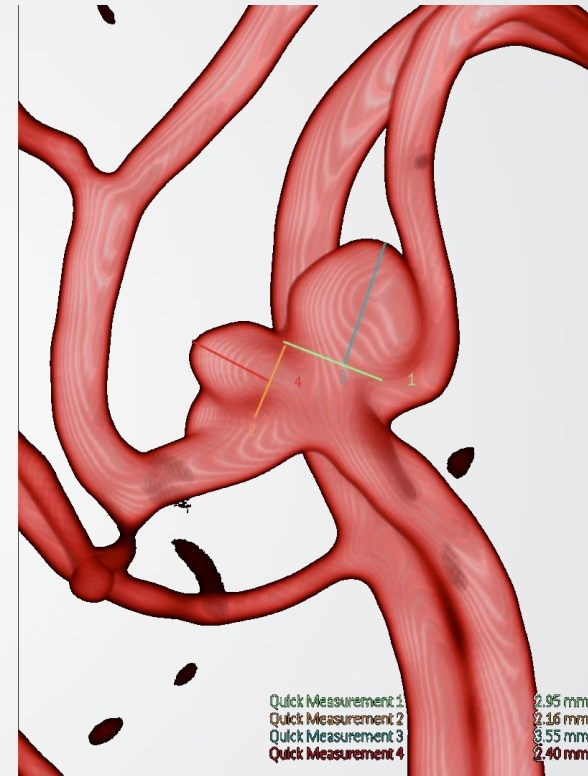
☒ R-PCOM ruptured in 2018 treated with coils.

DSA:

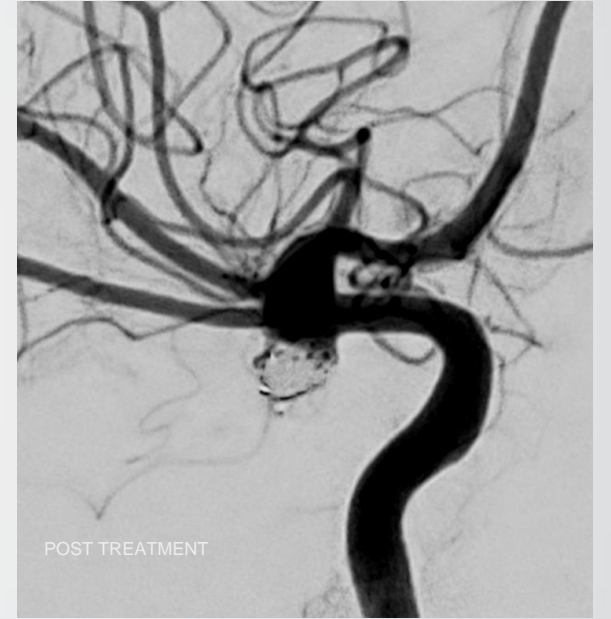
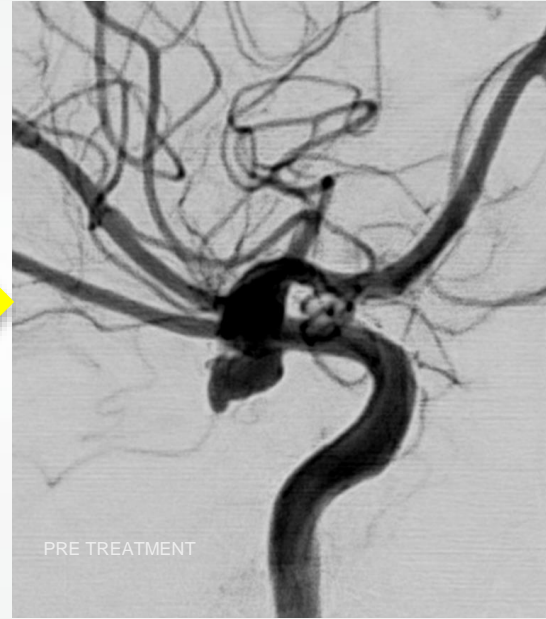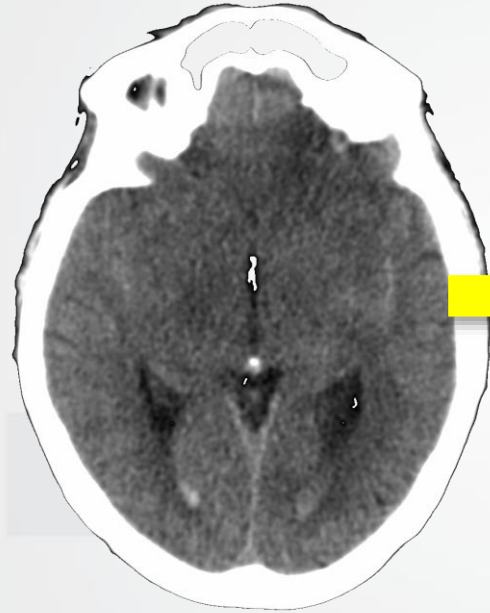
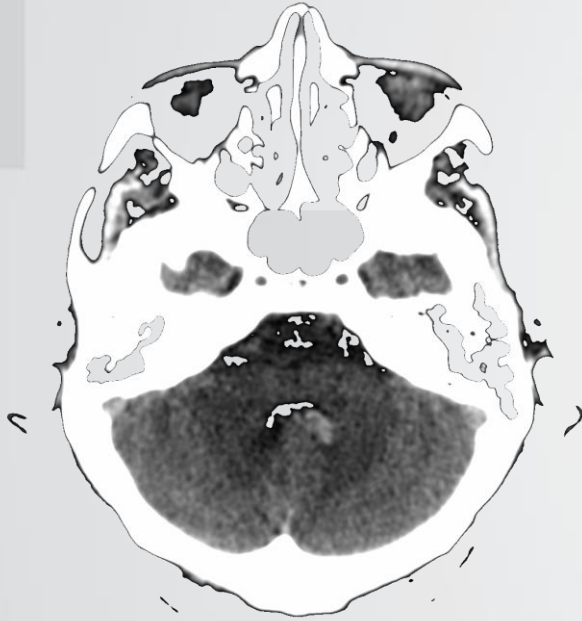
R-PCOM aneurysm with coils occluded

Left Pericallosal bilobulated aneurysm

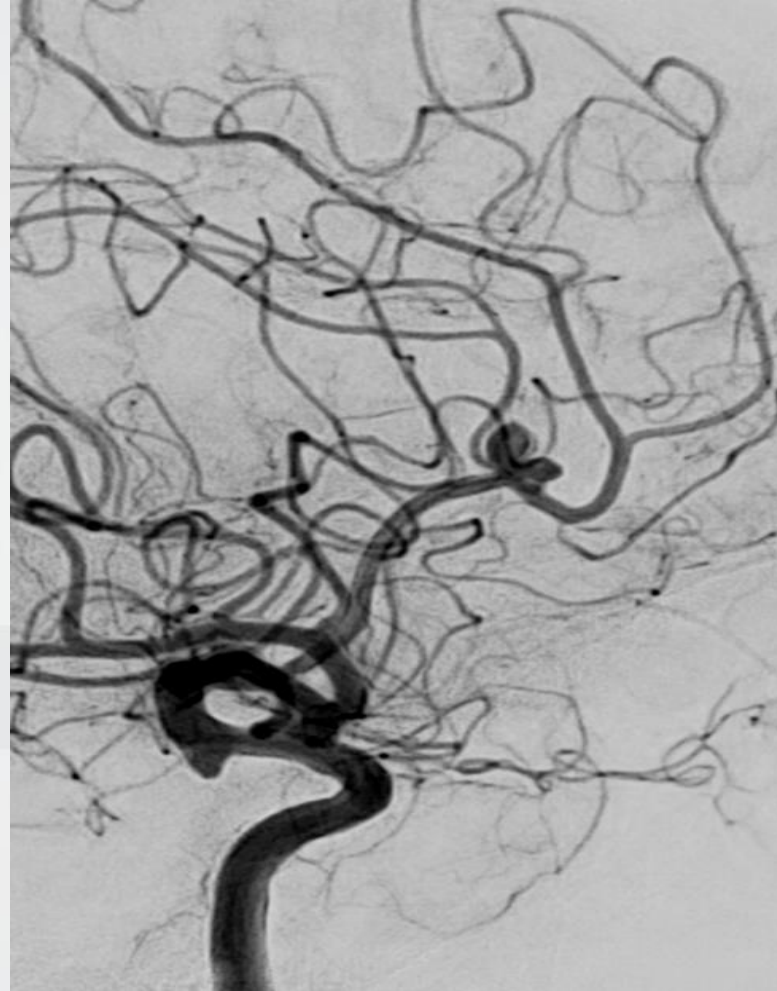
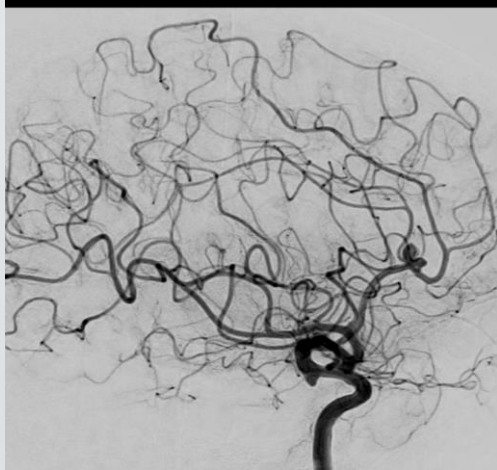
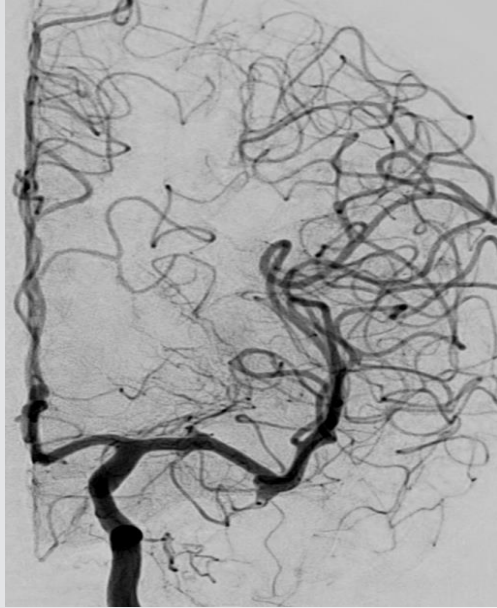
Strategy: Flow diversion



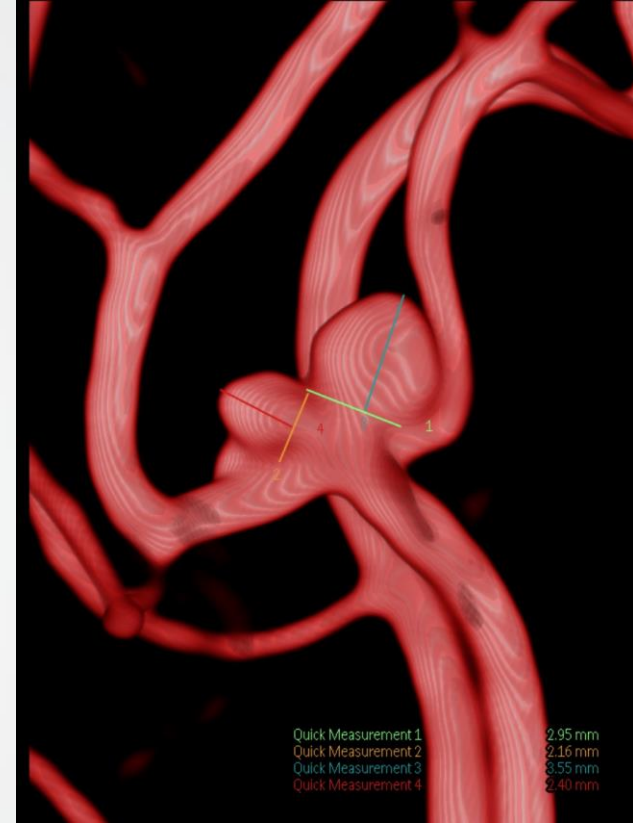
SAH FISHER IV HUNT HESS II



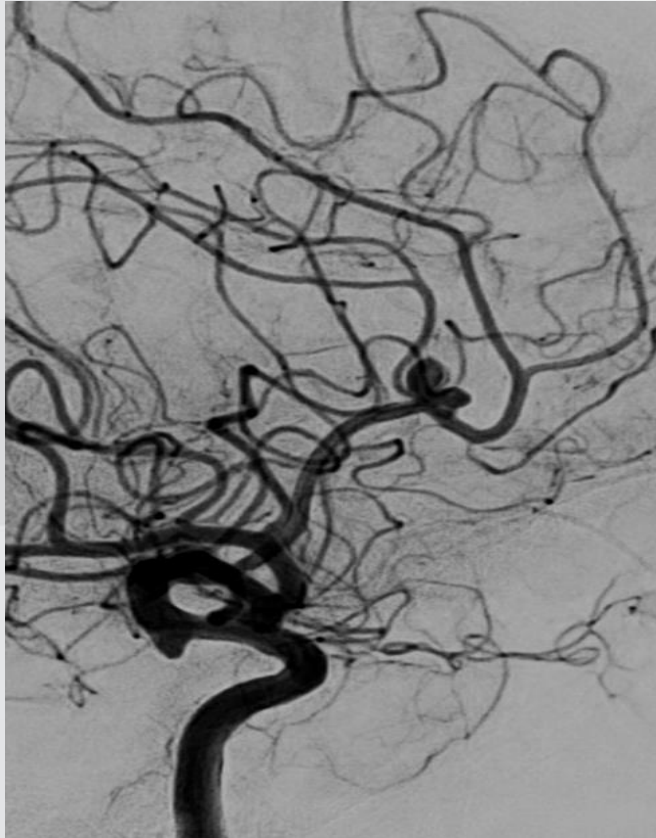
PRE TREATMENT



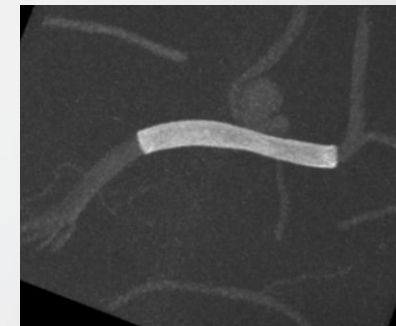
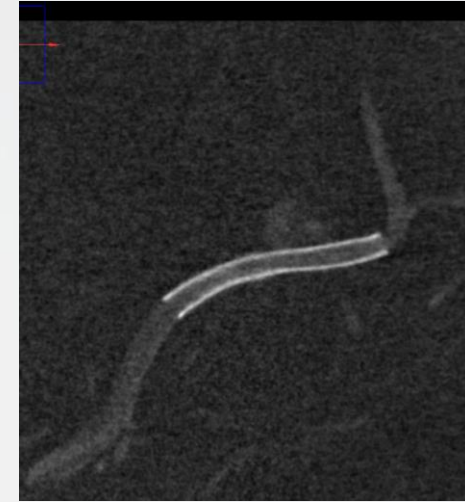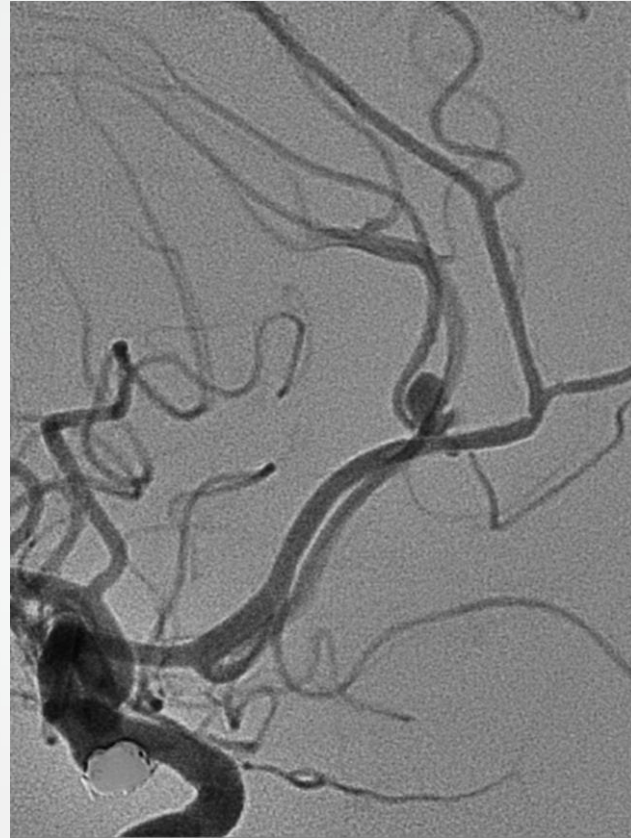PRE TREATMENT



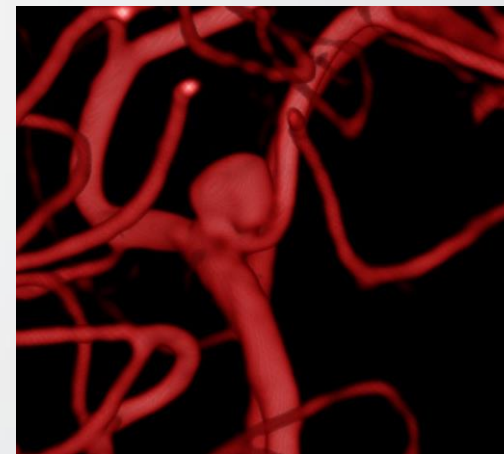
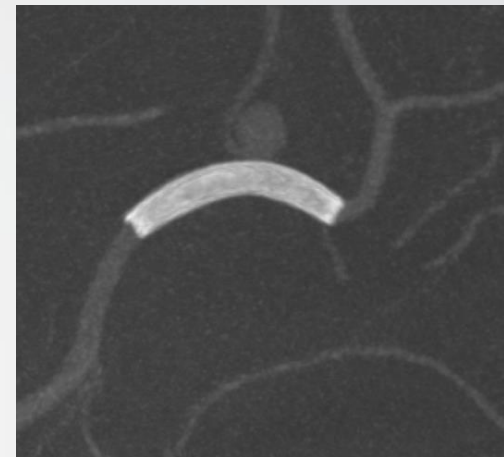
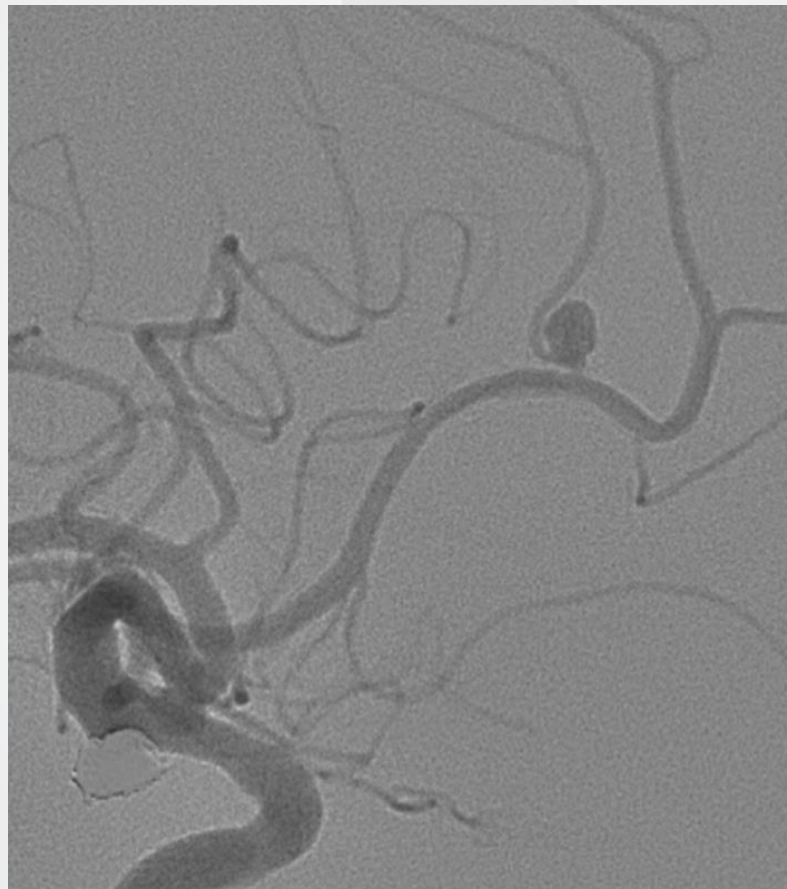
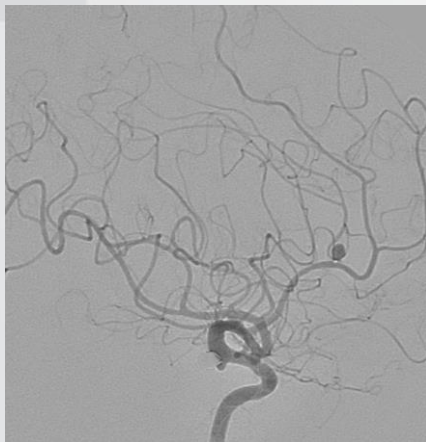
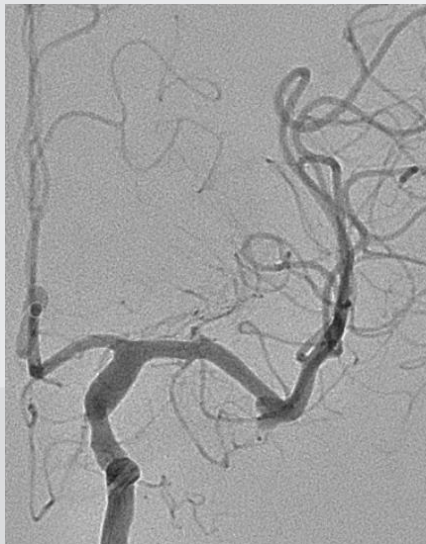
PRE TREATMENT



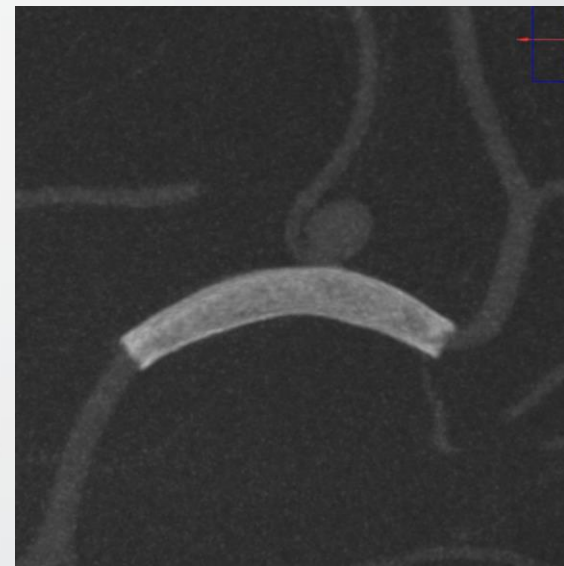
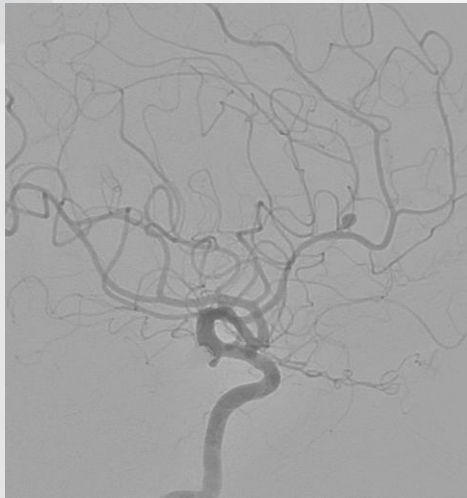
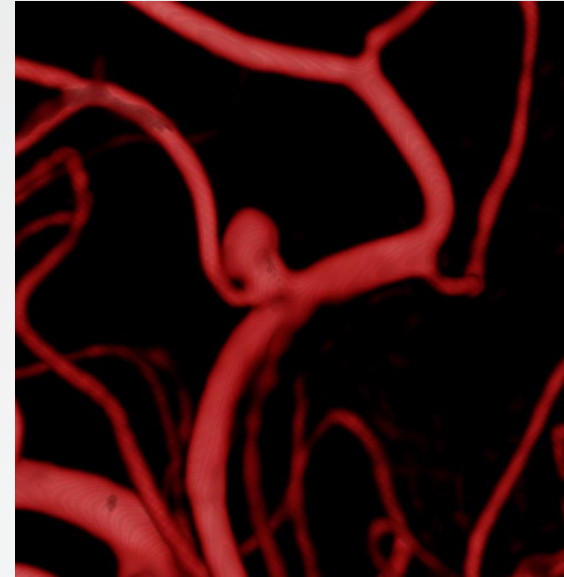
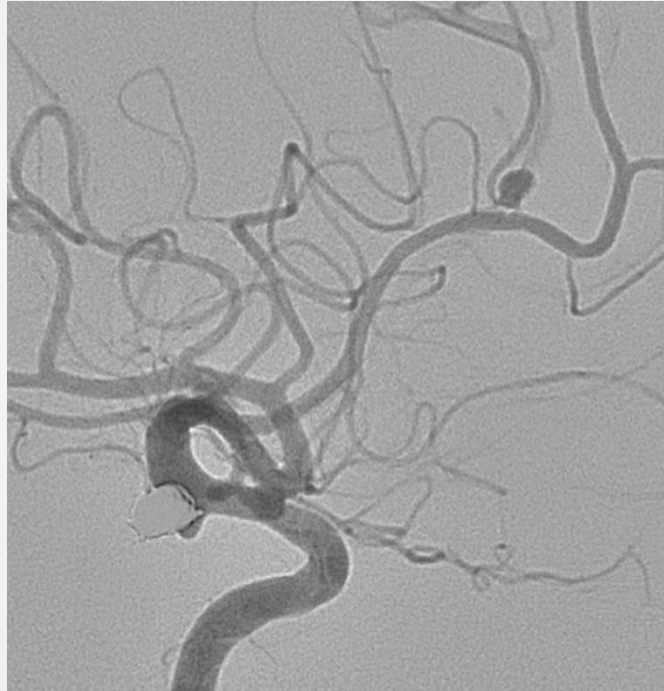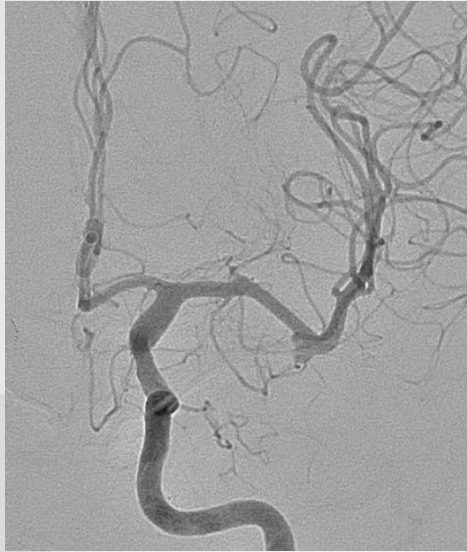POST TREATMENT




6 Months FUP DSA



12 Months FUP DSA





WLNC 2018

KOBE CASES

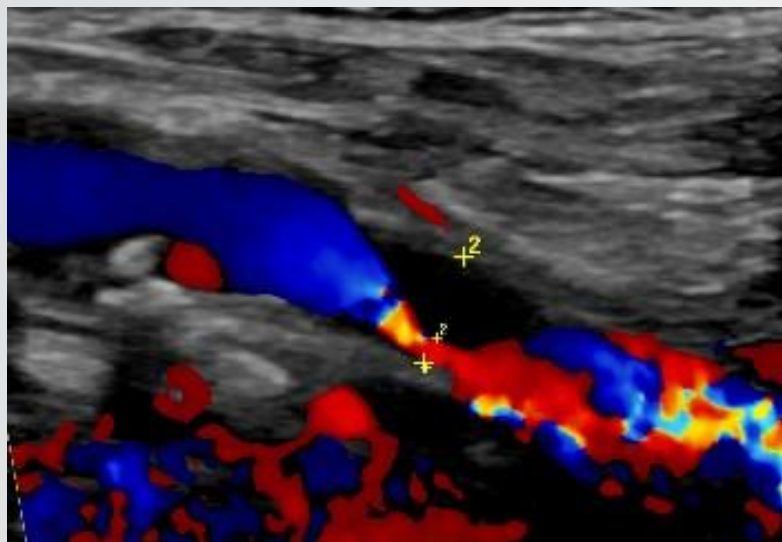


PATIENT 1

60y Female,
L-ICA asymptomatic stenosis

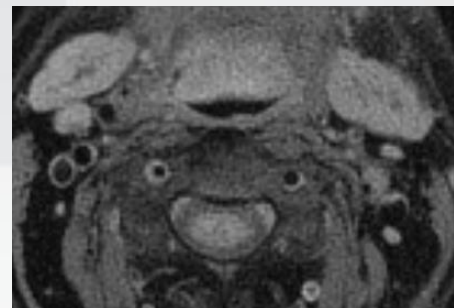
Current history	She presented non-related abnormal behavior, and carotid ultrasound has showed severe left carotid stenosis with moderate calcification.
Past medical history	Crohn's disease
Medication	Aspirin 100mg , Bisoprorol fumarete, Azernidipine, Lansoprazole, Vildagliptin, Doxizosin mesilate Clopidogrel 75mg (7 days prior to admission)
Anesthesia	Local anesthesia with temporary percutaneous pacing
Approach	Trans-femoral approach
Guiding system	Cello 9Fr
Distal protection	Carotid Guardwire
Stent	Precise
Angioplasty	Aviator



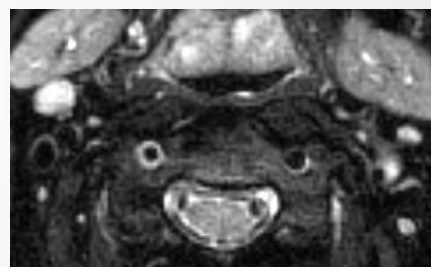

	ECST	PSV	Plaque Characteristic
L	85%	377cm/s	Low echoic, Moderate calcified
R	/	WNL	Iso echoic

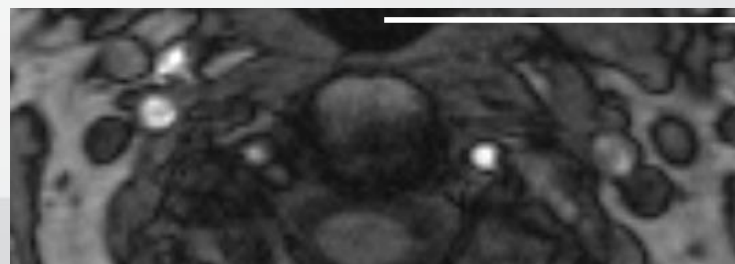
T1

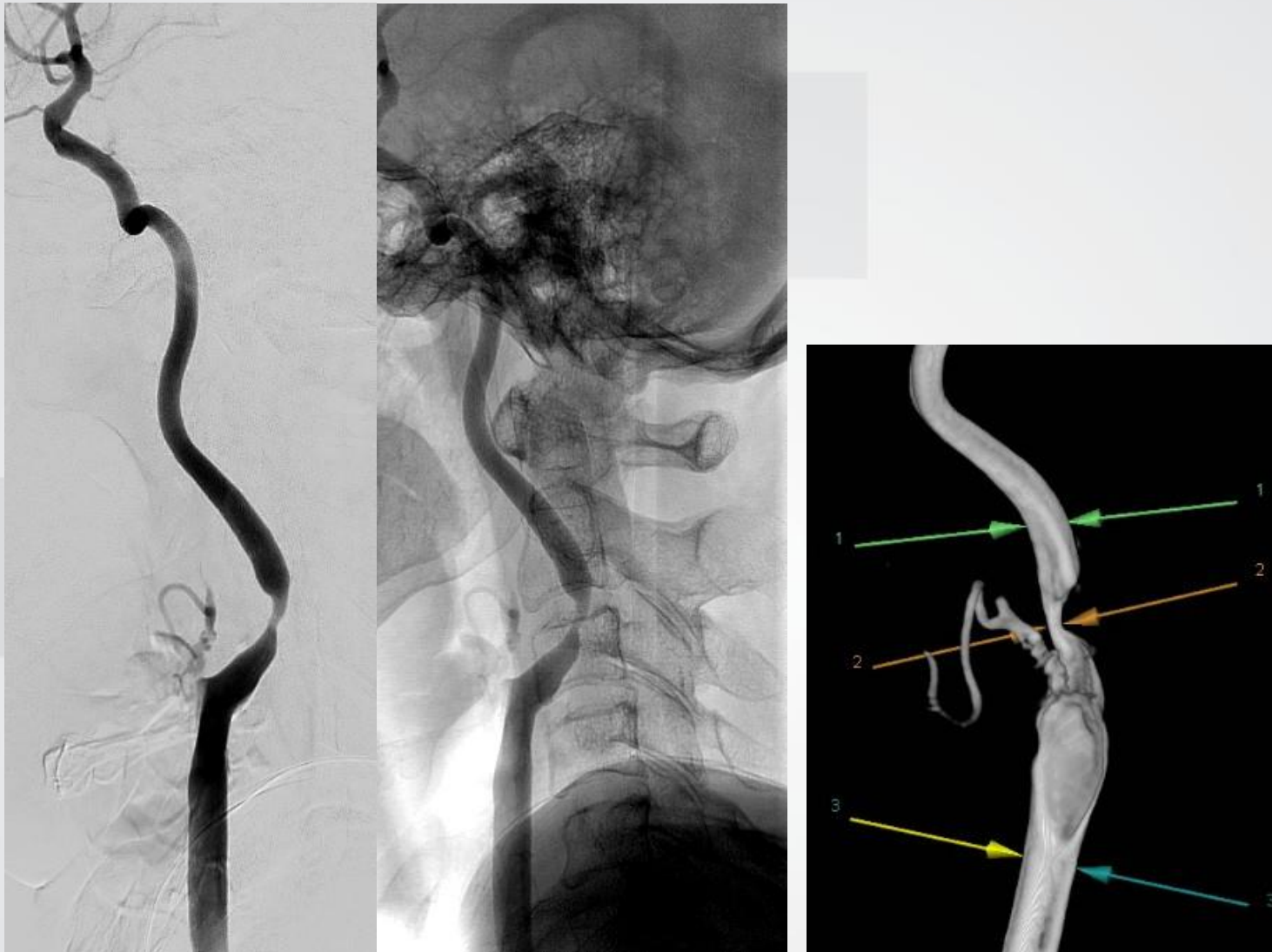

T2



TOF



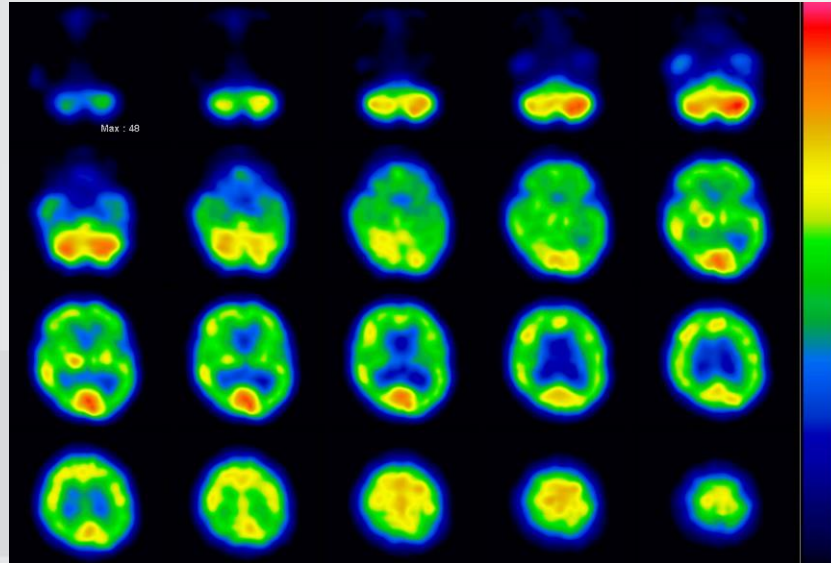


Lt CCA(Lateral)

Length of lesion: 16.2mm

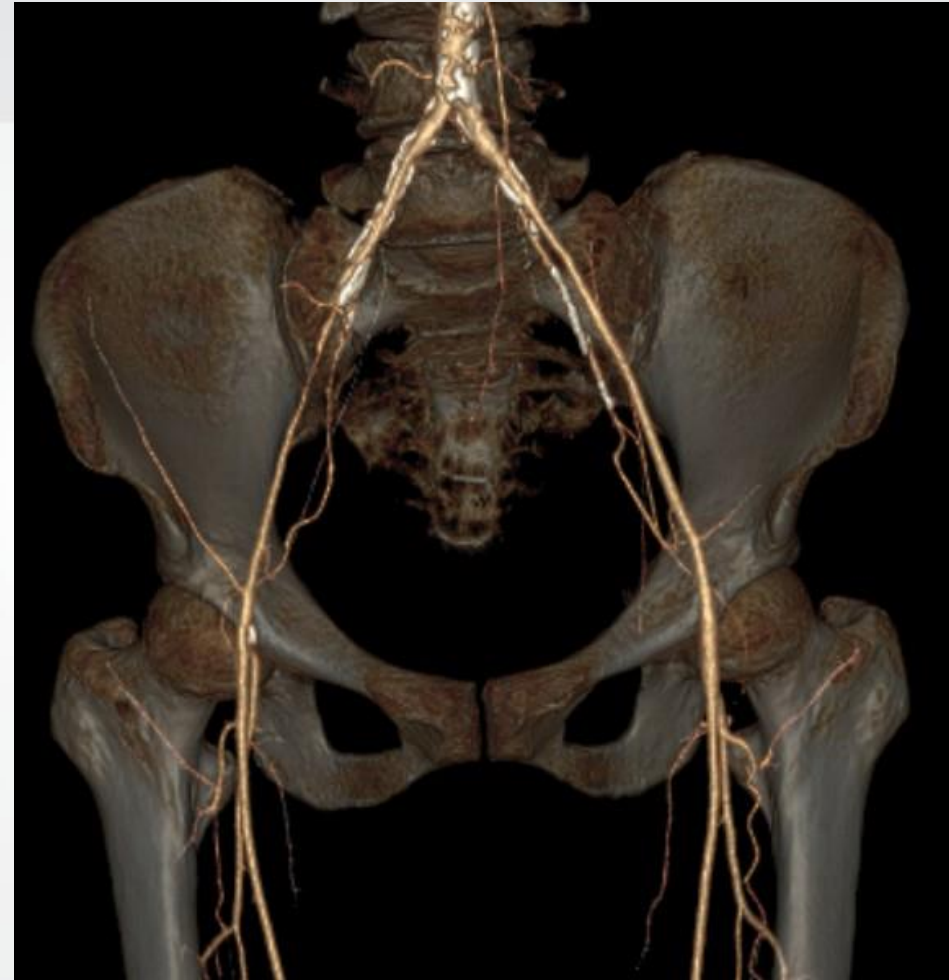
Diameter: Proximal 7.1mm,Distal 5.3mm, Stenosis 1.5mm, NASCET 72%

SPECT (rest)

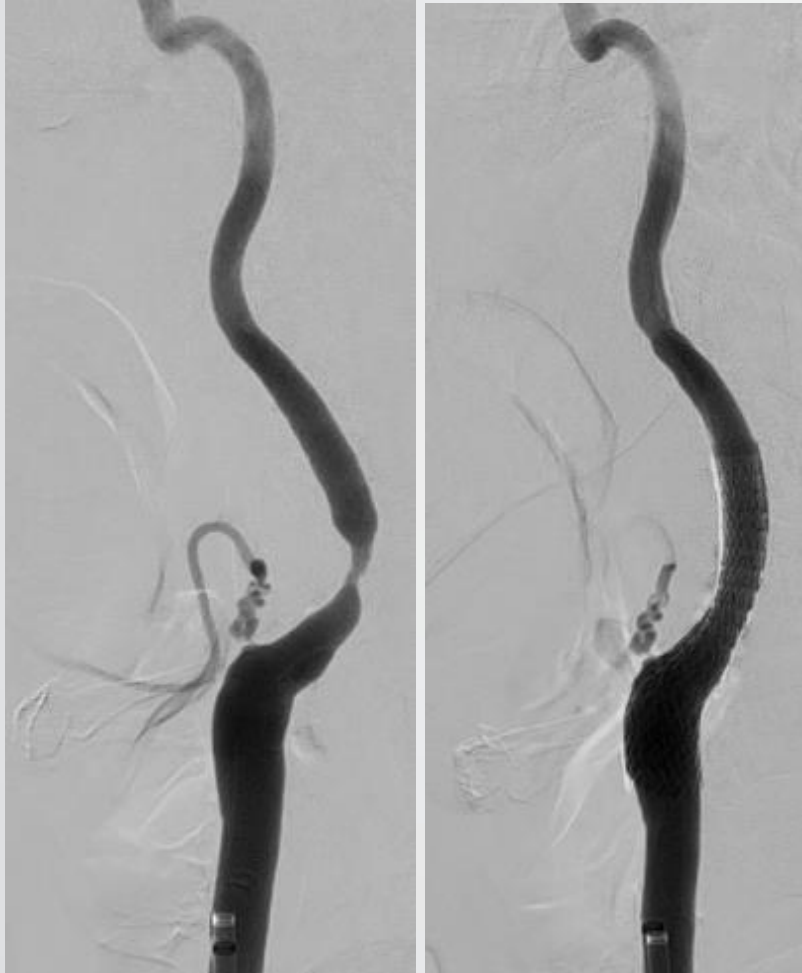

Lt MCA territory CBF ↓ (5%)

CTA



Case 1: 60y Female,
L-ICA CAS

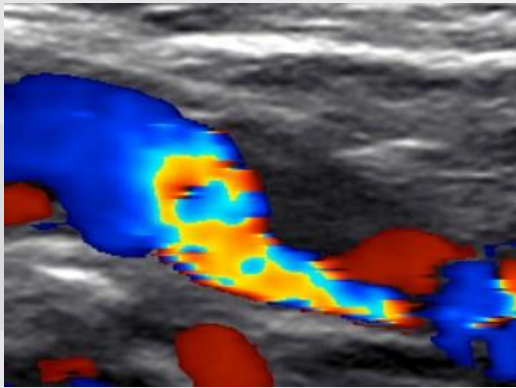


Pre

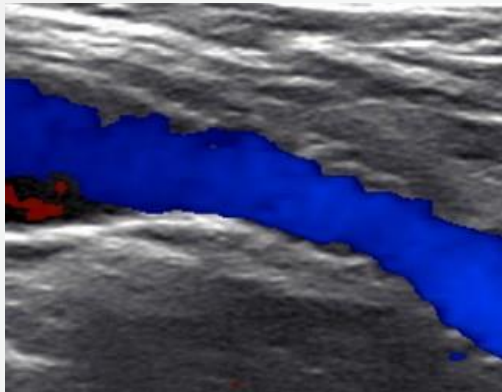
Post

Local anesthesia
TCD, INVOS monitor
MOMA ultra + Carotid Guardwire
Pre-PTA; Coyote 3.5/40mm, 6atm, 30sec
Stent; Precise 10/40mm
Post-PTA; Aviator 4.5/20mm, 10atm, 5sec

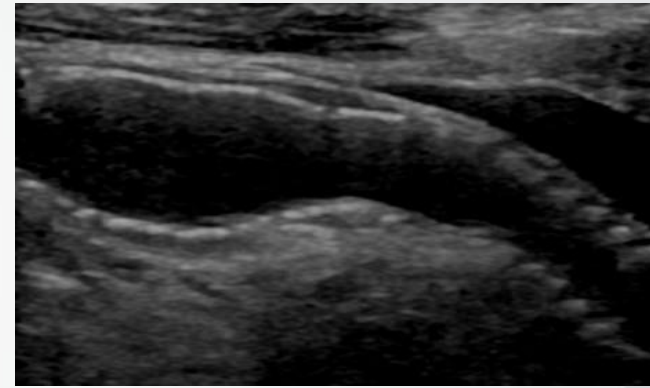
Case 1: 60y Female,
L-ICA CAS



Pre
PSV 377cm/s
mRS=0



POD 3M
PSV
121cm/s
mRS=0



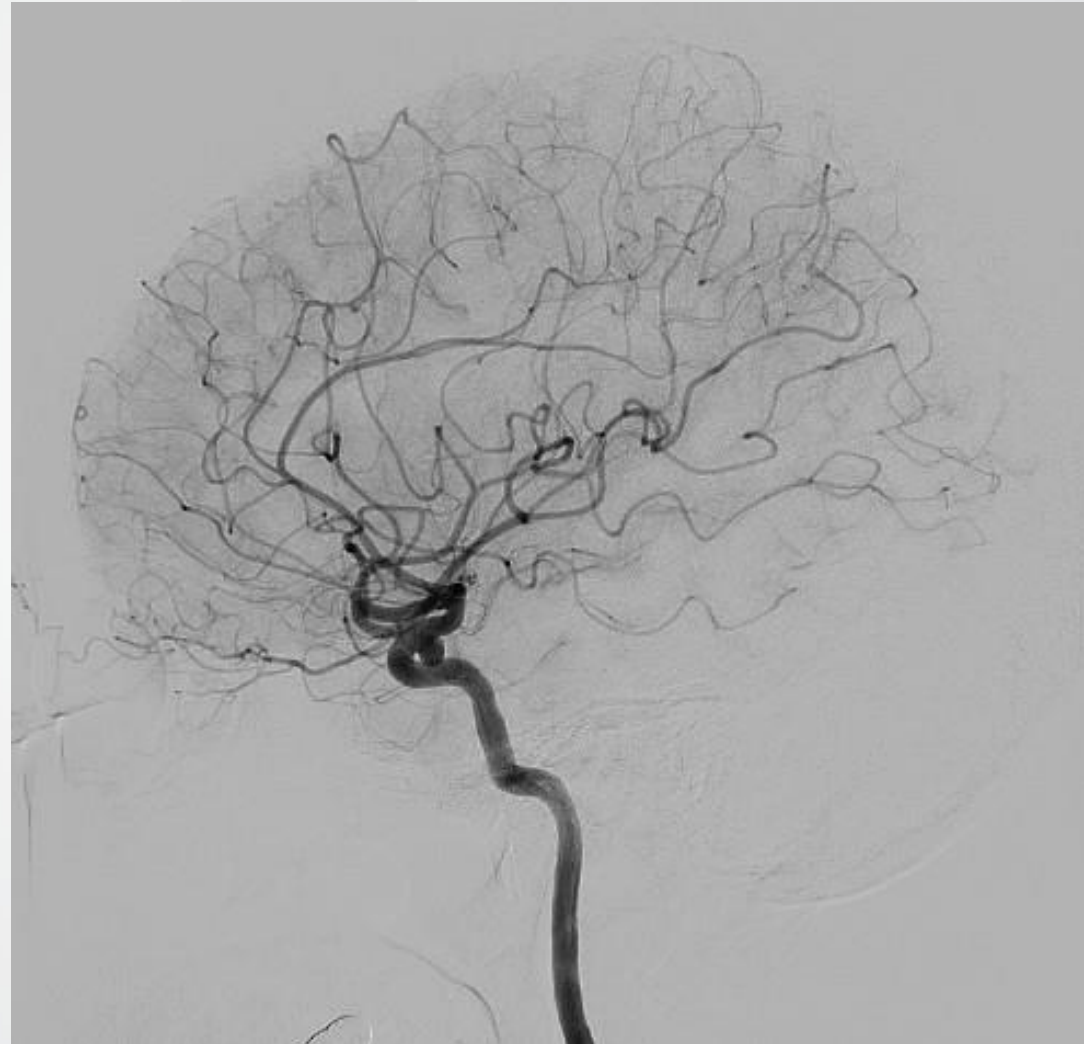
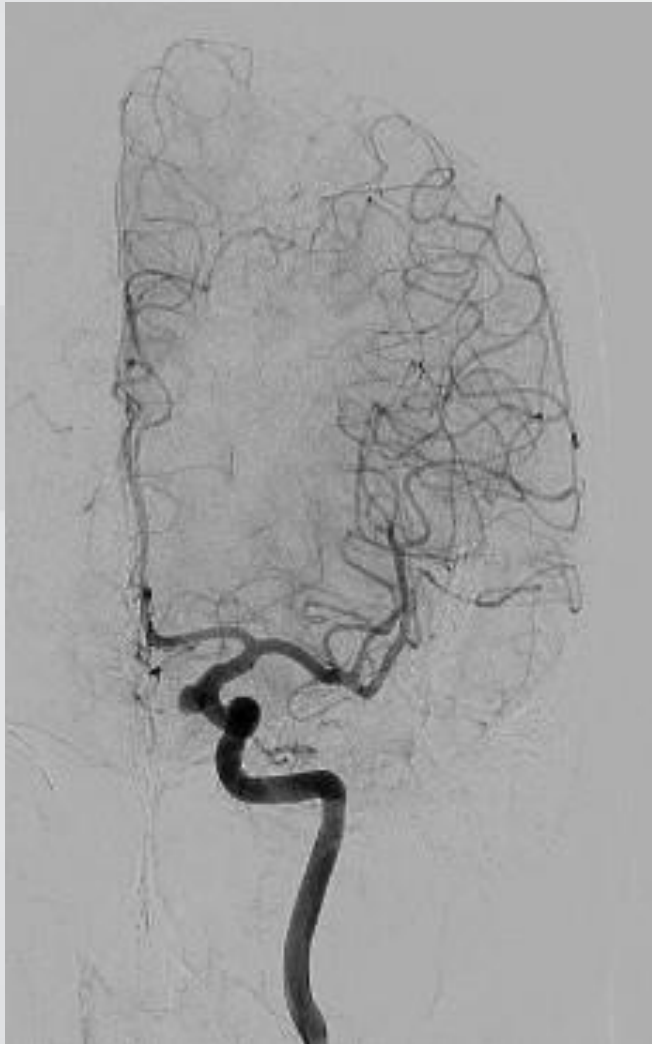POD 9M
PSV 87.1cm/s
restenosis(-)
mRS=0

PATIENT 2

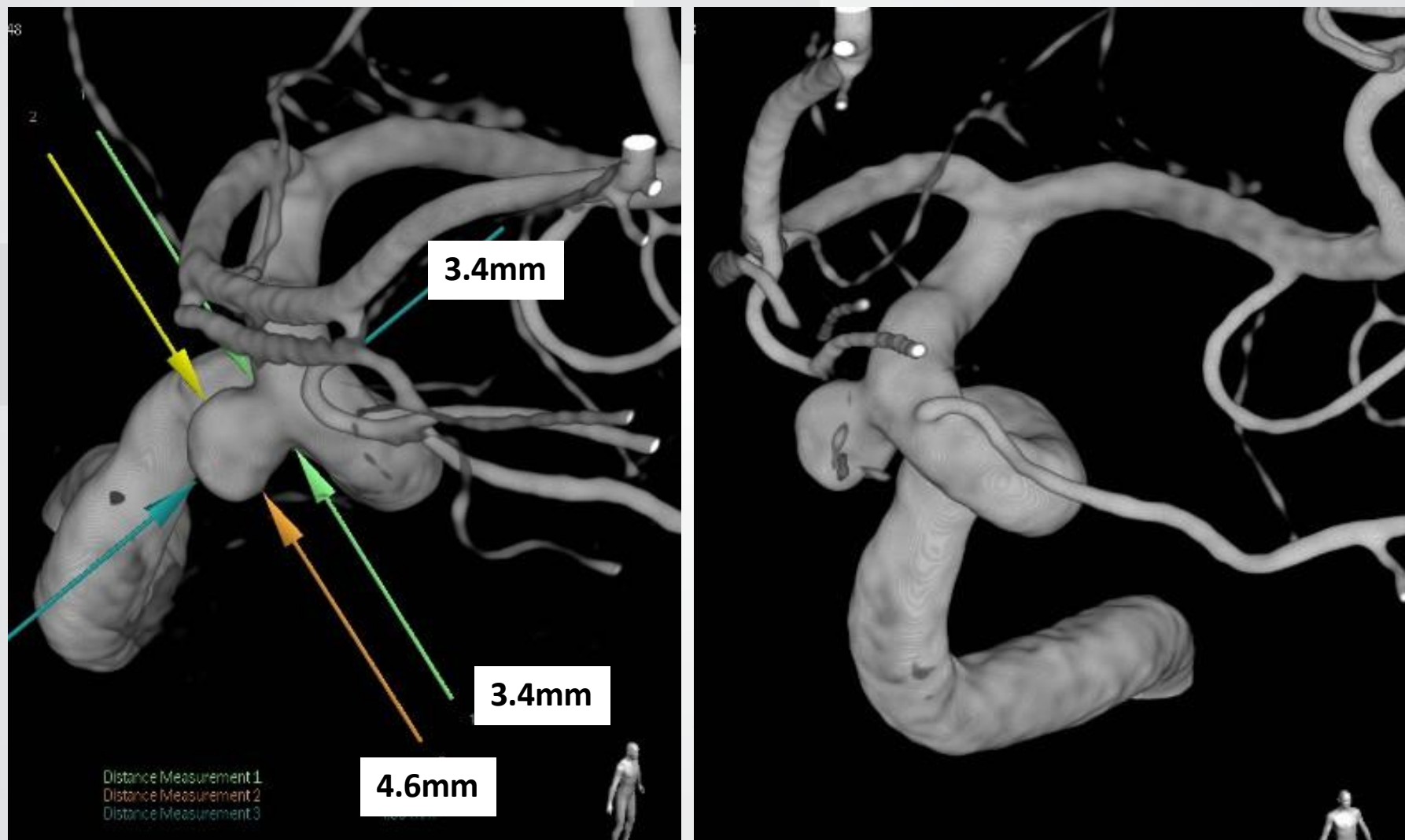
Current history	In 2013, she had no AN on MRA, but a left ICA SHA aneurysm was detected incidentally in 2017.
Past medical history	Bilateral coarthritis
Medication	Aspirin 100mg (#), Clopidogrel 75mg (#) #7 days prior to admission
Anesthesia	Local anesthesia
Approach	Trans-femoral approach
Guiding system	7Fr ENVOY
Stent	Enterprise 2 / LVIS / NF Atlas
Microcatheter	Excelsior SL10, steam shape / Headway 17
Coil	Cosmos/Hydrogel coil/Target/Others



Case 2: 63y Female,
L-ICA SAH unruptured aneurysm

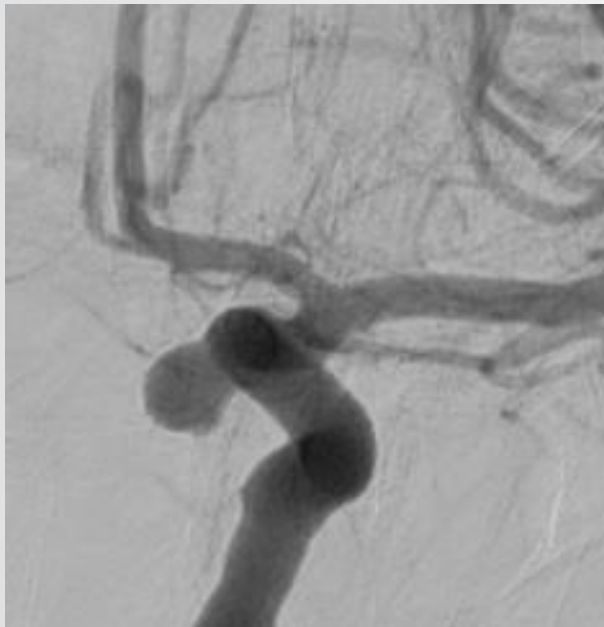


Case 2: 63y Female, L-ICA SAH unruptured aneurysm

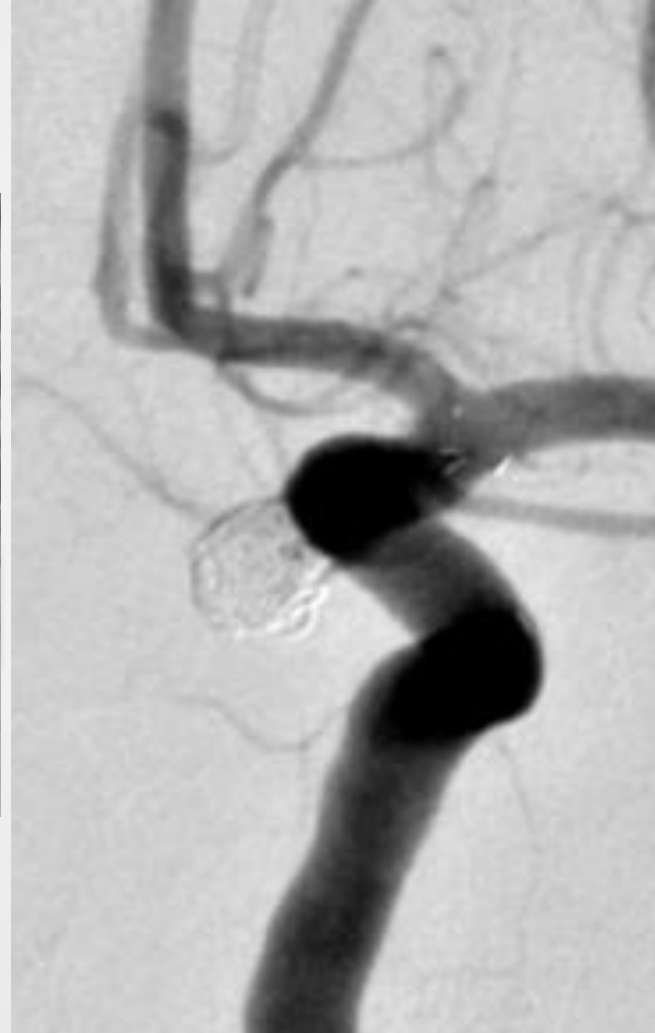


Case 2: 63y Female, L-ICA SAH unruptured aneurysm

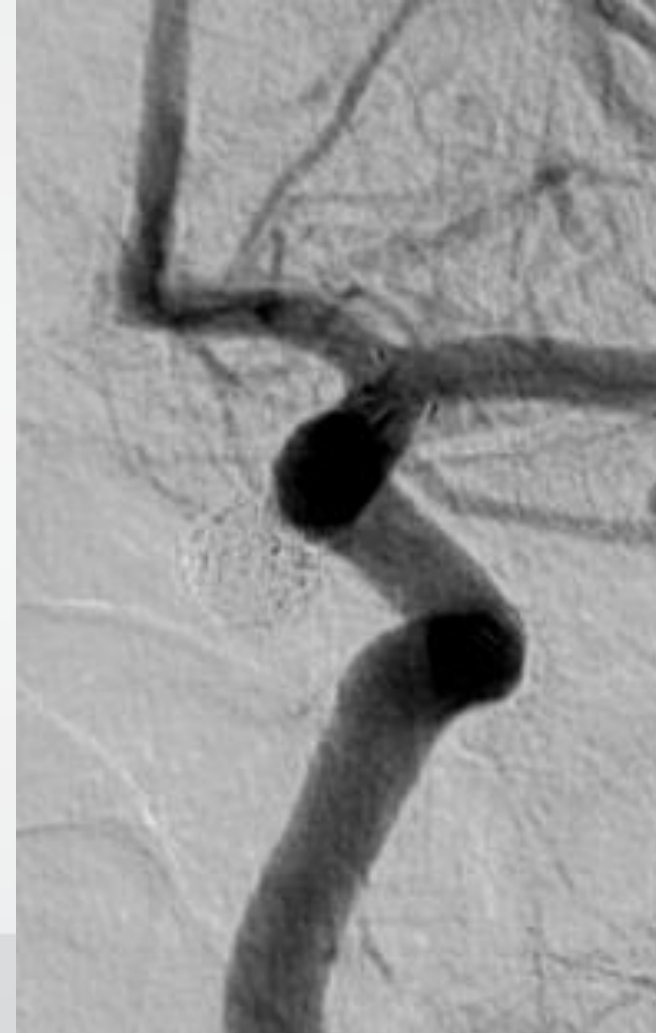
Pre Working angle



Local anesthesia GC;
Envoy 7F
Enterprise2 4/23mm Orbit
Galaxy 4/10,
HydroSoft 3/6 2.5/4, 2.5/4, 2/2



Post
DAPT 3M, ASA 3M



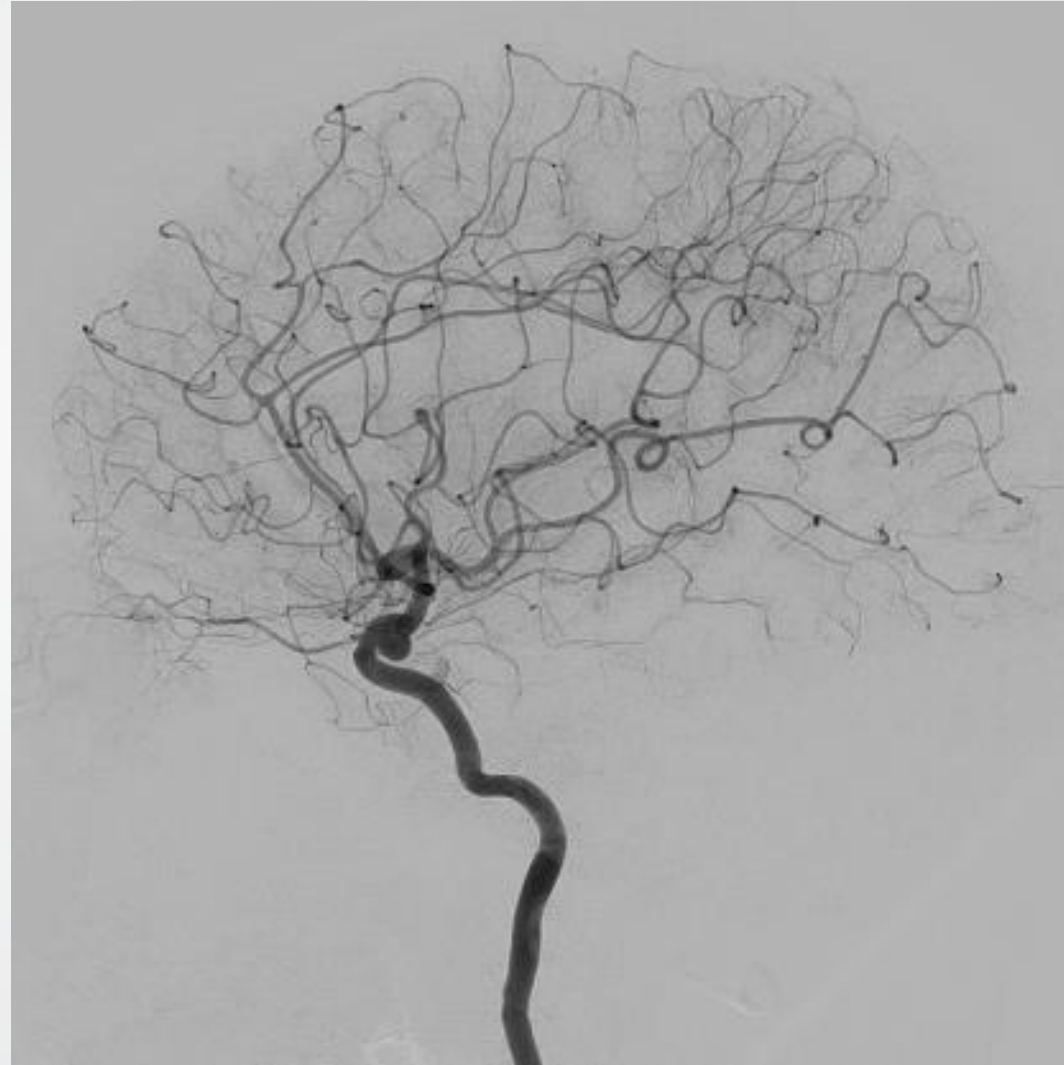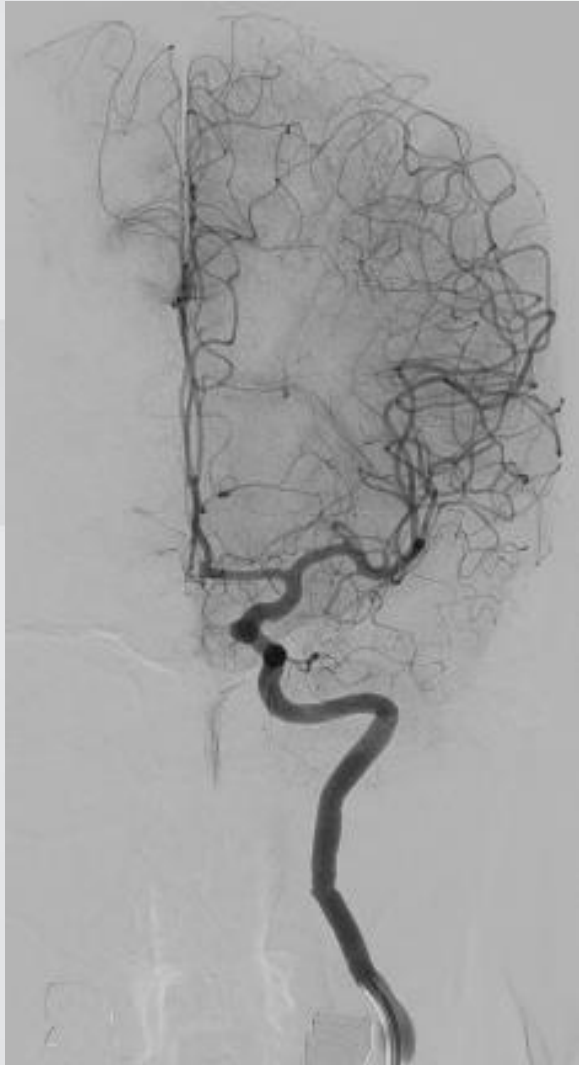POD 6M
mRS=0

PATIENT 3

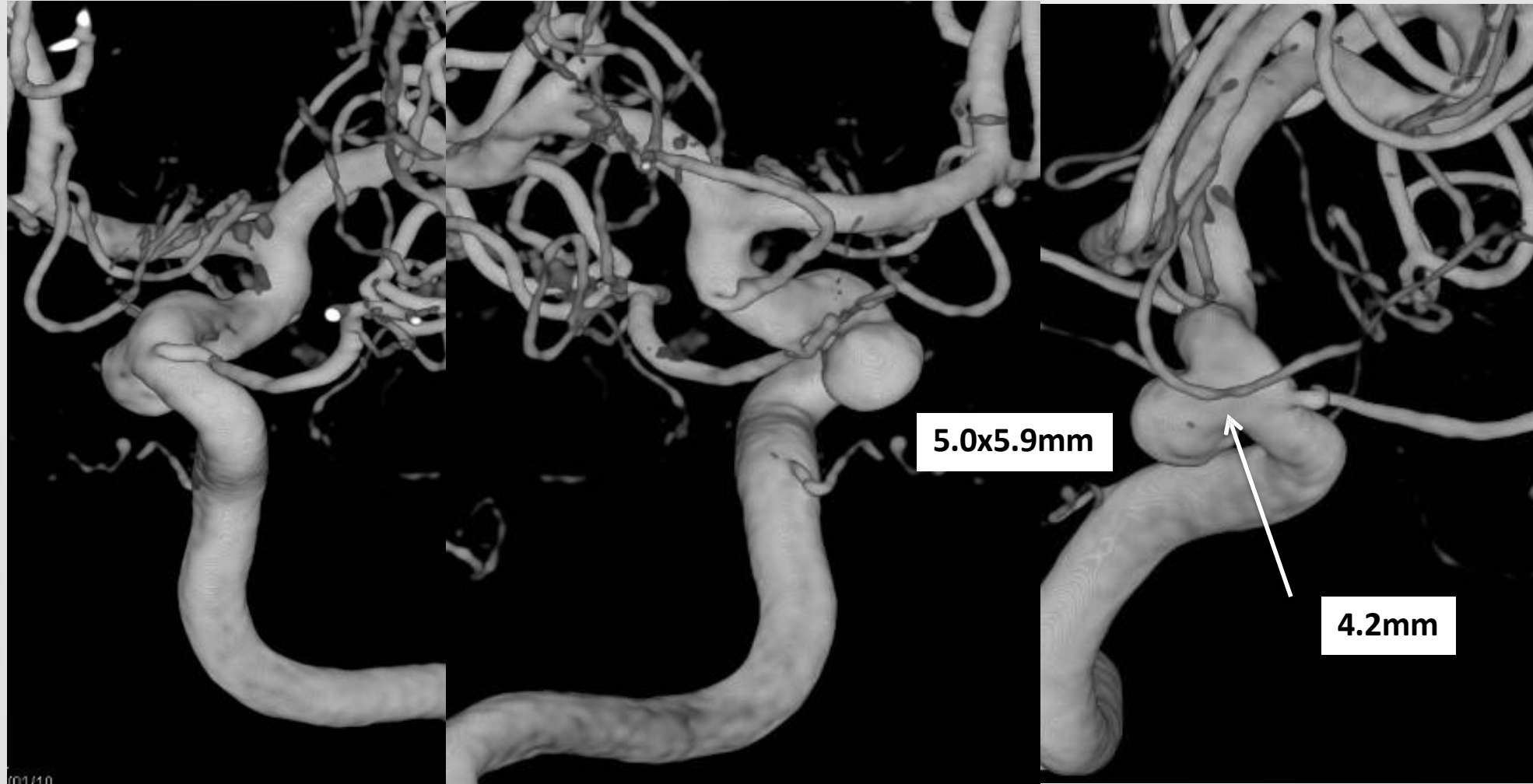
Current history	A left ICA SHA aneurysm was detected incidentally on MRA.
Past medical history	Mycoplasma pneumonia
Medication	Aspirin 100mg (#), Clopidogrel 75mg (#) #10 days prior to admission
Anesthesia	Local anesthesia
Approach	Trans-femoral approach
Guiding system	8Fr/6Fr coaxial catheter system
Stent	Enterprise 2 / LVIS / NF Atlas
Microcatheter	Prowler select plus, Excelsior SL10, steam shape
Coil	Axium/Target/Others



Case 3: 60y Female, L-ICA SAH unruptured aneurysm

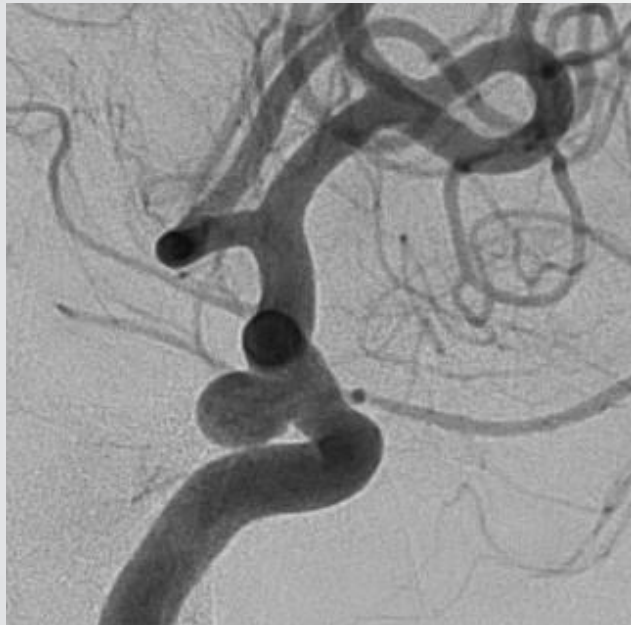


Case 3: 60y Female, L-ICA SAH unruptured aneurysm

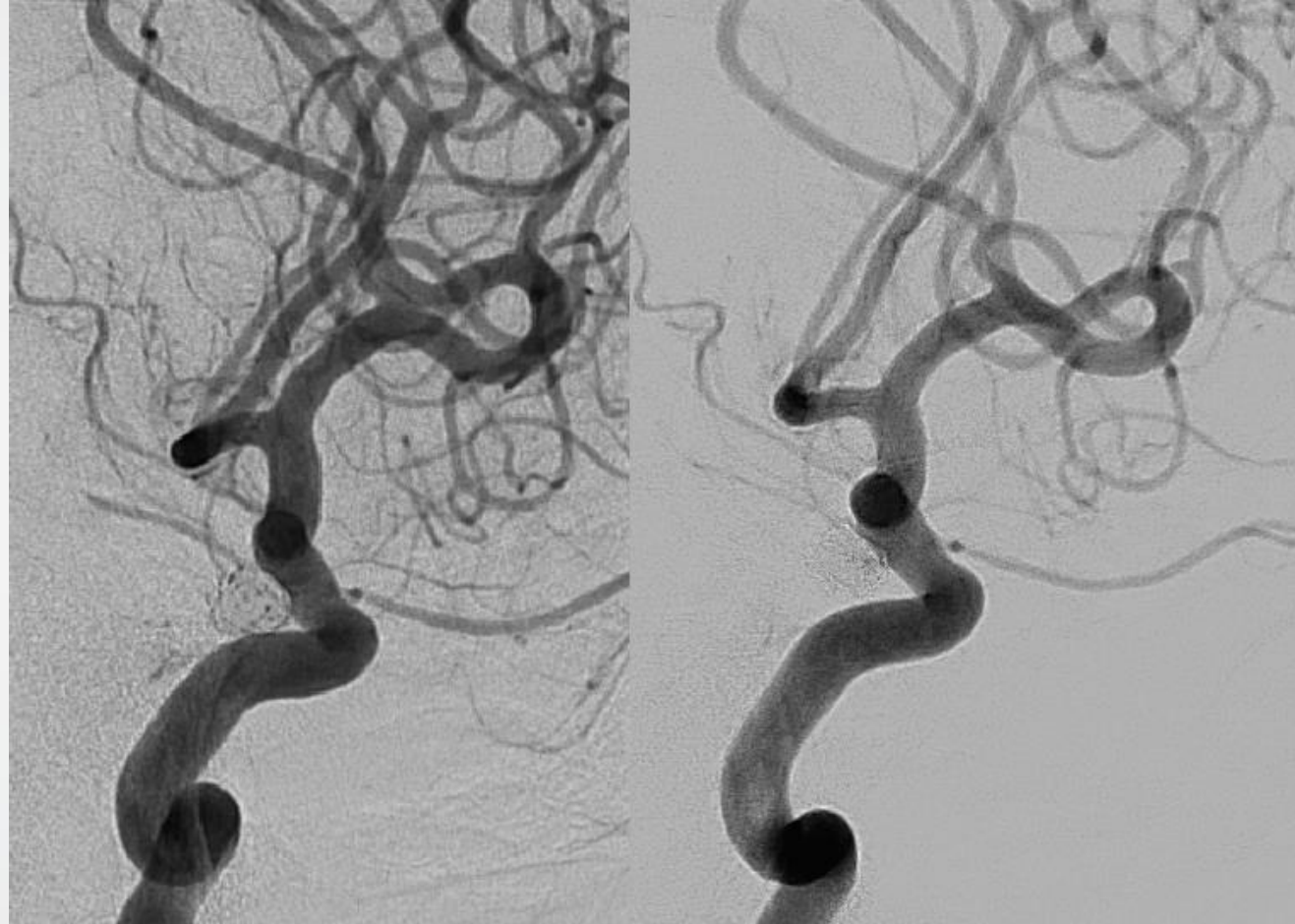


Case 3: 60y Female, L-ICA SAH unruptured aneurysm

Pre Working angle



Local anesthesia GC;
Fubuki 8F Scepter C
4/10mm
Axium Prime Frame 5/10
Axium Prime 4/8, 3.5/6, 3/4,
2.5/4, 2/3, 2/2



Post
DAPT 3M, ASA 3M

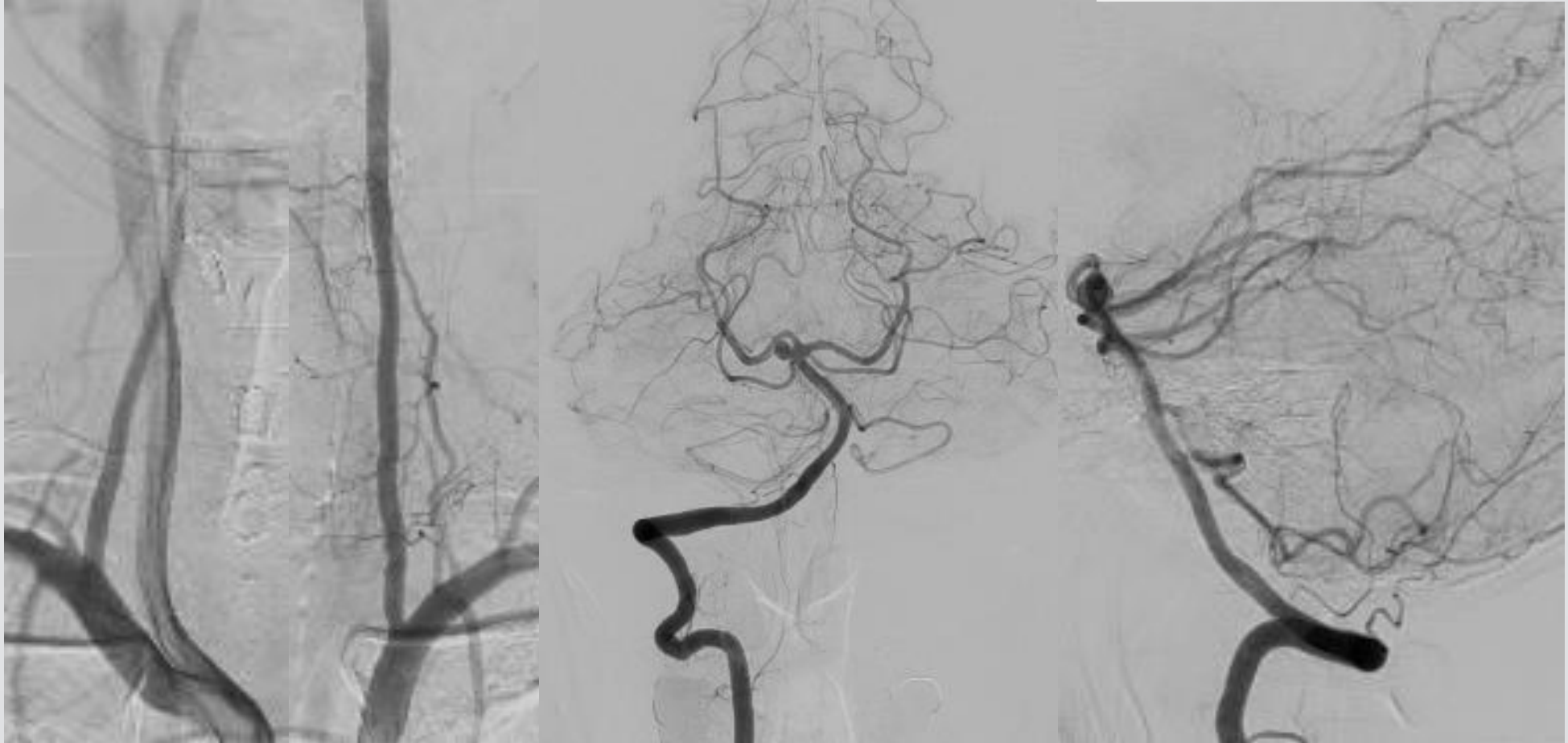
POD 6M
mRS=0

PATIENT 4

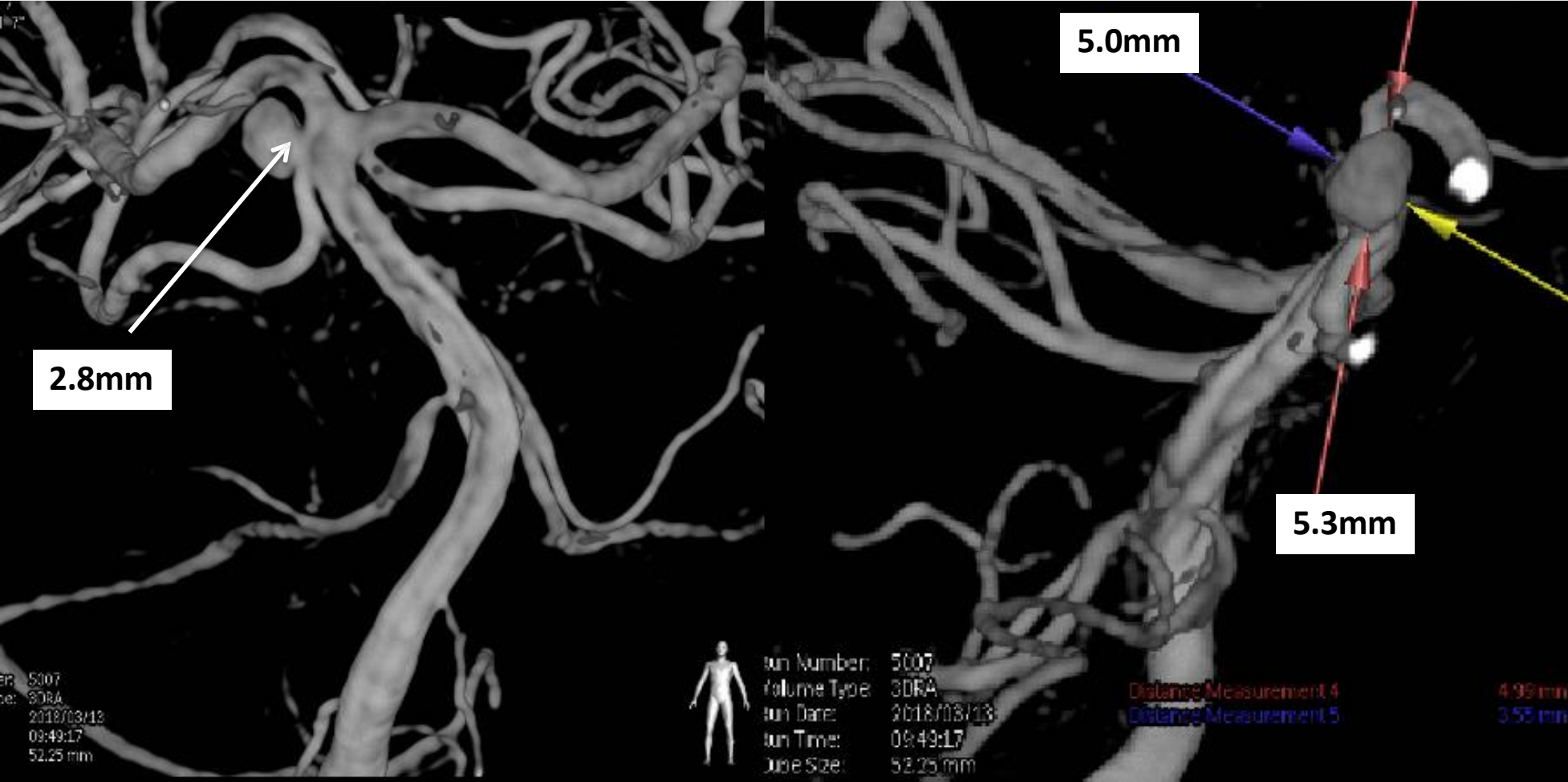
Current history	A right BA.SCA aneurysm was detected for examination of dizziness on MRA.
Past medical history	Hypertension and dyslipidemia
Medication	Aspirin 100mg (#), Clopidogrel 75mg (#) #10 days prior to admission Amlodipine, Atorubastatin
Anesthesia	Local anesthesia
Approach	Trans-femoral approach
Guiding system	7Fr Envoy
Stent	No plan
Balloon	Scepter on the table
Microcatheter	Excelsior SL10, steam shape
Coil	Target/ Galaxy/ Others



Case 4: 63y Female,
R-BA.SCA unruptured aneurysm

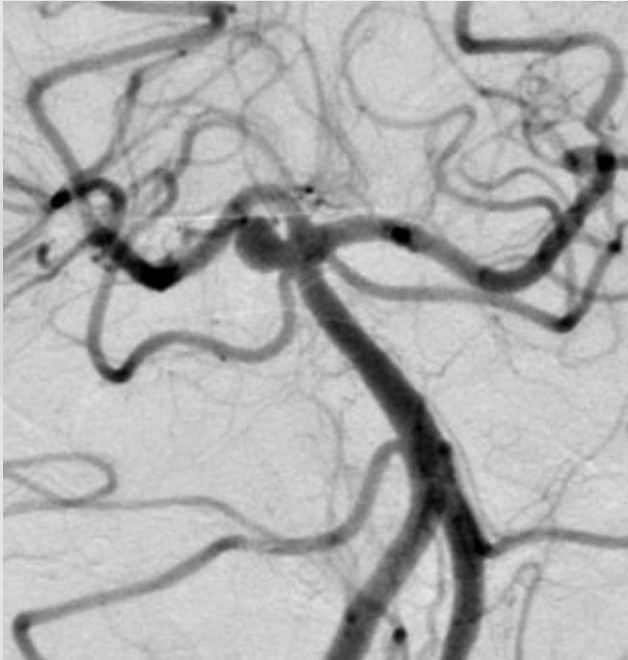


Case 4: 63y Female, R-BA.SCA unruptured aneurysm



Case 4: 63y Female, R-BA.SCA unruptured aneurysm

Pre Working angle



Local anesthesia

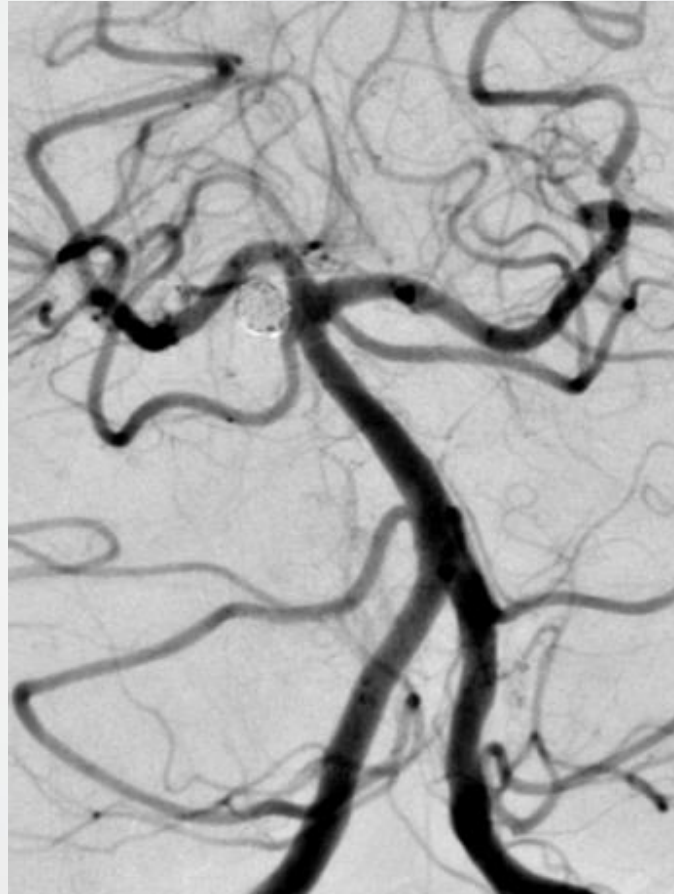
GC; Envoy 7F

Excelsior SL10 S shape

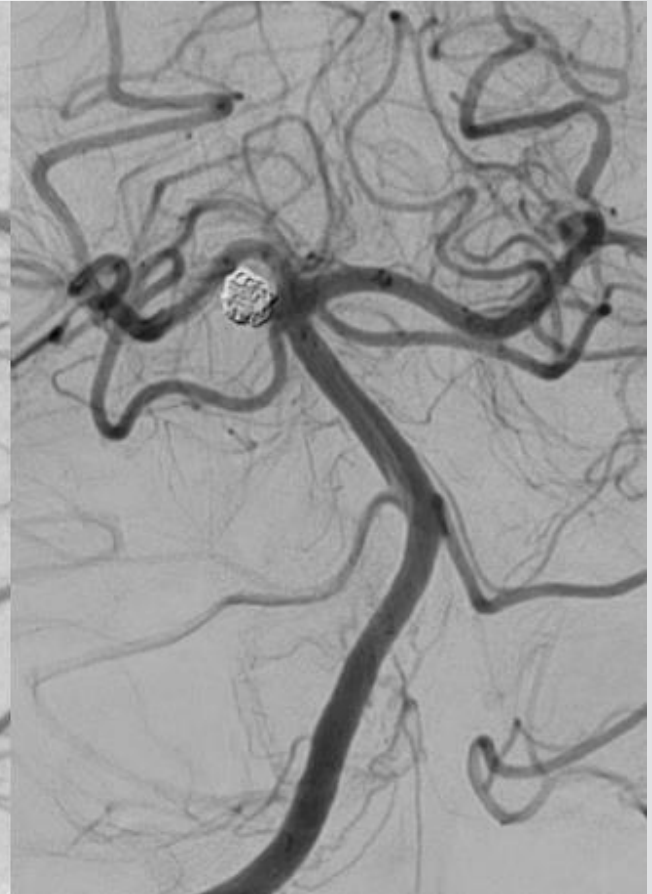double catheter Target360

soft 3/8

Target nano 2.5/4, 2/4, 2/4, 2/3



Post
DAPT 3M, ASA 3M



POD 6M
mRS=0



WORLD LIVE NEUROVASCULAR CONFERENCE

06 - 08 May 2020 • Washington, DC - USA

www.wlnc.org

**MARK
YOUR
CALENDAR!**



WLNC ORGANIZING COMMITTEE

Dr. Saruhan CEKIRGE
Dr. Jian Min LIU

Dr. Ricardo A. HANEL
Dr. Demetrius LOPES

Dr. Civan ISLAK
Dr. Pedro LYLYK

Dr. Osman KIZILKILIC
Dr. Isil SAATCI

Dr. Naci KOCER
Dr. Adnan SIDDIQUI

ENDORSED BY



ORGANIZING SECRETARIAT



www.dekongroup.com

info@wlnc.org

Educational Grant will be provided by CREF for WLNC 2020

CREF
CEREBROVASCULAR RESEARCH AND EDUCATION FOUNDATION
www.cref.info